

Ocular manifestations and SARS-CoV-2 detection in tears and conjunctival scrape from non-severe COVID-19 patients

Bing Jiang^{1,2}, Shao-Jie Li³, Wen-Long Wang⁴, Min Hu⁵, Sui He³, Jian Cao^{1,2}, Li Jiang^{1,2,6}, Yun Li^{1,2}

¹Department of Ophthalmology, the 2nd Xiangya Hospital of Central South University, Changsha 410011, Hunan Province, China

²Hunan Clinical Research Center of Ophthalmic Disease, Changsha 410011, Hunan Province, China

³Xiangtan Central Hospital, Xiangtan 411100, Hunan Province, China

⁴Department of Infectious Diseases, the 2nd Xiangya Hospital of Central South University, Changsha 410011, Hunan Province, China

⁵Department of Laboratory Medicine, the 2nd Xiangya Hospital of Central South University, Changsha 410011, Hunan Province, China

⁶Department of Nursery, Fangcang Hospital of Wuchang, Wuhan, Hubei Province, China

Co-first authors: Bin Jiang and Shao-Jie Li

Correspondence to: Yun Li. Department of Ophthalmology, the 2nd Xiangya Hospital of Central South University, Changsha 410011, Hunan Province, China. yun.li@csu.edu.cn

Received: 2020-06-17 Accepted: 2021-01-20

Abstract

• **AIM:** To explore the ocular features of corona virus disease (COVID)-19 and severe acute respiratory syndrome coronavirus (SARS-CoV)-2 detection in tears and conjunctival scrapes in non-severe COVID-19 patients.

• **METHODS:** This is a multicenter observational clinical study with no intervention conducted from Jan 25th to March 1st, 2020. Clinical data and samples of tears and conjunctival scraping were collected in consecutive laboratory-confirmed, non-severe COVID-19 patients from three hospitals. COVID-19 virus was analyzed by real-time reverse transcriptase polymerase chain reaction (RT-PCR) kits.

• **RESULTS:** Totally 255 laboratory-confirmed, non-severe COVID-19 patients were recruited for ocular manifestation investigation. Of them, 54.9% were females, with a mean age of 49.4y. None of the patients has evidence of uveitis; 11 patients (4.3%) complained of mild asthenopia; 2 (0.8%) had mild conjunctival congestion and serous secretion. Twenty-five of them had performed tears and conjunctival scrape for COVID-19 virus detection, with 4 yield possible

positive results in the nucleoprotein gene. One of them were asymptomatic with normal chest CT and positive pharyngeal swab result.

• **CONCLUSION:** Ocular manifestations are neither common nor specific in non-severe COVID-19 patients. Meanwhile, COVID-19 virus nucleotides can be detected in the tears and conjunctival scrape samples, warranting further research on the transmissibility by the ocular route.

• **KEYWORDS:** SARS-CoV-2; COVID-19; tears and conjunctival scrape; transmissibility

DOI:10.18240/ijo.2021.08.01

Citation: Jiang B, Li SJ, Wang WL, Hu M, He S, Cao J, Jiang L, Li Y. Ocular manifestations and SARS-CoV-2 detection in tears and conjunctival scrape from non-severe COVID-19 patients. *Int J Ophthalmol* 2021;14(8):1133-1137

INTRODUCTION

In less than two months, the current corona virus disease (COVID)-19 outbreak in Wuhan, China has skyrocketed to 82 213 infected and 3301 death in China. Globally 509 164 confirmed cases and 23 335 deaths of 199 countries were reported by Mar. 27th[1]. Due to the rapid spread, the World Health Organization has declared it a public health emergency of international concern (PHEIC), and its current status as pandemic[2].

The pathogen of COVID-19, 2019 novel coronavirus (2019-nCoV, or SARS-CoV-2), is the seventh member of enveloped RNA coronavirus, and the third to cause potentially fatal human to human transmission, the previous two being the severe acute respiratory syndrome coronavirus (SARS-CoV) outbreak in 2002 and the Middle East respiratory syndrome coronavirus (MERS-CoV) outbreak in 2012. COVID-19 virus showed 79% homology to SARS-CoV[3], and its clinical manifestations also mimic SARS, with slightly less mortality and even higher transmissibility, partly because of our insufficient knowledge of its transmission routes.

The main transmission route of COVID-19 is believed to be respiratory droplets and direct contact, though evidence of other possible routes is accumulating. Existing cases and experience from SARS also indicate the possibility

of transmission *via* ocular surface is not impossible^[4]. We investigated the possible ocular manifestations and virus detection in tears and conjunctival scrape in non-severe COVID-19 patients, for this patient cohort is more likely to be active and serve as infection sources in the community.

SUBJECTS AND METHODS

Ethical Approval Approval was obtained from the Institutional Review Board of the Second Xiangya Hospital, Central South University. Oral informed consent was obtained from the recruited subjects.

Consecutive COVID-19 patients were recruited from the three hospitals from Jan. 25 to Mar.1 2020, with the following criteria in the Interim Diagnostic and Treatment Protocol for COVID-19 of the People’s Republic of China (6th edition)^[5]: 1) Positive epidemiology history within 14d before onset, plus two of the three major clinical manifestations: fever and/or respiratory symptoms, lymphopenia and/or leukopenia on blood routine, and typical radiology findings of pneumonia on chest CT; 2) COVID-19 infection confirmed by two or more positive results in reverse transcriptase polymerase chain reaction (RT-PCR) assays from two different detection kits in pharyngeal swab specimens if the two kits yield different results, either detection from a third kit or resampling is employed; 3) None to mild systemic clinical manifestations; 4) No respiratory distress syndrome (RDS), No need for ventilation or incubation. The static arterial oxygen partial pressure (PaO₂) >95%.

The tear swab was taken by putting a sterile swab (the same as for pharyngeal swab) into the bilateral lower fornix of each patient 3min after topical anesthesia by a drop of oxybuprocaine hydrochloride eye drop (4 mg/mL, Santen, Japan). Conjunctival scraping is performed with the cotton swab gently rubbing the lower fornix 5 times in each eye, the swabs were combined into the same sampling tube and sent for polymerase chain reaction (PCR; Figure 1).

All ocular samples were collected by a single physician with personal protective equipment recommended by the infection control guideline of the country and sent to molecular diagnostic units using the same protocols and products as routine pharyngeal swabs.

The samples were analyzed by using RT-PCR kits from at least two different companies simultaneously (Shengxiang Biological Technology and Shuoshi Biological Technology, China). Samples were handled following the protocol for the pharyngeal swab. Kits are targeting the open reading frame (ORF1ab) and nucleoprotein (N) gene domains of the COVID-19 virus, the specific primers were as follows^[6].

Target 1 (ORF1ab): Froward primer (F): CCCTGTG GGTTTTACTACTAA; reverse primer (R): ACGAT TGTGCATCAGCTGA; probe (P): 5’-FAM-CCGTCTG

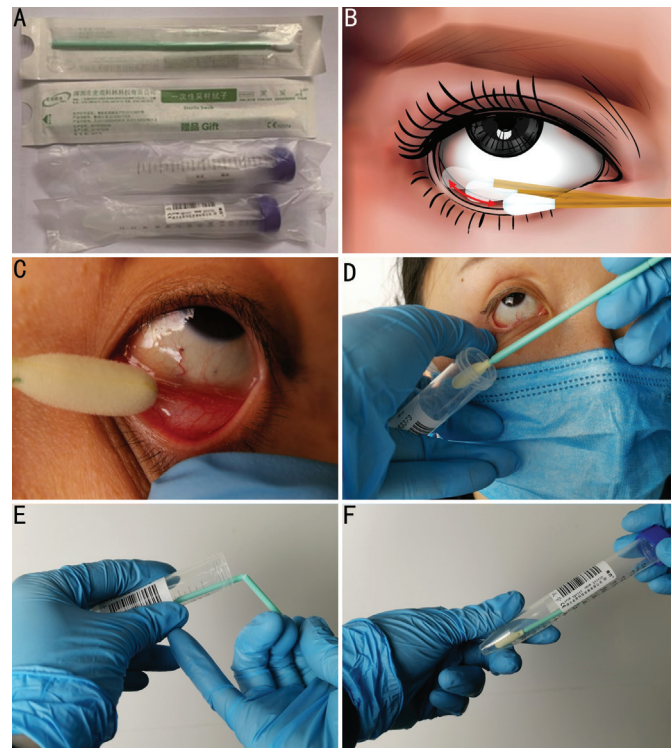


Figure 1 Tears and conjunctiva scrapes A: Swabs and sampling tubes used in this study; B: Illustration of the tears and conjunctiva scrape; C, D: After topical anesthesia, a sterile swab was put in the low fornix (C, D) and gently rub the conjunctiva of the lower fornix (area illustrated by the red arrow in B) for 5 times; E, F: Swabs of both eyes were collected in one sample tube and sent for PCR following the standard protocol for a pharyngeal swab^[5].

CGGTATGTGGAAAGGTTATGG-BHQ1-3’. Target 2 (N): F: GGGGAACCTTCTCCTGCTAGAAT; R: CAGACATTTTGCTCTCAAGCTG; P: 5’-FAM-TTGCTGTGCTTGACAGATT-TAMRA-3’.

RESULTS

Totally 255 laboratory-confirmed, non-severe COVID-19 patients were recruited for ocular manifestation investigation. Their demographic features and ocular characteristics were showed in Table 1. Among them 115 (45.1%) were males, aged 49.4±12.7y. Eleven patients (4.3%) complained of mild. Nonspecific symptoms such as dry eye and/or itchy eye, fatigue or fullness sensation of the eye, which could be due to the prolonged use of the smartphone or other visual terminals during isolation, partly supported by spontaneous resolve after stopping vision overload. Two (0.8%) had mild conjunctival congestion and serous secretion. None of the patients has evidence of keratitis, uveitis, or unexplained vision loss.

A total of 25 confirmed COVID-19 patients agreed for tear and conjunctival scrape sampling. Their mean age was 44.6±15.3y and 16 (64%) were males. They were recruited during the first (n=16, 64%), second (n=7, 28%), third (n=1, 4%) and fourth (n=1, 4%) weeks of their onsets. Their demographic and clinical features were shown in Table 2. In all tear and

Table 1 Demographic features and ocular characteristics of the 255 COVID-19 patients

Characteristics	All patients (n=255)	Tears & conj. tests (n=25)	PP results (n=4)	P (columns 2 and 3)
Demographic				
Age	49.4±12.7	44.6±15.3	42.25±8.8	0.578
Male	115 (45.1%)	16 (64%)	3 (75%)	0.626
Epidemiology history	253 (99.3%)	25 (100%)	4 (100%)	-
Clinical				
Dry eye	3	1	0	-
Itchiness	4	1	0	-
Transient blurred vision	4	0	0	-
Fullness	4	0	0	-
Foreign body sensation	0	0	0	-
Floater	0	0	0	-
Central vision loss	0	0	0	-
Visual field change	0	0	0	-
Conj. congestion	2	1	0	-
Serous secretion	2	1	0	-
Other	0	0	0	-

Conj.: Conjunctiva; PP: Possible positive (N gene positive).

Table 2 Patients with tears and conjunctiva scrapes for RT-PCR

ID	Gender	Age	Tears & conj. result	Sampling time ^a	Fever/respiratory	Ocular manifestation	Pneumonia on CT	Typical BR ^b
1	M	31	N	D6	+/+	No	+	+
2	M	46	N	D3	+/+	No	+	-
3	M	30	N	D2	-/+	No	+	-
4	F	31	N	D3	+/-	No	+	-
5	F	40	N	D6	-/+	No	+	+
6	M	37	N	D2	+/-	No	+	+
7	F	56	N	D10	-/+	No	+	+
8	M	64	N	D25	-/-	No	-	+
9	F	9	N	D4	-/-	No	-	+
10	M	33	N	D3	+/+	No	+	-
11	F	50	PP	D12	-/+	No	+	+
12	M	38	N	D2	+/+	No	+	-
13	M	56	N	D4	-/-	No	+	+
14	M	37	N	D5	-/+	No	+	+
15	M	49	PP	D8	+/+	No	-	+
16	M	28	PP	D4	-/-	No	-	+
17	F	46	N	D3	-/-	No	-	-
18	M	34	N	D10	+/-	Dry eye	+	-
19	F	84	N	D10	-/+	No	+	+
20	M	42	PP	D17	+/+	No	+	-
21	M	48	N	D4	-/-	No	+	-
22	F	39	N	D2	+/-	No	+	+
23	F	56	N	D6,D14	+/+	Conjunctivitis	+	+
24	M	62	N	D3	+/+	No	+	+
25	M	68	N	D13	+/+	No	-	-

^aSampling time from onset, in days. ^bLymphopenia and/or leukopenia. ID: Identification number; BR: Blood routine; CT: Computed topography; Conj.: Conjunctiva; PP: Possible positive (N gene positive); N: Negative.

conjunctival scraping samples, 4 have possible positive results in the N gene, the repetitive sampling 24h later yielded the same results, for which the PCR curves were shown in Figure 2. The mean duration from onset to sampling is 6.3d vs 8d in the possible positive group and negative group, with much

overlapping time in both groups. As the 2 patients with conjunctival congestion and tearing, one of them refused the conjunctival sampling and the other yielded a negative result. One patient (#16) were asymptomatic with near-normal chest CT and repeated positive results of both (1ab

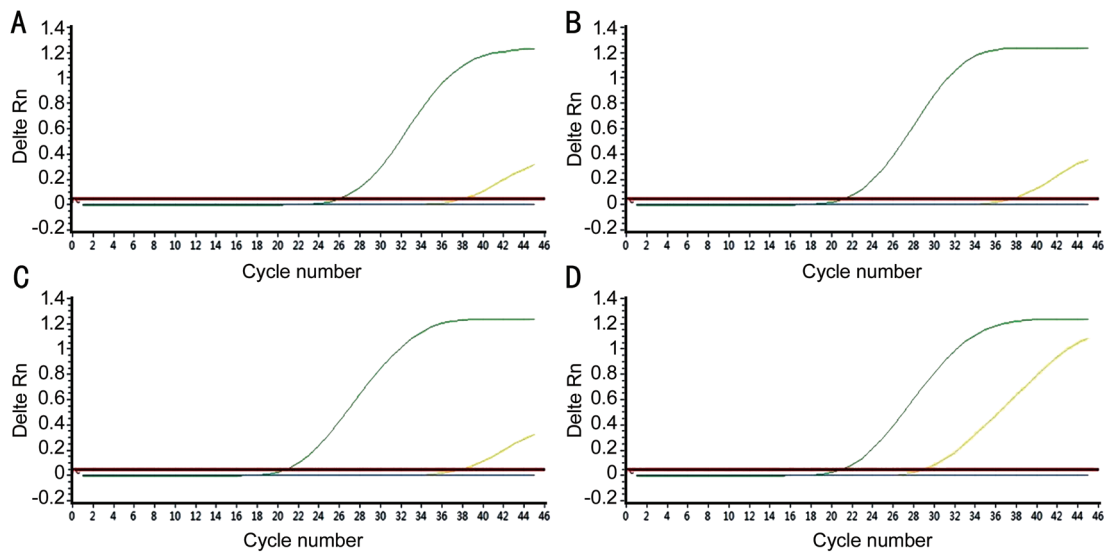


Figure 2 PCR curve of the 4 possible positive results in tears and conjunctiva scrape A: Patient #11; B: Patient #15; C: Patient #16; D: Patient#20.

and N gene positive) in all the pharyngeal, blood saliva and tear samples.

One patient has mild conjunctival hemorrhage with foreign body sensation from conjunctival scrapings, which spontaneously resolved 12h after. No other complication was reported. All patient recruited was checked with the symptoms and signs listed in Table 1.

Samples are judged as positive only when it showed both ORF1ab and N gene-positive reaction in both kits. Discordant results would be rechecked either with the third kit or another sampling.

DISCUSSION

It has been proven that COVID-19 can be transmitted by respiratory droplets and direct contact, fecal-oral and fomite transmission are also possible routes. Besides, tears and conjunctiva are speculated to be a way of transmission^[4]. Tears have been reported to be one of the body fluid reservoirs that might convey the SARS coronavirus, Ebola virus, *etc*^[7-8]; like SARS-CoV, COVID-19 virus is transmitted *via* ACE2 receptor, which can be found in conjunctiva and cornea^[9-10]. Evidences of COVID-19 virus in tears and conjunctiva is also accumulating^[11-12]. Eye protection was shown to be associated with less infection according to a recent Meta-analysis^[13], indicating that unprotected ocular surface as the entry of the virus cannot be ruled out.

Our study focused on non-severe (mild and moderate) COVID-19 patients, because these patients account for 80% of total laboratory-confirmed patients^[14], and they are less symptomatic, more socially active, therefore more likely to escape the surveillance and serve as infection sources. Our patients' cohort has a younger age compared with published data^[15-16], probably because elder patients are more prone to

be severe or critical cases. Two (0.8%) had mild conjunctival congestion and serous secretion; this percentage is lower than some of the earlier published studies^[17-18], but is consistent with the concurrent WHO report statistics^[14]. It is probably because of the difference of included population in regions, race, and pandemic stage.

Samples from 4 patients out of 25 showed possible positive (only N gene positive) with repeatability. These findings suggest presence COVID-19 virus in tear and conjunctiva. However, clinical significance of this phenomenon needs further study.

Analysis of the clinical features as the duration from onset, fever and/or respiratory symptoms, pneumonia on CT, or typical COVID-19 change in blood routine failed to identify any specific pattern or clinical correlation with the possible positive tears and conjunctival sample results. To further clarify this question, we probably need a larger sample size with more systemic registration of clinical information.

The negative results need prudent interpretations too. We have one patient (#15) who has negative results in both pharyngeal and conjunctiva three days before both samples turned possible positive of and confirmed the diagnosis. That reminds us of several possibilities in those with negative results. First, RT-PCR tests of viral nucleic acid are known to have high specificity but low sensitivity. It varies due to sampling location, quality, and different protocols. We employed multiple specimens and double-kit testing strategy to increase the sensitivity, still, negative test results cannot exclude the infection. Second, it is possible that the virus only present at a certain duration of the disease, which we might miss when sampling. Third, the virus copy numbers in our non-severe patients might not be high enough or be diluted by the anesthetic eye drops, to be detected.

This study is limited by the relatively small sample size and limited observation time of tear swab and conjunctival scraping taken from each patient.

Transmissibility of the tears and conjunctiva is neither confirm nor exclude by this study, so the next step for researchers would be virus culture and animal study to verify if the virus in the ocular surface is viable and infectible, its time-spatial distribution, and the optimal management of patients with a positive conjunctiva test. But the relatively low positive rate in the non-severe patients implies that the non-severe, thus more social-active patients are less likely to transmit COVID-19 through the ocular route, compare to the severe cases^[19].

In conclusion, this study showed that ocular manifestations are neither common nor specific in non-severe COVID-19 patients. Meanwhile, COVID-19 virus nucleotides can be detected in the tears and conjunctival scrape samples, warranting further research on the transmissibility by the ocular route. It seems clear that conjunctival swabs and conjunctival scrapings, though minimal invasive and convenient to perform, are not useful samples for COVID-19 diagnosis. The asymptomatic patient with possible positive tears and conjunctiva swab in our cohort also suggests that, at least for now, it is reasonable for ophthalmologists to treat COVID-19 as transmissible by conjunctiva and tears, to better protect our patients as well as ophthalmology professionals^[20].

ACKNOWLEDGEMENTS

We thank Dr. Shaobo Lei from the University of Toronto for proofreading of the manuscript.

Foundations: Supported by the National Natural Science Foundation of China (No.81300798); Natural Science Foundation of Hunan Province (No.2018JJ3737).

Conflicts of Interest: Jiang B, None; Li SJ, None; Wang WL, None; Hu M, None; He S, None; Cao J, None; Jiang L, None; Li Y, None.

REFERENCES

- 1 WHO. Coronavirus disease 2019 (COVID-19) Situation Report – 40 2020. <https://www.who.int/publications/m/item/weekly-epidemiological-update-on-covid-19---6-july-2021>.
- 2 WHO. Coronavirus disease (COVID-19) Pandemic 2020. <https://www.who.int/emergencies/diseases/novel-coronavirus-2019>.
- 3 Lu RJ, Zhao X, Li J, et al. Genomic characterisation and epidemiology of 2019 novel coronavirus: implications for virus origins and receptor binding. *Lancet* 2020;395(10224):565-574.
- 4 Lu CW, Liu XF, Jia ZF. 2019-nCoV transmission through the ocular surface must not be ignored. *Lancet* 2020;395(10224):e39.
- 5 China NHcotPsRo. Diagnosis and treatment of 2019-CoV (Sixth Edition). 2020. <http://www.nhc.gov.cn/yzygj/s7653p/202002/8334a8326dd94d329df351d7da8aefc2/files/b218cfcb1bc54639af227f922bf6b817.pdf>.
- 6 Chinacdc. Specific primers and probes for detection 2019 novel coronavirus

2020. http://ivdc.chinacdc.cn/kyjz/202001/t20200121_211337.html.
- 7 Loon SC, Teoh SC, Oon LL, Se-Thoe SY, Ling AE, Leo YS, Leong HN. The severe acute respiratory syndrome coronavirus in tears. *Br J Ophthalmol* 2004;88(7):861-863.
- 8 Vetter P, Fischer WA, Schibler M, Jacobs M, Bausch DG, Kaiser L. Ebola virus shedding and transmission: review of current evidence. *J Infect Dis* 2016;214(suppl 3):S177-S184.
- 9 Harmer D, Gilbert M, Borman R, Clark KL. Quantitative mRNA expression profiling of ACE2, a novel homologue of angiotensin converting enzyme. *FEBS Lett* 2002;532(1-2):107-110.
- 10 Sun Y, Liu L, Pan X. Mechanism of action between the SARS-CoV S240 protein and ACE2 receptor in eyes. *Guoji Yanke Zazhi (Int Eye Sci)* 2006;6(4):783-786.
- 11 Xia JH, Tong JP, Liu MY, Shen Y, Guo DY. Evaluation of coronavirus in tears and conjunctival secretions of patients with SARS-CoV-2 infection. *J Med Virol* 2020;92(6):589-594.
- 12 Zhou YY, Zeng YY, Tong YQ, Chen CZ. Ophthalmologic evidence against the interpersonal transmission of 2019 novel coronavirus through conjunctiva. *MedRxiv* 2020:20021956.
- 13 Chu DK, Akl EA, Duda S, Solo K, Yaacoub S, Schünemann HJ, COVID-19 Systematic Urgent Review Group Effort (SURGE) study authors. Physical distancing, face masks, and eye protection to prevent person-to-person transmission of SARS-CoV-2 and COVID-19: a systematic review and Meta-analysis. *Lancet* 2020;395(10242):1973-1987.
- 14 WHO. Report of the WHO-China Joint Mission on Coronavirus Disease 2019 (COVID-19) 2020. <https://www.who.int/docs/default-source/coronaviruse/who-china-joint-mission-on-covid-19-final-report.pdf>.
- 15 Guan WJ, Ni ZY, Hu Y, et al. Clinical Characteristics of Coronavirus Disease 2019 in China. *N Engl J Med* 2020;382(18):1708-1720.
- 16 Epidemiology Working Group for NCIP Epidemic Response, Chinese Center for Disease Control and Prevention. The epidemiological characteristics of an outbreak of 2019 novel coronavirus diseases (COVID-19) in China. *Zhonghua Liu Xing Bing Xue Za Zhi* 2020;41(2):145-151.
- 17 Wu P, Duan F, Luo CH, Liu Q, Qu XG, Liang L, Wu KL. Characteristics of ocular findings of patients with coronavirus disease 2019 (COVID-19) in Hubei Province, China. *JAMA Ophthalmol* 2020;138(5):575.
- 18 Pereira LA, Soares LCM, Nascimento PA, Cirillo LRN, Sakuma HT, Veiga GLD, Fonseca FLA, Lima VL, Abucham-Neto JZ. Retinal findings in hospitalised patients with severe COVID-19. *Br J Ophthalmol* 2020:bjophthalmol-2020.
- 19 Karimi S, Arabi A, Shahraki T, Safi S. Detection of severe acute respiratory syndrome Coronavirus-2 in the tears of patients with Coronavirus disease 2019. *Eye (Lond)* 2020;34(7):1220-1223.
- 20 Sadhu S, Agrawal R, Pyare R, Pavesio C, Zierhut M, Khatri A, Smith JR, de Smet MD, Biswas J. COVID-19: limiting the risks for eye care professionals. *Ocul Immunol Inflamm* 2020;28(5):714-720.