

# Role of artificial tears with and without hyaluronic acid in controlling ocular discomfort following PRK: a randomized clinical trial

Mehrdad Mohammadpour<sup>1</sup>, Masoud Khorrami-Nejad<sup>1,2</sup>, Delaram Shakoor<sup>1</sup>

<sup>1</sup>Translational Ophthalmology Research Center, Farabi Eye Hospital, Tehran University of Medical Sciences, Tehran 1336616351, Iran

<sup>2</sup>School of Rehabilitation, Tehran University of Medical Sciences, Tehran 1148965111, Iran

**Correspondence to:** Mehrdad Mohammadpour. Translational Ophthalmology Research Center, Farabi Eye Hospital, Tehran University of Medical Sciences, Tehran 1336616351, Iran. mahammadpour@yahoo.com

Received: 2020-08-15 Accepted: 2021-03-03

## Abstract

• **AIM:** To compare outcomes of applying preservative free artificial tears (PFAT) with and without hyaluronic acid (HA) in early postoperative course following photorefractive keratectomy (PRK).

• **METHODS:** In this triple-blinded randomized clinical trial, PRK procedure was performed on both eyes of 230 patients. Following PRK, patients were divided into three groups: the HA<sup>+</sup> group, 44 patients PFAT containing HA; the HA<sup>-</sup> group, 71 patients PFAT without HA were administered 5 times per day (every 4h); the third group, 115 patients received no PFAT before lens removal. On the 1<sup>st</sup> and 4<sup>th</sup> postoperative day, Visual Analogue Score (VAS) was utilized to evaluate patient's level of pain. Participants were asked to complete a questionnaire about the severity of eye discomfort ranked from 0 to 10 (0=no complaint; 10=most severe complaint experienced).

• **RESULTS:** In eyes receiving PFAT with or without HA (Drop group), mean scores for epiphora, foreign body sensation, and blurred vision on the 1<sup>st</sup> postoperative day were statistically lower ( $P<0.05$ ). Filamentous keratitis (FK) was detected in 11 (4.7%) eyes, and recurrent corneal erosion (RCE) was observed in 5 (2.1%) eyes. In the control group, FK was noted in 16 (6.9%) eyes while 13 (5.6%) eyes had RCE and 5 (2.1%) eyes had corneal haze. The rate of complications was statistically lower in Drop group ( $P=0.009$ ). However, the aforementioned scores were not statically different between HA<sup>+</sup> and HA<sup>-</sup> group one and two ( $P=0.29$ ).

• **CONCLUSION:** Following PRK, applying PFAT with and without HA yields faster visual recovery, decreases postoperative ocular discomfort and haze formation; however there is no additive effect for HA.

• **KEYWORDS:** artificial tears; hyaluronic acid; ocular discomfort; photorefractive keratectomy

**DOI:10.18240/ijo.2021.08.14**

**Citation:** Mohammadpour M, Khorrami-Nejad M, Shakoor D. Role of artificial tears with and without hyaluronic acid in controlling ocular discomfort following PRK: a randomized clinical trial. *Int J Ophthalmol* 2021;14(8):1225-1230

## INTRODUCTION

To correct refractive errors, laser assisted refractive surgeries have been used to alter corneal curvature by using excimer laser<sup>[1-2]</sup>. Various approaches have been used to achieve this issue and laser *in situ* keratomileusis (LASIK) is the most popular technique<sup>[3-4]</sup>, however since it involves creating a stromal flap, it is associated with intraoperative and postoperative complications such as flap related problems and corneal ectasia, respectively<sup>[5]</sup>. Surface ablation procedures including photorefractive keratectomy (PRK) are flapless, safer options which can be employed for patients with thin corneas and active life style with environmental hazards<sup>[6]</sup>. Nevertheless, in the latter, the corneal epithelium is debrided which initiates a set of inflammatory reactions and consequently wound healing response. Therefore, patients who undergo PRK experience more postoperative discomfort and delayed visual rehabilitation<sup>[3,6-8]</sup>. Numerous agents such as steroids, nonsteroidal anti-inflammatory and artificial tear drops have been used to prevent inflammatory response and enhance epithelial regeneration which facilitates early visual recovery and ultimately improves visual outcome<sup>[9]</sup>.

Hyaluronic acid (HA) is an extracellular glycosaminoglycan which can be found in the vitreous, lacrimal gland, corneal epithelium, conjunctiva and tear fluid<sup>[10-12]</sup>. Due to its viscoelastic and protective effect against oxidative damage, Sodium hyaluronate 1% has been widely used in the

ophthalmic practice<sup>[13-14]</sup>. It also enhances water retention on the corneal surface which increases the tear film stabilization and tear break-up time. Thus, it has been utilized in some artificial tears for the treatment of dry eye syndrome<sup>[15]</sup>. A study on rabbits have shown that HA has a major impact on corneal epithelial healing. It modifies cellular proliferation, differentiation and more importantly promotes epithelial cells migration which is the basis of the corneal wound healing process<sup>[16]</sup>. It also plays an anti-inflammatory role in conditions, such as wound repair<sup>[14]</sup>.

Few studies have been performed to evaluate the role of HA in epithelial healing<sup>[14,16]</sup>, however, to the best of our knowledge no study has yet assessed the application of HA in refractive surgeries on human subjects. In this study we intend to compare the effects of preservative free artificial tear (PFAT) drops with and without HA in reducing ocular discomfort, enhancing reepithelialization and improving visual outcomes following PRK.

## SUBJECTS AND METHODS

**Ethical Approval** All aspects of the present study were approved by the Institutional Review Board and Ethics Committee of Farabi Eye Hospital and Tehran University of Medical Sciences. The trial also adhered to the tenets of Helsinki treaty and was approved in Iranian Randomized Clinical Trial (IRCT ID=IRCT2013060713567N2). Informed consent was obtained from study participants.

**Study Design and Participants** This single center, triple-blinded randomized controlled trial was conducted at Farabi Eye Hospital, a tertiary center, affiliated to Tehran University of Medical Sciences, Tehran, Iran. The study recruited participants undergoing PRK procedure. Patients over 18 years of age who had documented refraction stability over last year were eligible to be enrolled. Individuals with myopia more than -8.0 D, astigmatism more than 3.0 D, hyperopia more than +4.0 D, corneal stroma less than 480  $\mu\text{m}$  and mesopic pupil size more than 6 mm were excluded. Patients with herpetic keratitis, keratoconus, corneal dystrophy, corneal degeneration, cataract, glaucoma, dry eye, lagophthalmos, uveitis, blepharitis, pregnancy, breast feeding, past medical history of diabetes, keloid formation, autoimmune, and immunodeficiency disorders were not enrolled.

**Surgical Procedure** All PRK surgeries were performed by one surgeon (Mohammadpour M). To induce anesthesia, topical tetracaine 0.5% was applied in both eyes. Alcohol solution 20% was applied for 20s and rinsed with 50 mL balanced salt solution (BSS). The corneal epithelium was removed by using a hockey spatula and a standard 8.5 mm epithelial defect was generated. Stromal ablation was performed by Technolas 217-Z excimer laser (Bausch & Lomb). Mitomycin 0.02% was applied for 30s on the stromal surface

and rinsed with 50 mL BSS. Following instilment of one eye drop of chloramphenicol, Comflicon A contact lenses (Biofinity, Cooper vision care, USA, FDA approved for seven days constant wear) were laid over both eyes.

**Postoperative Protocol and Follow Up** According to random number table, subjects were divided to three groups. In the first group, 44 patients received HA containing PFAT (Artelac advance: preservative free sodium hyaluronate 0.2% artificial tear drop, Bausch & Lomb) 5 times per day (every 4h). In the second group, 71 patients received HA free PFAT (Artelac, PFAT drop, Bausch & Lomb) 5 times per day (every 4h) and in the control group, 115 patients received no artificial tear. However, all patients received artificial tear drop after bandage contact lens removal. We scratched the labels on each tear drop container before providing it to the patients, in order to keep them blind about the drug they were using. All the drop bottles had similar sizes, appearances, and colors. In addition, the type of scratching of labels was the same in all patients. The rest of the protocol was similar. In the first 24h, patients also received topical diclofenac 0.1% every 6h. Chloramphenicol 0.1% was applied every 6h for 4d. Betamethasone 0.1% was employed for two weeks and then changed to floumetholone eye drop every 12h over the next two months. All cases received PFAT after contact lens removal for three months postoperatively.

On the first and fourth postoperative day, Visual Analogue Score (VAS) was utilized to evaluate patient's level of pain in which zero means no pain and 10 means worst pain experienced by the patient. Also, participants were asked to complete a questionnaire about the severity of eye discomfort ranked from zero to ten (0=no complaint; 10=most severe complaint experienced). The main components of eye discomfort included pain, epiphora, foreign body sensation, blurred vision, and photophobia. All patients received a slit-lamp examination on first postoperative day for anterior segment pathology. On the fourth day after surgery which the bandage lenses were removed, participants were examined by slit lamp to detect complications such as corneal haze, epithelial defect, and filamentous keratitis (FK). In the first- and third-month follow-up, uncorrected visual acuity (UCVA) and best corrected distance visual acuity (CDVA) were recorded. All medications were stopped at least 6h before measuring these parameters.

**Sample Size Calculation and Statistical Analysis** In order to get one significant difference between three groups in the main outcome measure, which is postoperative ocular pain and discomfort, a sample size of at least 39 patients in each group was calculated by means of the following formula:

$$n = \frac{2 \left( Z_{\alpha} + Z_{\beta} \right)^2}{d^2}$$

**Table 1 Eye discomfort parameters scores between drop and control groups**

Eye discomfort parameters	Postop. day	Drop groups	Control group	P
Pain	1 <sup>st</sup>	5.54±3.392	5.68±3.483	0.541
	4 <sup>th</sup>	4.20±3.186	3.81±3.056	0.185
Photophobia	1 <sup>st</sup>	6.50±3.099	6.79±3.084	0.234
	4 <sup>th</sup>	5.47±2.773	5.20±3.038	0.319
Epiphora	1 <sup>st</sup>	5.76±3.622	6.58±3.516	0.010
	4 <sup>th</sup>	3.53±3.120	3.39±2.970	0.713
Foreign body sensation	1 <sup>st</sup>	5.17±3.333	5.86±3.277	0.031
	4 <sup>th</sup>	5.27±3.116	4.71±3.463	0.057
Blurred vision	1 <sup>st</sup>	5.57±3.044	6.24±2.880	0.030
	4 <sup>th</sup>	5.60±2.659	5.72±2.799	0.573

Power of the study was considered 80% with SD of 1.4 and confidence interval of 0.05. Statistical analysis was conducted by means of SPSS for Windows software (version 20, SPSS, Inc.). Chi-square test was employed to evaluate the descriptive data between the study groups. We used Mann-Whitney to compare the quantitative data between the Drop group that received PFAT (group one and two) and control group with no PFAT (group three). Kruskal-Wallis ANOVA by ranks and median test combined with multiple comparisons between three groups was used to analyze all the variables. The level of significance was considered 0.05. All data are demonstrated in mean±SD. The examiner, patients, and the analyzer were all kept masked throughout the study.

## RESULTS

Both eyes of 230 consecutive patients underwent PRK surgery. Groups one and two (Drop group) consisting of 115 patients received PFAT (mean age 28.91±6.44y, female/male ratio=1.7). Group one who received Artelac advanced drop consisted of 44 patients (mean age 28.61±6.1y, female/male ratio=1.5) and group two entailed 71 patients in which Artelac drop was administered (mean age 29.21±6.7y, female/male ratio=1.8). The control group was consisting of 115 patients which did not receive PTAT (mean age 28.75±6.3y, female/male ratio=2).

Concerning postoperative pain and photophobia, no significant difference was observed between drop and control groups in the first and fourth postoperative days ( $P < 0.05$ ). However, the mean scores for epiphora, foreign body sensation and blurred vision on first postoperative day were statistically lower in Drop group ( $P = 0.010, 0.031, 0.03$ , respectively; Table 1).

Means of UCVA at one and three months follow up were significantly lower in HA<sup>+</sup> and HA<sup>-</sup> groups compare to control group ( $P = 0.03, P = 0.02$  respectively; Figure 1A). At three months follow up, averages of CDVA were significantly lower in Drop group ( $P = 0.002$ ; Figure 1B).

In Drop group, FK was detected in 11 (4.7%) eyes and recurrent corneal erosion (RCE) was observed in 5 (2.1%) eyes. In control group, FK was noted in 16 (6.9%) eyes while

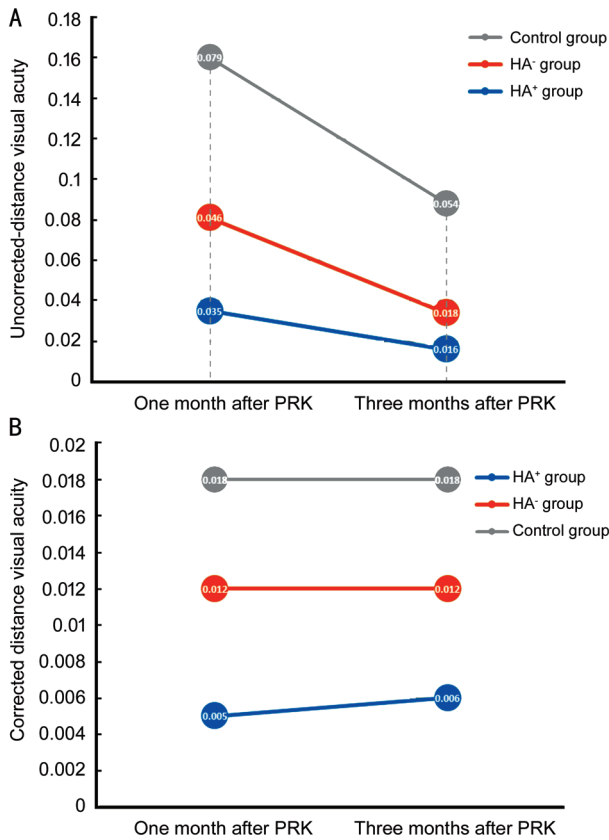
13 (5.6%) eyes had RCE and 5 (2.1%) eyes had corneal haze. In Drop group, RCE and haze were significantly lower than control group ( $P = 0.050, P = 0.026$  respectively), but FK did not have any significant difference ( $P = 0.345$ ).

Means of blurred vision on the first and fourth postoperative day were significantly lower in HA<sup>+</sup> group compare with HA<sup>-</sup> group ( $P = 0.035$  and  $P = 0.042$ , respectively). However, other pain and discomfort parameters scores showed no difference between HA<sup>+</sup> and HA<sup>-</sup> groups ( $P > 0.05$ ). Regarding visual acuity, although means of UCVA and CDVA at one and three month follow up were lower in HA<sup>+</sup> group compare with HA<sup>-</sup> group, the differences were not statistically significant ( $P = 0.28$ ; Figure 1A and 1B). In HA<sup>+</sup> group, 2 (2.2%) eyes were diagnosed with FK and RCE was noted in 5 (5.6%) eyes. In HA<sup>-</sup> group, FK and RCE were observed in 3 (2.1%) and 6 (4.2%) eyes, respectively (Figure 2). The difference between rate of all complications was not significant between HA<sup>+</sup> and HA<sup>-</sup> group ( $P < 0.05$ ).

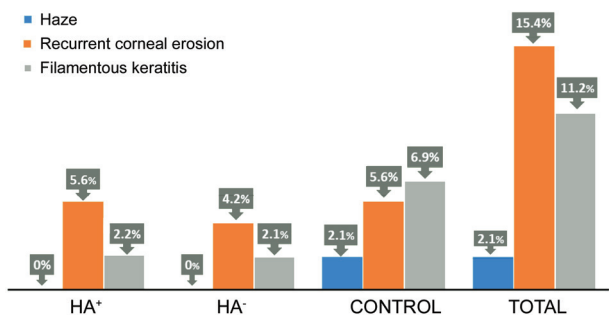
Blurred vision and eye discomfort parameters' scores in HA<sup>+</sup>, HA<sup>-</sup>, and control groups in the one and four days after PRK is shown in Figure 3.

## DISCUSSION

The findings of the present triple blinded controlled trial revealed that PFAT improve the outcomes of PRK surgery regarding postoperative eye discomfort, visual recovery time, and rate of complications; however there was no significant difference between artificial tears with and without HA in the early postoperative course following PRK. Patients who received PFAT drops had lower postoperative means of foreign body sensation, blurred vision, and epiphora. Since wound healing process after PRK plays a crucial role in the outcome of surgery, great attention has been drawn to understanding the physiology of wound healing after PRK<sup>[17]</sup>. As already known, PRK surgery entails debridement of epithelial layer. The injured epithelium by releasing inflammatory cytokines such as IL-1 mediates keratocyte apoptosis in the underlying layer which is the first detectable event in the healing process. Within 24h

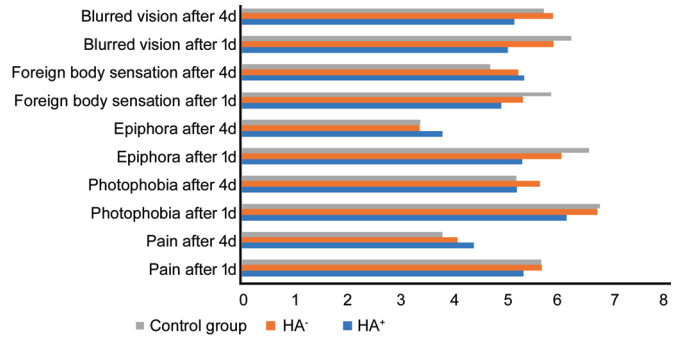


**Figure 1** The means of uncorrected and corrected visual acuity in one and three months following PRK. A: The means of uncorrected visual acuity (logMAR system) between three groups in one and three months following PRK; B: The means of corrected distance visual acuity between the three groups in one and three months following PRK. HA: Hyaluronic acid; PRK: Photorefractive keratectomy.



**Figure 2** Percentage of patients (the Y axis) with postoperative complications in HA<sup>+</sup>, HA<sup>-</sup>, and control groups. HA: Hyaluronic acid; PRK: Photorefractive keratectomy.

of keratocyte disappearance, the remaining keratocytes initiate proliferation and differentiate to myofibroblasts. These wound healing related cells migrate to stroma to produce extracellular components including collagen fibers, glycosaminoglycans, and growth factors which stimulates epithelial healing. All these processes are mediated by growth factors such as platelet derived growth factor released from the injured epithelium. An important cytokine in modulating stromal healing response is transforming growth factor beta (TGF-β). The more TGF-β



**Figure 3** Blurred vision and eye discomfort parameters' scores in HA<sup>+</sup>, HA<sup>-</sup> and control groups in the one and four days after PRK. HA: Hyaluronic acid; PRK: Photorefractive keratectomy.

is released, the more aggressive wound healing response and higher opacity in stroma may develop. The epithelial healing process involves proliferation and migration of the remaining epithelial cells and forming hemidesmosome and anchoring to the underlying layers of cornea. Myofibroblasts regulate epithelial healing by producing cytokines including haptocyte and keratinocyte growth factors<sup>[17-20]</sup>.

Cornea consists of six layers and has no vascular supply to meet its demand. The precorneal tear film and the aqueous humor provide cornea's nutrients and oxygen. In a normal eye, tear production is a result of interaction between lacrimal glands, eyelids, and interconnecting nerve plexus. Reduced corneal sensitivity as a result of damage to sub-epithelial nerve plexus disrupts this integrated cycle resulting in reduced tear flow and tear film stability. Therefore, refractive surgeries, due to postoperative corneal hypoesthesia is associated with development of dry eyes<sup>[2,21]</sup>. Artificial tear drops have been the most common treatment of patients with dry eyes. Although a genuine substitute of human natural tear has not been produced, artificial tear drops have been successful in alleviating eye discomforts related with dry eye<sup>[22-23]</sup>. However, according to large body of evidence, PFAT drops have better outcomes owing to lack of toxic effect of preservatives on fragile healing epithelium<sup>[24]</sup>.

Moreover, precorneal tear film plays a key role in the formation of a clear retinal image since it is one of the most vital refractive interfaces in the eye. Consequently, disruption of tear film which leads to irregularities on the corneal surface, affect visual function. However there has been a discrepancy in the effect of artificial tear drops on visual improvement. While most studies report improvement, others observed no change in visual function<sup>[23,25]</sup>. We noted that patients receiving the artificial tear drops had better outcomes and the means. LogMAR of UCVA and BCVA at one month follow up were significantly lower than the control group. Furthermore, the total rate of complications was significantly lower and corneal haze was not observed in groups one and two. It may



be assumed that artificial tear drops provide a more stable microenvironment for epithelial cells regeneration which leads to faster visual recovery and less complication. In addition, they alleviate symptoms of ocular irritation which reduce the rate of microtrauma to the fragile epithelial layer which results in enhanced epithelial healing, improved visual acuity and lower rate of complications<sup>[23,26]</sup>.

One of the major drawbacks of PRK surgery is corneal haze which is an optical disturbance due to a change in corneal transparency<sup>[27-28]</sup>. In our study, corneal haze was not observed in patients who received artificial tear drops. Several hypotheses has been proposed for development of haze in patients undergoing PRK. Data from studies performed on rabbits and human beings confirmed that haze formation is a direct consequence of increased number of wound healing keratocytes<sup>[20,27]</sup>. Another study performed on rabbit models noted that administration of neutralizing antibodies to TGF- $\beta$  prevented development of haze after PRK<sup>[29]</sup>. Consequently, a cytokine mediated intracellular interaction between stromal keratocytes and newly forming epithelial layer may have a key role in development of haze. We believe that application of PFAT drops may dilute the inflammatory cytokines, improve epithelial healing and inhibit development of haze in PRK patients. Since it is not accompanied with side effects of corticosteroid drops, which is one of the treatment regimen for management of corneal haze, hence provides superior outcomes for PRK patients.

Due to the importance of healing process in the outcome of PRK and a decrease in tear flow following the procedure, artificial tear drops, by providing a stable, radical free microenvironment, and attenuating the inflammatory response *via* diluting inflammatory mediator's concentration in tear film, may result in superior results. However, the presence of HA in PFAT does not seem to have an additional effect. This finding could be attributed to increased viscosity of the HA containing artificial tear drops which increases osmolarity of the tear film. Unfortunately, we were not able to assess the tear film osmolarity. However, it's been suggested that following refractive surgeries, tear film osmolarity increases due to a significant decline in tear flow and break up time which leads to an increase in tear film evaporation<sup>[30-31]</sup>. Furthermore, previous reports on dry eye patients suggested that increased osmolarity may cause damage to the ocular surface, since it initiates a cycle of inflammation which contributes to chronic epithelial stress and ocular discomfort. In addition, there's a direct link between tear hyperosmolarity and tear flow instability which deteriorates the condition in dry eye patients<sup>[32-33]</sup>. Hence, adding HA to the artificial tear drops in the short-term postoperative time may not yield better results, due to its possible impact on increasing tear osmolarity<sup>[34]</sup>.

The present study had several limitations. One is the short course of follow up following surgery and another is that the tear osmolarity was not evaluated in postoperative course. In addition, the patients in three groups were not matched, though the means of age and female/male ratios were not significantly different.

In conclusion, the present study showed that application of artificial tear drops in early postoperative course following PRK surgery can improve early ocular discomfort and visual rehabilitation. In addition, it may play a role in decreasing postoperative complications especially corneal haze formation. The effect of adding HA to artificial tear drops has to be further evaluated in future studies with larger sample sizes, longer follow ups and tear osmolarity measurement.

#### ACKNOWLEDGEMENTS

**Conflicts of Interest:** Mohammadpour M, None; Khorrami-Nejad M, None; Shakoob D, None.

#### REFERENCES

- 1 Kim TI, Alió del Barrio JL, Wilkins M, Cochener B, Ang M. Refractive surgery. *Lancet* 2019;393(10185):2085-2098.
- 2 Mohammadpour M, Khorrami-Nejad M, Chini-Foroush N. Correlation between iris-registered static and dynamic cyclotorsions with preoperative refractive astigmatism in PRK candidates. *J Curr Ophthalmol* 2019;31(1):36-42.
- 3 Manche E, Roe J. Recent advances in wavefront-guided LASIK. *Curr Opin Ophthalmol* 2018;29(4):286-291.
- 4 Sandoval HP, Donnenfeld ED, Kohnen T, Lindstrom RL, Potvin R, Tremblay DM, Solomon KD. Modern laser *in situ* keratomileusis outcomes. *J Cataract Refract Surg* 2016;42(8):1224-1234.
- 5 Randleman JB, Shah RD. LASIK interface complications: etiology, management, and outcomes. *J Refract Surg* 2012;28(8):575-586.
- 6 Katz TR. Safety, efficacy and predictability of SAT. *Complications in Corneal Laser Surgery*. Cham: Springer International Publishing, 2016:23-30.
- 7 Toda I. Dry eye after LASIK. *Invest Ophthalmol Vis Sci* 2018;59(14):DES109-DES115.
- 8 Mohammadpour M, Maleki S, Khorrami-Nejad M. The effect of tea tree oil on dry eye treatment after phacoemulsification cataract surgery: a randomized clinical trial. *Eur J Ophthalmol* 2020;30(6):1314-1319.
- 9 Golan O, Randleman JB. Pain management after photorefractive keratectomy. *Curr Opin Ophthalmol* 2018;29(4):306-312.
- 10 Chang WH, Liu PY, Lin MH, Lu CJ, Chou HY, Nian CY, Jiang YT, Hsu YH. Applications of hyaluronic acid in ophthalmology and contact lenses. *Molecules* 2021;26(9):2485.
- 11 You IC, Li Y, Jin RJ, Ahn M, Choi W, Yoon KC. Comparison of 0.1%, 0.18%, and 0.3% hyaluronic acid eye drops in the treatment of experimental dry eye. *J Ocular Pharmacol Ther* 2018;34(8):557-564.
- 12 Frescura M, Berry M, Corfield A, Carrington S, Easty DL. Evidence of hyaluronan in human tears and secretions of conjunctival cultures. *Biochem Soc Trans* 1994;22(2):228S.

- 13 Singh A, Li P, Beachley V, McDonnell P, Elisseff JH. A hyaluronic acid-binding contact lens with enhanced water retention. *Contact Lens Anterior Eye* 2015;38(2):79-84.
- 14 Ling K, Bastion MC. Use of commercially available sodium hyaluronate 0.18% eye drops for corneal epithelial healing in diabetic patients. *Int Ophthalmol* 2019;39(10):2195-2203.
- 15 Ang BCH, Sng JJ, Wang PXH, Htoon HM, Tong LHT. Sodium hyaluronate in the treatment of dry eye syndrome: a systematic review and meta-analysis. *Sci Rep* 2017;7(1):9013.
- 16 Gomes JP. Sodium hyaluronate (hyaluronic acid) promotes migration of human corneal epithelial cells *in vitro*. *Br J Ophthalmol* 2004;88(6):821-825.
- 17 Wilson SE. The wound healing response after laser *in situ* keratomileusis and photorefractive keratectomy. *Arch Ophthalmol* 2001;119(6):889.
- 18 Fagerholm P. Wound healing after photorefractive keratectomy. *J Cataract Refract Surg* 2000;26(3):432-447.
- 19 Park CK, Kim JH. Comparison of wound healing after photorefractive keratectomy and laser *in situ* keratomileusis in rabbits. *J Cataract Refract Surg* 1999;25(6):842-850.
- 20 Møller-Pedersen T, Li HF, Petroll WM, Cavanagh HD, Jester JV. Confocal microscopic characterization of wound repair after photorefractive keratectomy. *Invest Ophthalmol Vis Sci* 1998;39(3):487-501.
- 21 Quinto GG, Camacho W, Behrens A. Postrefractive surgery dry eye. *Curr Opin Ophthalmol* 2008;19(4):335-341.
- 22 O'Brien PD, Collum LM. Dry eye: diagnosis and current treatment strategies. *Curr Allergy Asthma Rep* 2004;4(4):314-319.
- 23 Salib GM, McDonald MB, Smolek M. Safety and efficacy of cyclosporine 0.05% drops versus unpreserved artificial tears in dry-eye patients having laser *in situ* keratomileusis. *J Cataract Refract Surg* 2006;32(5):772-778.
- 24 Berdy GJ. Preservative-free artificial tear preparations. *Arch Ophthalmol* 1992;110(4):528.
- 25 Huang FC, Tseng SH, Shih MH, Chen FK. Effect of artificial tears on corneal surface regularity, contrast sensitivity, and glare disability in dry eyes. *Ophthalmology* 2002;109(10):1934-1940.
- 26 Liu Z, Pflugfelder SC. Corneal surface regularity and the effect of artificial tears in aqueous tear deficiency. *Ophthalmology* 1999;106(5):939-943.
- 27 Tani E, Katakami C, Negi A. Effects of various eye drops on corneal wound healing after superficial keratectomy in rabbits. *Jpn J Ophthalmol* 2002;46(5):488-495.
- 28 Dutescu RM, Panfil C, Schrage N. Comparison of the effects of various lubricant eye drops on the *in vitro* rabbit corneal healing and toxicity. *Exp Toxicol Pathol* 2017;69(3):123-129.
- 29 Møller-Pedersen T, Cavanagh HD, Petroll WM, Jester JV. Neutralizing antibody to TGF $\beta$  modulates stromal fibrosis but not regression of photoablative effect following PRK. *Ceyr* 1998;17(7):736-747.
- 30 Horwath-Winter J, Vidic B, Schwantzer G, Schmut O. Early changes in corneal sensation, ocular surface integrity, and tear-film function after laser-assisted subepithelial keratectomy. *J Cataract Refract Surg* 2004;30(11):2316-2321.
- 31 Lee JB, Ryu CH, Kim J, Kim EK, Kim HB. Comparison of tear secretion and tear film instability after photorefractive keratectomy and laser *in situ* keratomileusis. *J Cataract Refract Surg* 2000;26(9):1326-1331.
- 32 Lemp MA, Bron AJ, Baudouin C, Benítez Del Castillo JM, Geffen D, Tauber J, Foulks GN, Pepose JS, Sullivan BD. Tear osmolarity in the diagnosis and management of dry eye disease. *Am J Ophthalmol* 2011;151(5):792-798.e1.
- 33 Tear film analysis and evaluation of optical quality: a review of the literature (French translation of the article). *J Fr Ophtalmol* 2019;42(3):226-243.
- 34 Iester M, Orsoni GJ, Gamba G, Taffara M, Mangiafico P, Giuffrida S, Rolando M. Improvement of the ocular surface using hypotonic 0.4% hyaluronic acid drops in keratoconjunctivitis sicca. *Eye (Lond)* 2000;14(6):892-898.