

# Effects of dietary high dose DHA omega-3 supplement in dry eye with meibomian gland dysfunction

Yeon Ji Jo, Jong Soo Lee

Department of Ophthalmology, Pusan National University School of Medicine&Medical Research Institute of Pusan National University Hospital, Busan 49241, Republic of Korea

**Correspondence to:** Jong Soo Lee. Department of Ophthalmology, Pusan National University Hospital 179, Gudeok-ro, Seo-gu, Busan 49241, Republic of Korea. jongsool@pusan.ac.kr

Received: 2020-10-25 Accepted: 2021-01-20

## Abstract

• **AIM:** To evaluate the clinical efficacy of dietary supplement of high dose DHA omega-3 in dry eye with meibomian gland dysfunction (MGD).

• **METHODS:** Prospective randomized double-masked, placebo-controlled clinical trial was conducted in mild to moderate dry eye patients with MGD. Patients have no history of taking any dietary omega-3 supplements before 3mo. Patients were divided into two groups: 24 patients in the omega-3 group and 26 patients in the placebo group. The omega-3 group received two capsules of Easyeye Dry<sup>®</sup>, total containing 600 mg of EPA and 1640 mg of DHA, while the placebo group received two capsules containing 3000 mg of olive oil. All patients take two pills once a day. The examination of MGD scores, tear break-up time (TBUT), corneal staining test (NEI), strip meniscometry (SM tube), and ocular surface disease index (OSDI) scores were performed at baseline, after 4 and 8wk.

• **RESULTS:** A total of 50 patients were included. There were no differences in baseline characteristics between the two groups, such as age, sex, and other ocular examination findings. The TBUT, NEI, and OSDI scores significantly improved after 4 and 8wk in both groups. While after 8wk TBUT ( $6.00 \pm 1.62$ s vs  $5.08 \pm 1.28$ s,  $P=0.034$ ) and MGD score ( $7.2 \pm 1.8$  vs  $8.1 \pm 2.6$ ,  $P=0.033$ ) in the omega-3 group was more significantly improved than that of the placebo group.

• **CONCLUSION:** Dry eye with the MGD patient, a high dose of DHA omega-3 dietary supplement can improve TBUT and MGD score after 8wk, effective in stabilizing the tear film.

• **KEYWORDS:** DHA; dietary supplement; dry eye disease; meibomian gland dysfunction

DOI:10.18240/ijo.2021.11.08

**Citation:** Jo YJ, Lee JS. Effects of dietary high dose DHA omega-3 supplement in dry eye with meibomian gland dysfunction. *Int J Ophthalmol* 2021;14(11):1700-1706

## INTRODUCTION

Dry eye disease (DED) is a multifactorial chronic inflammatory condition of the ocular surface that results in ocular discomfort and visual disturbance. The prevalence of DED is estimated at 10.4% of the Korean people<sup>[1]</sup>. DED is continually increasing due to various factors such as aging, intensive use of computer and smartphone, contact lenses wearing, and corneal refractive surgery<sup>[2-3]</sup>. The artificial tear is the first choice of treatment for DED, but the symptoms and signs of some DED are not alleviated completely by artificial tears. Thus, the various methods such as using steroid eye drops or autologous serum, punctal occlusion are used for chronic and severe DED. Regardless of the various treatment methods for dry eye existed, many DED patients suffering from chronic discomfort of dry eye.

The leading cause of DED is known due to obstructive meibomian gland dysfunction (MGD). MGD is caused by hyper-keratinization of the ductal epithelium and increased viscosity of meibum, resulting in lipid insufficiency and excessive evaporation and instability of the tear film<sup>[4]</sup>. Actually, omega-3 fatty acids affect dry eye syndrome related with MGD. For example, omega-3 fatty acids induce the change of lipid profile in the meibum, secretion and quality of the meibomian gland, and tear film stability in MGD<sup>[5-7]</sup>. Omega-3 plays an important role in modulating the inflammatory and immune responses in DED<sup>[8]</sup>. For example, omega-3 fatty acids block the synthesis of interleukin-1 and tumor necrosis factor-alpha associated with dry eye syndrome. However, omega-3 fatty acid is not enough supply by dietary food sources, and dietary supplement of omega-3 fatty acids can be supplied to improve DED symptoms.

While many previous studies reported controversial results as to whether dietary supplementation with omega-3 fatty acids can aid in the treatment of dry eye symptom<sup>[9-10]</sup>. The U.S Food and Drug Administration (FDA) has established an

**Table 1 Korean Corneal Disease Study Group guideline for the diagnosis of dry eye disease<sup>[13]</sup>**

Symptoms and signs <sup>a</sup>	Level I	Level II	Level III	Level IV
Ocular symptoms	Sometimes	Often	Always	Daily life limited
Visual symptoms	Sometimes	Often	Always	Daily life limited
Staining score <sup>b</sup>	<Grade I	Grade II	Grade III	>Grade IV
TBUT	Variable	6-10s	1-5s	Immediate
Schirmer-1	Variable	<5 to ≤10 mm	<2 to ≤5 mm	<2 mm

<sup>a</sup>Positive ocular signs may include conjunctival injection, lid abnormalities (blepharitis, trichiasis, keratinization, and symblepharon), and tear film abnormalities (debris, decreased tear meniscus, and mucus clumping). However, these findings are not considered in the grading of disease severity; <sup>b</sup>Oxford system.

acceptable daily intake of omega-3 is 3 g (3000 mg) per day under physician's supervision. Omega-3 fatty acids is mainly composed of two kinds of fatty acid such as eicosapentaenoic acid (EPA) or docosahexaenoic acid (DHA). EPA inhibits the production of prostaglandin, leukotriene, and thromboxane related to inflammatory reactions<sup>[11]</sup>. DHA which is the final metabolite of omega-3 organizes nerve tissue such as the brain and retina. Also, DHA acts as a storage molecule, so it can be shortened and re-saturated to produce EPA and the anti-inflammatory prostaglandins<sup>[12]</sup>. But recommended dietary allowance dosage for EPA and DHA is still not established, especially in DED. Although DHA influences the nerve tissue especially retina of eye, few products on the market contain higher doses DHA rather than EPA.

The purpose of this study is to investigate the efficacy of dietary supplementation with high dose DHA omega-3 for treating DED patients in 8wk intervention period.

## SUBJECTS AND METHODS

**Ethical Approval** A randomized, double-masked interventional study was performed at one referral eye center from December 2017 to September 2019. This trial was approved by the institutional review boards and the local ethics committee (IRB No.1711-002-060). Written informed consent was obtained from all the participating patients based on the Helsinki protocol. This study is registered with the Korean clinical research information service (KCT0005222).

**Patients** Over 18 years old adults, symptoms of DED with MGD patients were included in this study. Patients were checked dietary habits by questionnaire sheet whether high omega-3 food intake regularly or not. The diagnosis of DED was made based on the guideline proposed by the Korean Corneal Disease Study Group (KCDSG; Table 1)<sup>[13]</sup>.

And MGD was diagnosed by slit-lamp examination. The application of digital pressure to the 8 glands of the central third of the lower tarsus on a scale of 0 to 3: 0=clear, 1=cloudy, 2=cloudy with debris, and 3=thick like toothpaste (total score range 0-24). In this criterion, moderate MGD patients (score range 8-12) were included. And lid vascularity, plugging of gland orifices, lid margin irregularity and thickening were also

assessed to include this study<sup>[14]</sup>.

All patients have no history of having dietary omega-3 supplements from 3 months ago<sup>[15]</sup>. During the trial period, all participants have prescribed 0.5% carboxymethyl cellulose eye drops (Refresh plus<sup>®</sup>, Allergan, Dublin, Ireland) four times a day. However, patients were instructed not to use tear supplements, at least 2h before the examination.


Patients were excluded from this study if they met one of the following criteria: a history of diagnosed level IV DED by KCDSG guideline; allergic conjunctivitis, severe ocular infection, and inflammation; ocular surgery in 3mo; systemic (anti-anxiety, anti-histamine, anti-depressant) or topical medications that could affect tear film or meibomian gland function; severe MGD having anatomical changes; allergy to fluorescein<sup>®</sup>; using contact lens; and current pregnancy or breast feeding.

## Randomization, Masking, and Sample Size Calculation

To calculate sample size and compare the mean difference in dry eye symptoms between the omega-3 and placebo groups. Assuming 1:1 randomization, 80% power (alpha=0.05), and a precision error of 5%. The estimated sample size in each group was calculated to be 24 by the G power 3.1 programs. Figure 1 shows the patient flow-chart, randomization schedule, and follow-up protocol. Patients were randomly allocated to one of the two groups by a parallel assignment. High dose DHA omega-3 group received two capsules of Easyeye Dry<sup>®</sup> (Korea CNS pharm, Seoul, Korea), total containing 600 mg of EPA and 1640 mg of DHA, once a day for 8wk. The placebo group received 3000 mg of olive oil in two capsules, once a day for 8wk. The contents and types of capsules were masked for participant patients.

**Outcome Measures** All participants were examined by slit-lamp examination and dry eye testing at baseline, 4, and 8wk after omega-3 and placebo supplementation. At each visit, assessed MGD score, tear break-up time (TBUT), cornea staining (NEI score) of the ocular surface, tear secretion (SM Tube), and ocular symptoms evaluated by Ocular Surface Disease Index (OSDI).

The ocular surface was stained with 2 mL of 1% preservative-free fluorescein solution instilled into the conjunctival sac. The



**Figure 1** Flow diagram of this study for the therapeutic effect of dietary omega-3 supplement.

corneal staining was then assessed by fluorescein staining using the NEI score where the area of corneal staining was divided into five areas: superior, nasal, center, temporal, and inferior. The density of corneal staining was graded from 0, when no corneal staining was present, to 1 when corneal staining was sparse, 2 when it was moderately dense, and 3 when the corneal staining was high and the lesions overlapped<sup>[16]</sup>.

TBUT was the interval between the last complete blink and the first disturbance of the stained corneal tear film. Three measurements per subject were made both right and left side, then the average of the three values was taken as the mean value.

Under non-anesthetic conditions, the tip of the strip meniscometry tube (SM tube, Echo Electricity Co., Ltd., Fukushima, Japan) was immersed in the tear meniscus for 5s under a slit-lamp microscope. The examination was performed while taking care to avoid the test paper touching the ocular surface. The duration of measurement was strictly checked using a timer. The SM Tube value (in millimeters) was measured from the wet length of the test paper for 5s<sup>[17]</sup>.

The OSDI is one of the most frequently used methods to assess DED. In this study, Korean version OSDI questionnaire was used. The translated in the Korean version of OSDI tool reliability was Crohnhach's  $\alpha=0.94$ <sup>[18]</sup>. This questionnaire comprises 12 questions and evaluates the frequency of symptoms over the preceding week. The questionnaire requires approximately 5min for the patient to complete, and the scores range from 0 to 100. Based on the score, the patient's symptoms can be categorized as normal (0-12), mild dry eye (13-22), moderate dry eye (23-32), or severe dry eye (33-100)<sup>[19]</sup>.

**Statistical Analysis** Statistical analysis was performed using SPSS version 24.0 for Windows (SPSS statistics, IBM). A *t*-test or one-way analysis of variance (ANOVA) test was applied. The *t*-test was conducted to investigate the mean differences

between the two groups. An ANOVA test was conducted to determine whether there were significant changes in mean test values over the course of the 8wk of intervention. The *P*-value of less than 0.05 was considered statistically significant.

## RESULTS

Of the 50 included patients, 24 patients were randomized to the high dose DHA omega-3 group and 26 patients to the placebo group. Two patients were lost during the follow-up period. There were 44 females and 6 males were included. Total patients mean age was  $63.0\pm 7.7$ y, the mean age in high dose DHA omega-3 group was  $62.0\pm 7.0$ y, and  $63.8\pm 8.4$ y in the placebo group. As for baseline indices, there was no significant differences in mean age, sex, best corrected distant visual acuity (BCDVA), intraocular pressure (IOP), MGD score, TBUT, NEI score, SM Tube, and OSDI score between two groups (all  $P>0.05$ ; Table 2).

**Meibomian Gland Dysfunction Score** MGD score was only significantly reduced in omega-3 groups after treatment. In omega-3 group, the MGD score was  $8.7\pm 1.5$  at the baseline, and  $7.2\pm 1.8$  ( $P<0.001$ ) at 8wk after treatment. Regarding to placebo group, the MGD score was  $8.6\pm 1.4$  at the baseline, and  $8.1\pm 2.6$  ( $P=0.162$ ) after 8wk. There were no significant differences in MGD score between the two groups at baseline ( $P=0.783$ ). But after 8wk of treatment, the omega-3 group MGD score showed more significant improvement than the placebo group ( $P=0.033$ ; Figure 2).

**Tear Break-up Time** Mean baseline TBUT in both omega-3 and placebo groups improved significantly after treatment. In omega-3 group, the value of baseline TBUT was  $4.13\pm 0.85$ s. After 4 and 8wk, the value of TBUT were  $5.58\pm 1.21$  ( $P<0.001$ ) and  $6.00\pm 1.62$ s ( $P<0.001$ ). In the placebo group, the value of baseline TBUT was  $3.75\pm 0.79$ s. The value of TBUT were  $5.25\pm 1.29$ s ( $P<0.001$ ) at 4wk and  $5.08\pm 1.28$ s ( $P<0.001$ ) at 8wk after treatment. However, the value of TBUT at 8wk was

**Table 2 Characteristics of patients with dry eye**

Baseline characteristic	All (n=50)	Omega 3 (n=24)	Placebo (n=26)	P
Age (y, mean±SD)	63.0±7.7	62.0±7.0	63.8±8.4	0.403
Sex (male:female)	6:44	2:22	4:22	0.156
BCDVA (logMAR)	0.11±0.12	0.09±0.11	0.09±0.08	0.886
IOP (mm Hg)	15.3±2.3	15.7±1.6	14.8±2.9	0.186
MGD score	8.6±1.4	8.7±1.5	8.6±1.4	0.745
TBUT (s)	3.96±0.83	4.13±0.85	3.75±0.79	0.181
NEI score	3.7±2.9	4.0±3.5	3.5±2.4	0.484
SM Tube (mm)	3.0±1.4	3.2±1.4	2.8±1.5	0.335
OSDI score	27.1±3.8	26.8±3.8	27.0±4.0	0.720

SD: Standard deviation; BCDVA: Best corrected distant visual acuity; IOP: Intraocular pressure; MGD: Meibomian gland dysfunction; TBUT: Tear break up time, NEI: National Eye Institute/Industry; SM: Strip meniscometry; OSDI: Ocular Surface Disease Index.

improved significantly higher in the omega-3 group, compared to the placebo group ( $P=0.034$ ; Figure 3).

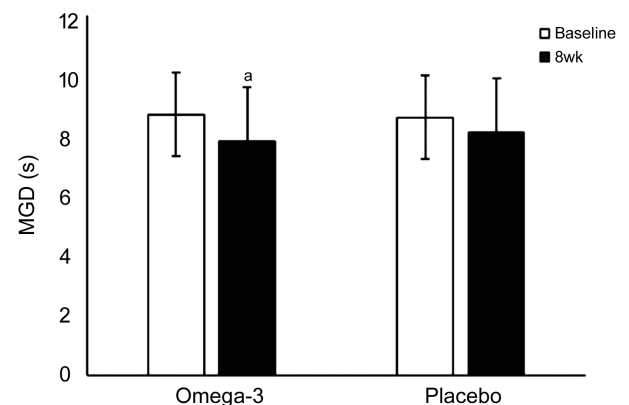
**Cornea Staining** NEI score was significantly reduced in both groups after treatment. In omega-3 group, the average NEI score was  $4.0\pm3.5$  at baseline,  $2.5\pm2.1$  ( $P=0.013$ ) at 4wk, and  $1.4\pm1.4$  ( $P<0.001$ ) at 8wk. As for the placebo group, the average NEI score was  $3.5\pm2.4$  at the baseline,  $3.0\pm2.4$  ( $P=0.030$ ) at 4wk, and  $1.9\pm1.5$  ( $P<0.001$ ) at 8wk. However, there were no significant differences in vital staining between two groups at 4 and 8wk after treatment (Figure 4).

**SM Tube Test** The mean value of the baseline SM tube in omega-3 group was  $3.2\pm1.1$  mm, which changed insignificantly reduced after treatment. The value of SM tube was  $2.8\pm1.1$  mm ( $P=0.071$ ) at 4wk and  $2.9\pm1.5$  mm in 8wk ( $P=0.518$ ). The mean value of the baseline SM tube in the placebo group was  $2.8\pm1.5$  mm, which changed insignificantly improved after treatment. The value of SM tube was  $2.9\pm0.5$  mm ( $P=0.811$ ) in 4wk and  $3.1\pm1.1$  mm in 8wk ( $P=0.319$ ). There were no differences in the SM tube between the omega-3 and placebo groups at 4 and 8wk (Figure 5).

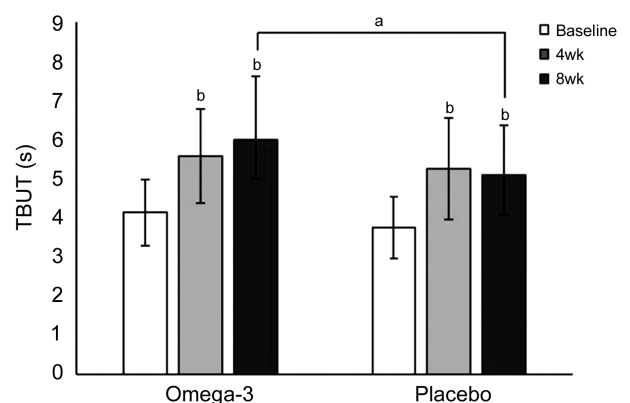
**OSDI Score** OSDI score was also significantly reduced in both groups after treatment. In omega-3 group, the value of OSDI score was  $26.8\pm3.8$  at the baseline,  $24.2\pm4.2$  ( $P<0.001$ ) at 4wk, and  $24.3\pm4.2$  ( $P<0.001$ ) at 8wk after treatment. Regarding to Placebo group, the value of OSDI score was  $27.0\pm4.0$  at the baseline,  $25.5\pm4.1$  ( $P<0.001$ ) at 4wk, and  $25.0\pm4.0$  ( $P<0.001$ ) after 8wk. There were no significant differences in OSDI score between the two groups at 4 and 8wk after treatment (Figure 6).

## DISCUSSION

It is known that DED can be aggravated by MGD. This study was conducted to evaluate the treatment effect of high dose omega-3 dietary supplementation in DED patients with MGD. Recently, the composition of omega-3/omega-6 ratio in serum is increased due to changing a dietary habit in Korea. High serum omega-6 level triggers the pro-inflammatory

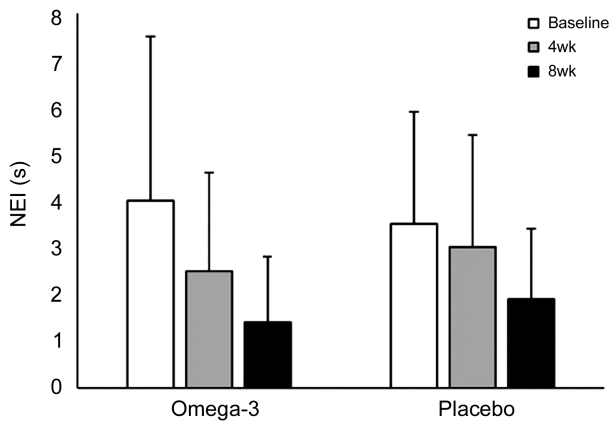


**Figure 2 The outcomes of MGD score after omega-3 and placebo supplementation** The MGD score of omega-3 group significantly improved at 8wk after treatment ( $^aP=0.033$ ).

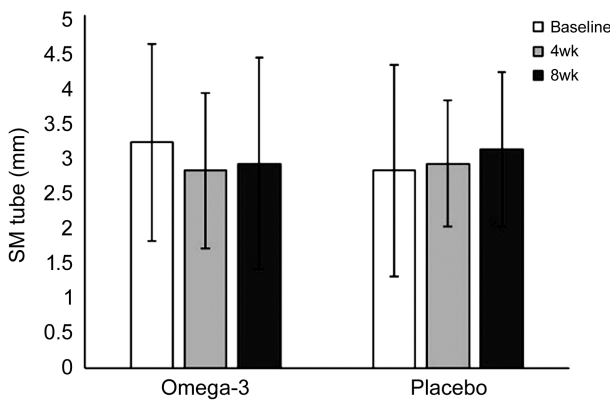


**Figure 3 The outcomes of TBUT after omega-3 and placebo supplementation** The value of TBUT of omega-3 group significantly improved at 4 and 8wk after treatment, compared to that of control group at baseline of pre-treatment on both groups (compared  $t$ -test  $^bP<0.001$  in all groups). Especially, the value of TBUT in omega-3 group was significantly more improved than that of control group at 8wk (one-way analysis of variance,  $^aP=0.034$ ).

status which could worsen symptoms in DED and MGD. Although oral supplementation of omega-3 could benefit to reduce inflammatory reaction, the direct mechanism of dietary

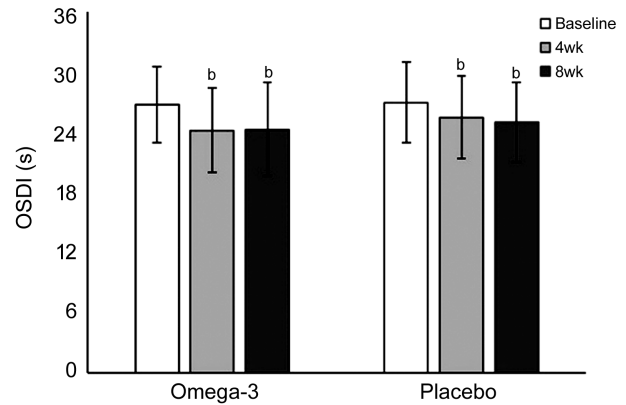


**Figure 4 The outcomes of NEI score after omega-3 and placebo supplementation** The values of NEI score of omega-3 group and control significantly improved at 4 and 8wk, compared to that of baseline between pre-and post-treatment (compared *t*-test  $P=0.013$ ,  $P<0.001$ ,  $P=0.030$ ,  $P<0.001$  respectively). The value of NEI score in omega-3 group was not significantly more improved than that of control group at baseline, at 4 and 8wk (one-way analysis of variance,  $P=0.034$ ).



**Figure 5 The outcomes of strip meniscometry tube (SM tube) after omega-3 and placebo supplementation** There was not significantly difference of improvement in values of SM tube in the omega-3 and control group at 4 and 8wk after treatment, compared to that of baseline on both groups. The values of SM tube between Omega-3 and control group were not significantly improved at baseline, 4, and 8wk (compared *t*-test  $P=0.071$ , 0.518, 0.811, 0.319).

omega-3 supplementation in DED treatment is not fully understood. Although there was controversy in the therapeutic effect by omega-3 supplement, but many previous studies report dietary omega-3 supplement is effective in DED<sup>[10-11,20-21]</sup>. Dietary omega-3 fatty acid supplementation could help significantly reduced ocular surface inflammation in DED<sup>[22]</sup>, because it has strong anti-inflammatory effects on human corneal epithelium and modulating the corneal nerve regeneration related with the ocular pain relief<sup>[23]</sup>. However, there is controversy about the treatment effect of omega-3 fatty acids on dry eyes so far. In the report of the Dream Study Research Group (DSRG), omega-3 dietary supplementation



**Figure 6 The outcomes of OSDI score after omega-3 and placebo supplementation** The values of OSDI score in the omega-3 and control group were significantly improved at 4 and 8wk, compared to that of baseline between pre-and post-treatment (compared *t*-test  $P<0.001$  in all groups). The values of OSDI score between Omega-3 and control group were not significantly improved at baseline, 4, and 8wk (compared *t*-test  $P=0.071$ , 0.518, 0.811, 0.319).

therapy administered to 394 patients with moderate to severe DED had no significant therapeutic effect compared to the placebo group<sup>[9]</sup>. By our study, there was no difference in the secretion of tear, corneal staining, and OSDI between dietary omega-3 supplement and placebo. These findings are consistent with dietary Omega-3 supplement doesn't improve dry eye syndrome. On the other hand, in a meta-analysis report of 17 randomized controlled trial studies involving a total of 3363 patients<sup>[10]</sup>, oral supplementation of omega-3 improved ocular symptoms of DED, TBUT, tear secretion, and cornea NEI score in dry eye.

Regarding to dry eye with MGD, the therapeutic effect of omega-3 supplementation was more affect in patients with MGD or blepharitis than the aqueous deficiency dry eye<sup>[24]</sup>. Dietary supplementation of omega-3 in MGD may affect the stability of tear film, included secretion and quality of meibum<sup>[25]</sup>. High dose DHA omega-3 supplement could be an important treatment because it can increase meibomian gland secretions and quality, enhanced tear film stability in meibomian gland dysfunction<sup>[6-7,9]</sup>. In additional, saturated fatty acids such as DHA may potentially lower the melting point of meibomian lipids, thereby increasing fluidity and secretion<sup>[26]</sup>. In these 17 Meta-analyses, which analyzed the therapeutic effect when dietary supplement in MGD patients with omega-3 moderate dose, showed a significant therapeutic effect compared to the placebo group. Compared with DSRG study, the prevalence of dry eye associated with MGD is just 6.4% of subjects, so the therapeutic effect of omega-3 dietary supplement is not clear in dry eye with MGD<sup>[9]</sup>. Our study also showed markedly the improvement of MGD score and TBUT in omega-3 treatment group contained with high dose DHA in

MGD. This means that high dose omega-3 supplementation contained with high dosage of DHA affect additional therapeutic effect in MGD. More clinical study is needed based on many dry eyes with MGD for evaluation of additional therapeutic effects in MGD by dietary omega-3 supplement contained with high dose of DHA. Further multi-center clinical trial would be helpful to confirm its long-term efficacy and safety.

Regarding to the duration of dietary omega-3 supplement, some studies generally required the duration of omega-3 supplement use ranged from 6wk to 12mo<sup>[10]</sup>. Short-Term omega-3 Fatty Acids Treatment for Dry Eye, using high-dose dietary omega-3 (2400 mg/d) treatment elicit a significant improvement in dry eye symptoms within 1mo<sup>[27]</sup>. The duration of dietary omega-3 supplements of our clinical study required at least 2mo, because the longer the duration of oral supplement, the more frequent the side effects. It is known that the following adverse events can occur when consuming dietary omega-3; gastrointestinal disturbance (nausea, diarrhea, or epigastric discomfort), skin abnormality (eruption, itching, exanthema, or eczema), hemorrhage (cerebral, fundal, epistaxis, and subcutaneous)<sup>[28]</sup>. In the 50 patients included in our study, no patients fortunately complained of side effects during 8wk.

The limitations of this trial, being its small sample size ( $n=50$ ) and undertaking at a single site. The lipid profiles of patients at baseline and final visit were not evaluated. Furthermore, although the amount of omega-3 supplement generally supplied as food is small, patients' dietary habitats were not completely controlled. For example, in a study of 13 797 Koreans, the average daily dietary intake of DHA was 166.95 mg and EPA was 96.99 mg, which was very low compared to the average recommended amount<sup>[29]</sup>. Further investigation of the therapeutic potential of high dose DHA omega-3 for treating DED concerned with MGD is needed.

In conclusion, the eight weeks treatment of high dose DHA omega-3 and placebo supplementation improving the signs and symptoms of DED with MGD and NEI score. High dose omega-3 supplementation shows a beneficial therapeutic effect relative to placebo for MGD and TBUT after eight weeks of treatment. Our findings suggest that when adjunctive taking high dose DHA omega-3 dietary supplements for more 8wk, it could be obtained additional therapeutic effect in TBUT and MGD by improving tear film stability and meibomian gland function.

#### ACKNOWLEDGEMENTS

**Conflicts of Interest:** Jo YJ, None; Lee JS, None.

#### REFERENCES

1 Ahn JM, Lee SH, Rim TH, Park RJ, Yang HS, Kim TI, Yoon KC, Seo KY, Epidemiologic Survey Committee of the Korean Ophthalmological Society. Prevalence of and risk factors associated with dry eye: the

Korea National Health and Nutrition Examination Survey 2010-2011. *Am J Ophthalmol* 2014;158(6):1205-1214.e7.

- 2 The definition and classification of dry eye disease: report of the Definition and Classification Subcommittee of the International Dry Eye WorkShop (2007). *Ocul Surf* 2007;5(2):75-92.
- 3 Craig JP, Nichols KK, Akpek EK, Caffery B, Dua HS, Joo CK, Liu Z, Nelson JD, Nichols JJ, Tsubota K, Stapleton F. TFOS DEWS II definition and classification report. *Ocul Surf* 2017;15(3):276-283.
- 4 Malhotra C, Singh S, Chakma P, Jain AK. Effect of oral omega-3 fatty acid supplementation on contrast sensitivity in patients with moderate meibomian gland dysfunction: a prospective placebo-controlled study. *Cornea* 2015;34(6):637-643.
- 5 Walter SD, Gronert K, McClellan AL, Levitt RC, Sarantopoulos KD, Galor A.  $\omega$ -3 tear film lipids correlate with clinical measures of dry eye. *Invest Ophthalmol Vis Sci* 2016;57(6):2472-2478.
- 6 Kangari H, Eftekhari MH, Sardari S, Hashemi H, Salamzadeh J, Ghassemi-Broumand M, Khabazkhoob M. Short-term consumption of oral omega-3 and dry eye syndrome. *Ophthalmology* 2013;120(11):2191-2196.
- 7 Oleňik A, Mahillo-Fernández I, Alejandre-Alba N, Fernández-Sanz G, Pérez MA, Luxan S, Quintana S, Martínez de Carneros Llorente A, García-Sandoval B, Jiménez-Alfaro I. Benefits of omega-3 fatty acid dietary supplementation on health-related quality of life in patients with meibomian gland dysfunction. *Clin Ophthalmol* 2014;8:831-836.
- 8 Calder PC, Grimble RF. Polyunsaturated fatty acids, inflammation and immunity. *Eur J Clin Nutr* 2002;56(Suppl 3):S14-S19.
- 9 Dry Eye Assessment and Management Study Research Group, Asbell PA, Maguire MG, Pistilli M, Ying GS, Szcotka-Flynn LB, Hardten DR, Lin MC, Shtein RM. n-3 fatty acid supplementation for the treatment of dry eye disease. *N Engl J Med* 2018;378(18):1681-1690.
- 10 Giannaccare G, Pellegrini M, Sebastiani S, Bernabei F, Roda M, Taroni L, Versura P, Campos EC. Efficacy of omega-3 fatty acid supplementation for treatment of dry eye disease: a meta-analysis of randomized clinical trials. *Cornea* 2019;38(5):565-573.
- 11 James MJ, Gibson RA, Cleland LG. Dietary polyunsaturated fatty acids and inflammatory mediator production. *Am J Clin Nutr* 2000;71(1 suppl):343S-348S.
- 12 Das UN. Essential fatty acids and their metabolites could function as endogenous HMG-CoA reductase and ACE enzyme inhibitors, anti-arrhythmic, anti-hypertensive, anti-atherosclerotic, anti-inflammatory, cytoprotective, and cardioprotective molecules. *Lipids Health Dis* 2008;7:37.
- 13 Hyon JY, Kim HM, Lee D, Chung ES, Song JS, Choi CY, Lee J, Korean Corneal Disease Study Group. Korean guidelines for the diagnosis and management of dry eye: development and validation of clinical efficacy. *Korean J Ophthalmol* 2014;28(3):197-206.
- 14 Arita R, Minoura I, Morishige N, Shirakawa R, Fukuoka S, Asai K, Goto T, Imanaka T, Nakamura M. Development of definitive and reliable grading scales for meibomian gland dysfunction. *Am J Ophthalmol* 2016;169:125-137.

- 15 Bowman G, Silbert L, Dodge H, Lahna D, Hagen K, Murchison C, Howieson D, Kaye J, Quinn J, Shinto L. Randomized trial of marine n-3 polyunsaturated fatty acids for the prevention of cerebral small vessel disease and inflammation in aging (PUFA trial):rationale, design and baseline results. *Nutrients* 2019;11(4):735.
- 16 Lemp MA. Report of the national eye institute/industry workshop on clinical trials in dry eyes. *Clao J* 1995;21(4):221-232.
- 17 Singh A, Vanathi M, Kishore A, Gupta N, Tandon R. Evaluation of strip meniscometry, tear meniscus height and depth in the diagnosis of dry eye disease in Asian Indian eyes. *Ocul Surf* 2019;17(4): 747-752.
- 18 Han SH, Kim EY. Prevalence of dry eye disease its affecting factors by using OSDI questionnaire. *J Korea Acad Ind Coop Soc* 2016;17(10):93-103.
- 19 Schiffman RM, Christianson MD, Jacobsen G, Hirsch JD, Reis BL. Reliability and validity of the ocular surface disease index. *Arch Ophthalmol* 2000;118(5):615-621.
- 20 Bhargava R, Kumar P, Kumar M, Mehra N, Mishra A. A randomized controlled trial of omega-3 fatty acids in dry eye syndrome. *Int J Ophthalmol* 2013;6(6):811-816.
- 21 Wojtowicz JC, Butovich I, Uchiyama E, Aronowicz J, Agee S, McCulley JP. Pilot, prospective, randomized, double-masked, placebo-controlled clinical trial of an omega-3 supplement for dry eye. *Cornea* 2011;30(3):308-314.
- 22 Epitropoulos AT, Donnenfeld ED, Shah ZA, Holland EJ, Gross M, Faulkner WJ, Matossian C, Lane SS, Toyos M, Bucci FA, Perry HD. Effect of oral re-esterified omega-3 nutritional supplementation on dry eyes. *Cornea* 2016;35(9):1185-1191.
- 23 Gao Y, Su J, Zhang Y, Chan A, Sin JH, Wu D, Min K, Gronert K. Dietary DHA amplifies LXA4 circuits in tissues and lymph node PMN and is protective in immune-driven dry eye disease. *Mucosal Immunol* 2018;11(6):1674-1683.
- 24 Al-Namaeh M. A systematic review of the effect of omega-3 supplements on meibomian gland dysfunction. *Ther Adv Ophthalmol* 2020;12:2515841420952188.
- 25 Ziemanski JF, Wolters LR, Jones-Jordan L, Nichols JJ, Nichols KK. Relation between dietary essential fatty acid intake and dry eye disease and meibomian gland dysfunction in postmenopausal women. *Am J Ophthalmol* 2018;189:29-40.
- 26 Harauma A, Saito J, Watanabe Y, Moriguchi T. Potential for daily supplementation of n-3 fatty acids to reverse symptoms of dry eye in mice. *Prostaglandins Leukot Essent Fatty Acids* 2014;90(6):207-213.
- 27 Bhargava R, Kumar P, Arora Y. Short-term omega 3 fatty acids treatment for dry eye in young and middle-aged visual display terminal users. *Eye Contact Lens* 2016;42(4):231-236.
- 28 Brinton EA, Mason RP. Prescription omega-3 fatty acid products containing highly purified eicosapentaenoic acid (EPA). *Lipids Health Dis* 2017;16(1):23.
- 29 Ha AW, Kim WK. Intake ratio and major food sources of n-3 and n-6 fatty acids in Korea: a study based on the sixth Korea national health and nutrition examination survey (2013-2014). *Asia Pac J Clin Nutr* 2018;27(2):433-440.