

Ophthalmic manifestations of *Cryptococcus gattii* species complex: a case series and review of the literature

Grace A. McCabe¹, Jack W. McHugh², Todd Goodwin^{3,4}, Douglas F. Johnson⁵, Anthony Fok⁶, Thomas G. Campbell^{1,4,7,8}

¹Department of Ophthalmology, the Royal Melbourne Hospital, Melbourne, Victoria 3050, Australia

²Department of Internal Medicine, Mayo Clinic, Rochester, Minnesota 55902, USA

³James Cook University, Townsville, Queensland 4811, Australia

⁴NQ Eye Foundation, Townsville, Queensland 4811, Australia

⁵Department of Infectious Disease, the Royal Melbourne Hospital, Melbourne, Victoria 3050, Australia

⁶Department of Neurology, the Royal Melbourne Hospital, Melbourne, Victoria 3050, Australia

⁷Centre for Eye Research Australia, East Melbourne, Victoria 3002, Australia

⁸Ophthalmology, Department of Surgery, the University of Melbourne, Melbourne, Victoria 3010, Australia

Correspondence to: Thomas G. Campbell. Centre for Eye Research Australia, East Melbourne, Victoria 3002, Australia. research@drthomascampbell.com

Received: 2020-10-29 Accepted: 2021-06-25

Abstract

• **AIM:** To report 4 cases of *Cryptococcus gattii* (*C. gattii*) species complex infection with diverse ophthalmic manifestations, and to review the literature to examine pathobiology of disease, classical ophthalmic presentations and outcomes, and treatment modalities for this emerging pathogen.

• **METHODS:** Cases of *C. gattii* meningoencephalitis with ophthalmic manifestations were identified via chart review at two institutions in Australia and one institution in the mid-west region of the United States and are reported as a case series. Additionally, a MEDLINE literature review was conducted to identify all reported cases of *C. gattii* with ophthalmic manifestations from 1990-2020. Cases were reviewed and tabulated, together with our series of patients, in this report.

• **RESULTS:** Four cases of *C. gattii* with ophthalmic manifestations are presented; three from Australia and one from the USA. A literature review identified a total of 331 cases of *C. gattii* with visual sequelae. The majority of

cases occurred in immunocompetent individuals. Blurred vision and diplopia were the most common presenting symptoms, with papilloedema the most common sign, reported in 10%-50% of cases. Visual loss was reported in 10%-53% of cases, as compared to rates of visual loss of 1%-9% in *C. neoformans* infection. Elevated intracranial pressure, cerebrospinal fluid (CSF) fungal burden, and abnormal neurological exam at presentation correlated with poor visual outcomes. The mainstays of treatment are anti-fungal agents and aggressive management of intracranial hypertension with serial lumbar punctures. CSF diversion procedures should be considered for refractory cases. Acetazolamide and mannitol are associated with high complication rates, and adjuvant corticosteroids have demonstrated higher mortality rates; these treatments should be avoided.

• **CONCLUSION:** Permanent visual loss represents a devastating yet potentially preventable sequelae of *C. gattii* infection. Intracranial hypertension needs to be recognised early and aggressively managed. Referral to an ophthalmologist/neuro-ophthalmologist in all cases of cryptococcal infection independent of visual symptoms at time of diagnosis is recommended.

• **KEYWORDS:** *Cryptococcus*; *Cryptococcus gattii*; cryptococcosis; ophthalmic manifestation

DOI:10.18240/ijo.2022.01.18

Citation: McCabe GA, McHugh JW, Goodwin T, Johnson DF, Fok A, Campbell TG. Ophthalmic manifestations of *Cryptococcus gattii* species complex: a case series and review of the literature. *Int J Ophthalmol* 2022;15(1):119-127

INTRODUCTION

The *Cryptococcus* complex species are spore-forming, soil-dwelling fungi. *Cryptococcus gattii* (*C. gattii*) was historically considered a variety of *Cryptococcus neoformans* (*C. neoformans*). Increased recognition of unique epidemiological, morphological, and clinical features led to its designation as an independent species in 2002^[1-2]. Genotyping identified at least four molecular types or genotypes of *C. gattii* (variety

gattii; VG), VGI, VGII, VGIII, and VGIV, with each of these genotypes containing subtypes^[1]. Based on phylogenetic analysis of genetic loci and genotyping studies Hagen *et al*^[2] demonstrated significant genetic diversity and proposed *C. neoformans* be divided into two species and *C. gattii* into five species. Subsequent published genotypes have revealed greater genetic diversity than is encompassed by the seven species. In an effort to recognise genetic diversity without creating confusion Kwon-Chung *et al*^[3] proposed the use of “*C. gattii* species complex” as a practical solution, rather than creating more species^[3]. In this manuscript when “*C. gattii*” is used it refers to the “*C. gattii* species complex”.

Though *C. gattii* has long been established as a cause of endemic infection in the sub-tropics and in Australia^[4-5], an outbreak in Vancouver Island in 1999 led to spread of *C. gattii* into the Pacific Northwest region of the United States^[6], with further reports described elsewhere in the United States and in Europe in more recent years^[7-8]. It appears genotype distribution and frequency are dependent on geographic regions. In Australia VGI is the most common genotype of isolates whereas isolates from the outbreak in Canada and the Pacific Northwest region of the United States were the molecular type VGII^[6].

Infections caused by *C. neoformans* have classically been associated with immunosuppressed individuals, most frequently HIV/AIDS patients. In contrast, *C. gattii* infections have predominantly been documented in healthy and immunocompetent patients^[5,9]. The majority of patients present with central nervous system (CNS) infection, with concurrent or isolated pulmonary infection also common^[10].

A notable observation of *C. gattii* CNS infection is the high rate of visual sequelae, particularly when compared to infections caused by *C. neoformans*^[1]. We present cases from multiple centres that illustrate the diverse ophthalmic manifestations of *C. gattii*. We will also review the literature to evaluate ophthalmic manifestations of *C. gattii* infection, prognosticators of visual outcome, and treatment modalities. To our knowledge this is the first study that has specifically examined ophthalmic manifestations of *C. gattii* infection.

SUBJECTS AND METHODS

Ethical Approval Approval for the study was obtained *via* the Institutional Review Boards at the Royal Melbourne Hospital and at Mayo Clinic respectively. All research activities were in accordance with the Declaration of Helsinki.

Four cases of *C. gattii* were independently identified, including cases from Victoria and Queensland, Australia, and the mid-west region of the United States. The ocular and systemic characteristics, treatment, and visual outcomes are reported. A MEDLINE literature search (1990 through 2020) was performed to identify cases of *C. gattii* meningoencephalitis

where ophthalmic manifestations were reported. All reported cases were reviewed and tabulated, together with our series of patients, in this report.

RESULTS

Patient 1 *C. gattii* in an Immunocompetent Individual A 20-year-old healthy female presented to a tertiary hospital with a 2-month history of frontal headache, night sweats, and blurred vision. Neurological examination was notable for significant nuchal rigidity, visual acuity (VA) was 6/9 right eye and 6/9 left eye, with normal colour vision and no relative afferent pupillary defect (RAPD). Ophthalmoscopy showed bilateral optic nerve swelling (Figure 1). She had not travelled rurally.

Magnetic resonance imaging (MRI) brain showed T1 ring-enhancing lesion (Figure 2A) and computed tomography (CT) chest showed cavitating lesions in both lungs (Figure 2B). Lumbar puncture (LP) revealed a normal opening pressure (OP), with analysis of cerebrospinal fluid (CSF) demonstrating lymphocytic pleocytosis and Cryptococcal antigen (Crag) titre >1:2560. CSF culture grew *C. gattii* which was subtyped to *C. gattii* VGI using matrix-assisted laser desorption/ionization coupled to time-of-flight spectrometry (MALDI-TOF). Liposomal amphotericin B and flucytosine were initiated. HIV testing was negative.

One week post-initiation of therapy headache continued. Repeat LP revealed an OP of 32 cm H₂O CSF. Ophthalmic assessment demonstrated dyschromatopsia, right RAPD and worsening of optic disc swelling consistent with grade 5 papilloedema. Repeat MRI brain showed hydrocephalus. She had daily LP until day 20 of admission, when a ventriculo-peritoneal (VP) shunt was inserted, resulting in immediate symptomatic improvement. She completed a 6-week induction course of liposomal amphotericin B and flucytosine infusions, followed by a 12mo course of fluconazole to complete consolidation and maintenance therapy. At follow-up 4-months post-discharge her visual acuity was 6/5 in both eyes, with grade 3 papilloedema, and lipid deposits present at the left parafoveal area (Figure 3).

Patient 2 Severe *C. gattii* Meningoencephalitis Following Renal Transplantation A 61-year-old male presented to an Emergency Department in the mid-west region of the United States, with a 6-month history of headache, vomiting, and 5 kg weight loss. He was immunosuppressed with tacrolimus 2 mg BID, prednisone 10 mg OD, mycophenolate mofetil 250 mg BID following renal transplantation two years prior. The source of infection was not clear. Donor derived transmission of *Cryptococcus* has previously been described, however this patient had travelled to *Cryptococcal* endemic regions in the north-western United States^[1,11]. Examination was notable for skin lesions on left forearm (Figure 4A). LP was obtained;

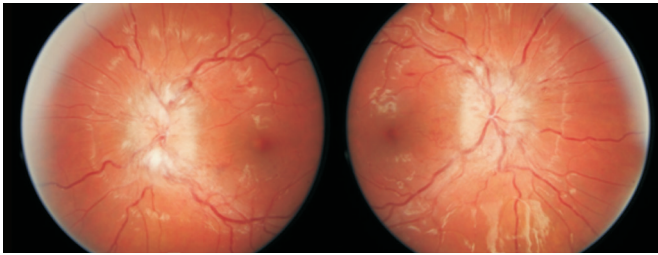


Figure 1 Bilateral Frisen grade 4 papilloedema.

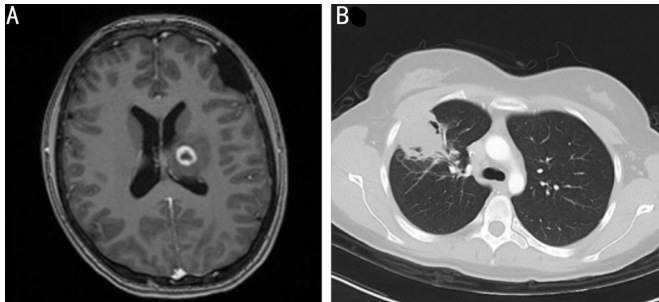


Figure 2 Cross sectional imaging A: Axial T1 MRI of the brain demonstrating a ring enhancing lesion with local mass effect in the left thalamus; B: Axial CT of the chest demonstrating a cavitation lesion of the right middle lobe.

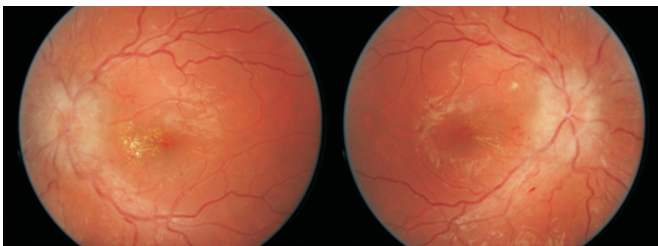


Figure 3 Bilateral Frisen grade 3 papilloedema with partial macular stars of lipid deposit.

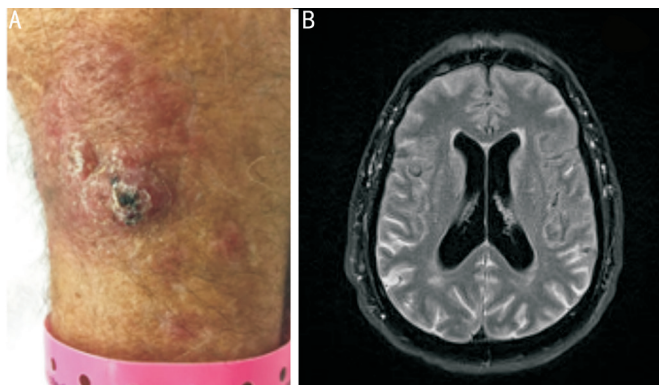


Figure 4 Skin and CNS manifestations A: Cutaneous cryptococcosis with nodules, maculopapules, and ulceration; B: Axial FLAIR MRI demonstrating diffuse lepto-meningeal enhancement and hydrocephalus.

OP was 50 cm H₂O CSF. CSF fungal smear demonstrated yeast. Amphotericin B and flucytosine were initiated and his immunosuppressive regimen was tapered.

Fungal cultures of CSF and Grocott's Methenamine Silver Stain (GMS) staining of skin lesions subsequently demonstrated *C. gattii*. The patient had severe headaches with persistent

elevation of intracranial pressure (ICP) on serial LPs requiring lumbar drain insertion on hospital day 4. On day 5 the patient developed reduced right VA. VA was counting fingers right eye and 6/15⁻² left eye. Fundusoscopic examination demonstrated bilateral optic nerve oedema. He had limitation of abduction consistent with mild 6th nerve palsy in both eyes. MRI brain and orbits revealed generalized mild hydrocephalus and abnormal leptomeningeal enhancement (Figure 4B). Prednisone was switched to dexamethasone for management of optic nerve oedema. Unfortunately, the patient continued to experience profound elevation of ICP with associated encephalopathy despite placement of a VP shunt. A decision was made to pursue hospice cares and the patient died 30d following initial presentation.

Patient 3 Retinal Cryptococcomas in an Immunocompetent Individual A 41-year old previously well male presented to an Emergency Department in Queensland with a 4-week history of worsening headaches and fever. LP was performed and revealed normal OP with CSF Crag titre of >1:1280 with subsequent culture positive for *C. gattii*. CT brain was unremarkable and CT chest demonstrated a pulmonary cryptococcoma in the left lower lobe.

The patient had no visual symptoms but was referred to the ophthalmologist for routine review, with initial VA of 6/4.5 in both eyes. Dilated slit lamp examination was notable for a retinal lesion temporal to the fovea of the left eye, with intra-retinal oedema. Infrared imaging and optical coherence tomography (OCT) and demonstrated a cryptococcoma (Figure 5A, 5B). The optic nerves were normal.

He was treated with amphotericin B and flucytosine infusions. Daily fundusoscopic examinations showed the retinal lesion reducing in size. After 3wk of inpatient care, he was discharged home after 3wk on oral fluconazole.

The patient returned to the emergency department 5d post discharge with worsening headaches. Repeat MRI demonstrated multiple cerebral cryptococcomas. He was re-commenced on amphotericin B and flucytosine infusions and oral fluconazole. The retinal cryptococcoma continued to reduce in size, however the patient developed optic nerve head swelling that continued to worsen on subsequent reviews despite several LPs demonstrating OPs of no higher than 25 cm H₂O of CSF. He was re-commenced on amphotericin B and flucytosine infusions for 6wk.

Six weeks later, repeat LP had a normal OP of 19 cm H₂O CSF, and optic nerve swelling continued to reduce. Repeat infrared imaging and OCT at 4 and 7mo respectively demonstrated improving retinal thickening over the retinal cryptococcoma (Figure 5C, 5D). He was again discharged on oral fluconazole planned for a 12mo course. VA remained stable at 6/4.5 in both eyes.

Patient 4 Immunocompetent with Persistent Intracranial Hypertension

An independent 58-year-old female from rural Victoria, Australia presented to the local Emergency Department with a cough and lethargy. She had hypertension, obstructive sleep apnoea and migraine.

Treatment for community acquired pneumonia was initiated, however 6wk later she returned to the Emergency Department with headaches and confusion associated with photophobia, phonophobia and visual disturbance. Bronchoalveolar lavage with cultures confirmed *C. gattii* infection. MRI brain demonstrated a well circumscribed lesion of the right temporal lobe (Figure 6A). Flucytosine and amphotericin B were prescribed for a 6wk course, followed by consolidation with oral fluconazole. Weekly LPs were performed for chronic headache, with recorded OPs of 26-36 cm H₂O CSF.

Four months following diagnosis she was transferred to our tertiary centre with ongoing postural headaches associated with photophobia, blurred vision, scintillations and new papilloedema. On ophthalmic examination, VA was 6/12 right eye and 6/7.5 left eye. Fundal examination demonstrated grade 2 papilloedema of both eyes (Figure 7). Repeat imaging showed multiple enlarging ring enhancing cryptococcomas with substantial progression of vasogenic oedema in the right supratentorial brain parenchyma (Figure 6B). VP shunt was inserted with improvement in symptoms.

At 1-year follow up, headaches and papilloedema had resolved, however there was further deterioration in VA; 6/12 right eye and 6/15 left eye. Repeat MRI brain demonstrated reduction in size in two of the four cryptococcal lesions. Maintenance therapy with fluconazole was continued for a planned 18mo course.

DISCUSSION

The 4 cases presented here, allied with a review of the existing literature, illustrate a number of important principles related to infection with *C. gattii*. The first of these is the broad geographical distribution. While previously thought to be a disease of the tropics and sub-tropics, *C. gattii* is now recognized as an endemic fungus in the United States, most prevalent in the North-western regions of the country. Host factors also appear to differ significantly when compared to *C. neoformans*, with infection with *C. gattii* observed more frequently in immunocompetent hosts.

The second of these is that *C. gattii* is associated with significant visual sequelae, in particular when associated with intracranial hypertension. While papilloedema is strongly associated with vision loss, it is not present in all cases, and prompt recognition and management of intracranial hypertension with decompressive therapies is critical. Unlike in idiopathic intracranial hypertension, acetazolamide and mannitol are associated with adverse side effects and poor outcomes.

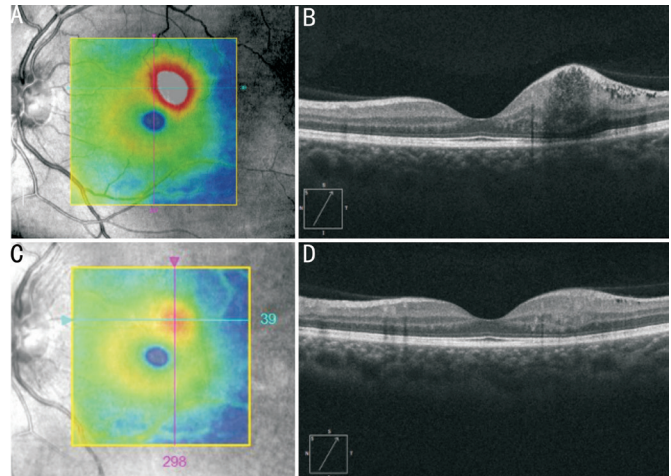


Figure 5 Cryptococcoma imaging A: En face infrared imaging of the left eye demonstrating retinal thickening (colour coded as white and red) corresponding to the retinal cryptococcoma superotemporal to the fovea (blue circle); B: OCT of the left retina demonstrating a round, well circumscribed retinal cryptococcoma; C: Four months follow-up demonstrating improving retinal thickening over the retinal cryptococcoma; D: Seven months follow-up demonstrating diminution of the retinal cryptococcoma.

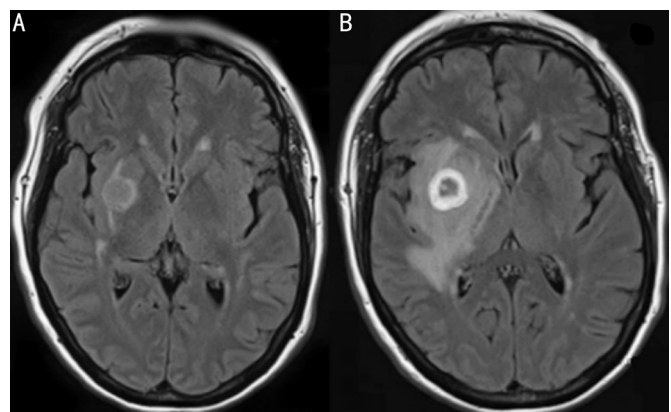


Figure 6 Axial MRI brain imaging A: Circumscribed lesion of the right temporal lobe; B: Ring enhancing lesion with marked surrounding vasogenic oedema at 4mo follow-up.

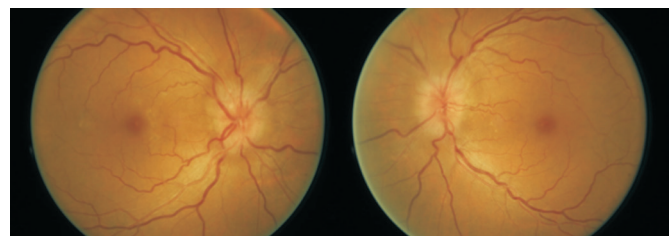


Figure 7 Colour fundus photographs demonstrating bilateral Frisen grade 2 papilloedema.

Third, these cases highlight the protean ophthalmic and systemic manifestations possible in *C. gattii* infection. Our cases demonstrate that *C. gattii* infections can cause myriad ophthalmic pathologies including vision loss, papilloedema, and retinal cryptococcomas. While the phenomena of

endophthalmitis and retinal cryptococcomas secondary to *C. gattii* have been documented only rarely in the literature, their possibility warrants dilated fundoscopic examination. We recommend that all patients diagnosed with *C. gattii* meningitis be referred to an ophthalmologist/neuro-ophthalmologist at presentation and receive long-term follow up during their treatment course to assess for ophthalmic sequelae. Whilst the literature is relatively sparse in this area, there is a suggestion that *C. gattii* is associated with worse visual outcomes than *C. neoformans*. Whether this is related to differential rates of fungal blockage of CSF, an as yet unidentified mechanism, or a spurious finding, requires further elucidation. Further studies that directly compare the mean ICP and ophthalmic manifestations of *C. neoformans* and *C. gattii* would contribute significantly to the literature in this area.

Epidemiology *C. gattii* was thought to be a rare pathogen endemic to the sub-tropics and Australia. Increased laboratory capabilities enabling genotyping of cryptococcal species, with subsequent documentation of cases in North America, South America, Europe, and Asia has led to recognition that this yeast is more widely distributed than previously recognised^[12-14]. In 2014 Baddley *et al*^[15] found that *C. gattii* accounts for approximately 20% of cryptococcal infections. Genotyping identified at least four molecular types or genotypes of *C. gattii*, VGI, VGII, VGIII, and VGIV with each of these genotypes containing subtypes^[1]. Subsequent published genotypes have revealed greater genetic diversity than is encompassed by the previously delineated taxonomy. As such Kwon-Chung *et al*^[3] suggested that “*C. gattii* species complex” be used.

VGI and non-outbreak VGII have been associated with particularly severe cases of CNS infection^[16]. VGIIa strains reported in outbreak regions of the USA have been associated with higher rates of pulmonary infection, however CNS involvement is common to all types^[7].

Environmental and Host Factors The primary environmental factor associated with infection appears to be exposure to decayed tree hollows. *C. gattii* has been isolated from over 50 tree species, with eucalypt trees in particular linked to the higher rates of infection seen in Australia^[17]. In the USA, favourable biogeoclimatic zones in the Pacific Northwest are thought to be responsible for the development of an ecological niche; *C. gattii* has consistently been recovered from native trees, soil and freshwater in this region^[11].

In contrast with *C. neoformans*, which is almost universally associated with compromised cell-mediated immunity, *C. gattii* (VGI and VGII) appears to have a tropism for immunocompetent hosts. More recent studies have shown an increased risk of *C. gattii* infection in patients with positive HIV status, solid organ transplant, malignancy, and idiopathic

CD4 lymphopenia, particularly in outbreak regions^[9-10]. Male sex has also been positively associated with *C. gattii* infection, although it is likely that this is linked to environmental exposures^[6].

Ophthalmic Symptoms and Signs Table 1 documents our review of the literature encompassing 331 cases of *C. gattii* CNS infection that ophthalmic manifestations were reported^[4,6-7,10,18-27]. The majority of patients were immunocompetent. Ophthalmic symptoms reported at presentation ranged from blurred vision, reported at 40%-62% in two case series^[6-7], and diplopia, reported at 20% in one case series^[7].

These visual symptoms generally occur with headache, nausea and vomiting, and are attributable to papilloedema, the most commonly reported ophthalmic sign, with rates ranging from 43%-50% in earlier studies from Australia and Papua New Guinea (PNG)^[4,19]. While LP was not routinely performed to document intracranial hypertension, Seaton *et al*^[20] reported a rate of optic disc swelling of 81% at presentation in a case series of 82 patients. Notably, they found that rates of optic disc swelling were associated with a significantly longer time from onset of symptoms to presentation, which may account for the lower rates observed in developed countries. More recently Chen *et al*^[10] documented a rate of 16% in an Australian study, with associated optic atrophy in 9% of cases. In the United States Harris *et al*^[6] report papilloedema in 10% of cases. Notably, Harris *et al*^[6] differentiates between outbreak and non-outbreak types: in outbreak types associated with VGIIa infection, papilloedema was observed in 6% of cases, whereas a rate of 22% was observed in infections caused by non-outbreak types.

Cranial nerve (CN) palsies have also been documented in 20% of patients reported by Laloo *et al*^[4] in PNG and 18% in Australia by Chen *et al*^[10]. CN VI was involved most frequently in both cases series. Whether CN palsies are a result of direct invasion by *C. gattii*, or secondary to increased ICP has not been determined. We found one further case of endogenous endophthalmitis secondary to *C. gattii*, diagnosed on PET scan and confirmed with vitreous biopsy^[25]. Prior to our case series, there has also been only one previous case of retinal cryptococcomas secondary to *C. gattii* reported in the literature^[26]. Interestingly in both cases there did not appear to be loss of VA. Whether this is truly a rare phenomenon, or rather due to lack of routine dilated eye examination is unclear.

Visual Outcomes In PNG, Seaton *et al*^[20] studied 82 patients with *C. gattii* meningitis and found that 51% of patients had developed “varying degrees of visual loss” and 31% became blind during the course of their illness. Visual loss was significantly associated with CN VI palsy, and serum and CSF *Cryptococcus* antigen (Crag) titres $\geq 1:1024$ It is

Table 1 *C. gattii* neuro-ophthalmic infections: a review of case series and case reports 1990-2020

Authors	Year	Location	Cases	Host status	Neuro-ophthalmic manifestations	Visual outcome
Lalloo <i>et al</i> ^[4]	1994	Papua New Guinea	49	IC	Funduscopy abnormalities (53%); CN palsy (22%)	Blindness (31% of survivors)
Mitchell <i>et al</i> ^[19]	1995	Australia	26	IC	Papilloedema (50%)	Not specified
Laurenson <i>et al</i> ^[21]	1996	Papua New Guinea	7	IC	Papilloedema (43%)	Decreased VA (43%)
Seaton <i>et al</i> ^[20]	1997	Papua New Guinea	82	IC	Disc swelling (76%); CN palsy (52%)	Decreased VA (50%); blindness (37%)
Chau <i>et al</i> ^[18]	2010	Vietnam	10	Not specified	Blurred vision (40%); diplopia (20%); papilloedema (50%)	Not specified
Harris <i>et al</i> ^[6]	2011	USA	49 ^a	Not specified	Blurred vision (18%); papilloedema (6%)	Not specified
Chen <i>et al</i> ^[10]	2012	Australia	73	IC (54), IS (19)	Papilloedema (16%); optic atrophy (9%); CN palsy (18%)	Decreased VA (11%); blindness (4%)
Harris <i>et al</i> ^[7]	2013	USA	25	Not specified	Papilloedema (8%); blurred vision (62%)	Not specified
Illnait-Zaragozi <i>et al</i> ^[22]	2013	Cuba	1	IC	Blurred vision; diplopia	Blindness
Espino Barros Palau <i>et al</i> ^[23]	2014	Canada	1	IS	Papilloedema; retinitis	Decreased VA
Chen <i>et al</i> ^[24]	2016	Taiwan, China	1	IC	Papilloedema; sub-hyaloid/retinal haemorrhage	Blindness
Lin <i>et al</i> ^[25]	2017	India	1	IC	Endophthalmitis	Decreased VA
Johnson <i>et al</i> ^[26]	2018	USA	1	IS	Retinitis, retinal cryptococcomas	Preserved VA
Bauer <i>et al</i> ^[27]	2018	Germany	1	IC	Decreased VA	Decreased VA
Current study	2021	Australia; USA	4	IC (3), IS (1)	Retinal cryptococcomas; papilloedema (2)	Decreased VA (4)

^aData available for 49/76 patients. IC: Immunocompetent; IS: Immunosuppressed; CN: Cranial nerve; VA: Visual acuity.

unclear whether patients in this case series received ICP lowering therapies, which may have a profound impact on visual outcomes.

In Australia, Chen *et al*^[10] report rates of visual loss at 11%, with blindness in 4%. CSF Crag \geq 1:256 and abnormal neurology at presentation were associated with death and long-term neurological sequela. Speed and Dunt^[5] compare *C. neoformans* and *C. gattii* in Victoria during the AIDS epidemic, and suggest that patients with *C. gattii* infection were more likely to have focal CNS features, papilloedema and neurological sequelae and to undergo surgical procedures when compared to *C. neoformans*, however exact figures are not specified. Studies in the United States have paid minimal attention to visual outcomes with no ophthalmic outcome data reported in either case series.

In summary, though many papers examining *C. gattii* meningitis note ophthalmic signs and symptoms, there is limited data regarding long-term sequelae, and only one study that specifically examined risk factors for visual loss. Reported rates of visual loss varied from 11%-53%, in contrast to studies examining *C. neoformans*, where visual loss has been reported in 1%-9% of cases^[28-29].

Pathobiology of Disease *Cryptococcus spp.* establishes infection in the lung *via* inhalation of spores. From this point it enters the blood-stream and traverses the blood-brain barrier before entering the CSF. The prototypic finding of cryptococcal meningitis (CM) is intracranial hypertension, often in the

absence of significant inflammation. While the underlying mechanism of elevated ICP is likely multi-factorial, the theory given most weight in the literature is fungal blockage of CSF at the level of the arachnoid villi^[30]. Occasionally obstructive hydrocephalus occurs, often secondary to a mass effect in the presence of cryptococcomas^[19]. However, the presence of intracranial hypertension in the absence of radiological hydrocephalus is also frequently observed and has been attributed to equivalent pressures between intraventricular fluid and CSF surrounding the brain and the paucity of intraventricular fungal elements, preventing ventricular dilation^[31].

Papilloedema is defined as optic nerve swelling secondary to intracranial hypertension and is the most frequently cited mechanism for visual loss in CM^[32-33], with direct fungal invasion or compression of the optic nerve cited as other mechanisms for visual loss^[34]. One recent study found that intracranial hypertension and increased fungal burden are independently associated with severe visual loss^[35]. It is notable that even though papilloedema was observed to be a risk factor for visual sequelae in our review, it has not universally been observed on funduscopy examination, and optic nerve sheath dilatation or inflammation has not been consistently visualized on MRI^[36].

This has led to the proposal of optic nerve sheath compartment syndrome (ONSCS) as a possible mechanism of visual loss in *Cryptococcus spp.* infections by Moodley *et al*^[36]. Plugging of

the peri-optic space at the mid-orbital level of the optic sheath by cryptococcal fungal elements is theorised to cause a large pressure gradient between the intracranial sub-arachnoid space and the proximal peri-optic CSF space. In their studies this is demonstrated by enlargement of peri-optic space and loss of peri-optic CSF signal during phases of elevated CSF pressure on T2 weighted MRI, with return following lowering of CSF pressure^[37]. ONSCS follows during the initial phase, causing optic nerve compression, axoplasmic stasis, and ischaemia. Optic nerve dysfunction may ensue with visual blurring and visual loss.

Treatment Ophthalmic manifestations of *C. gattii* occur in the context of CNS infection and treatment modalities focus on anti-fungal therapies for pathogen eradication, and ICP-lowering therapies for prevention of neuro-ophthalmic sequelae. Infectious Disease Society of America (IDSA) treatment guidelines do not differentiate between *C. gattii* and *C. neoformans* infection, but do outline therapeutic approaches based on host status and complications of cryptococcosis^[38].

In the immunocompetent host, induction therapy with amphotericin B and flucytosine for 4-6wk is recommended; with the longer induction regimen reserved for patients with neuro-ophthalmic symptoms at baseline. CSF should be examined every second week for clearance during the induction phase. Induction therapy should be prolonged in two weeks cycles until fungal clearance is demonstrated. High dose fluconazole is then suggested for a further 8wk, followed by maintenance therapy with low dose fluconazole for a further 6-12mo, or longer dependent on clinical response. Patients with renal impairment at baseline should receive liposomal amphotericin B. For patients co-infected with HIV specialist advice should be sought regarding 1) timing of antifungal therapy and initiation of antiretroviral therapy, and 2) the duration of antifungal therapy.

Management of intracranial hypertension is a critical component of therapy. IDSA guidelines recommend baseline LP with measurement of OP, with target closing pressure <20 cm CSF or <50% of OP^[38]. If symptoms and signs of intracranial hypertension persist, daily LP should be performed. In refractory cases, CSF diversion procedures should be considered. The role of CSF diversion versus medical management has yet to be studied in a clinical trial, however optic nerve fenestration for management of visual loss associated with papilloedema has been performed in individual cases with good visual outcomes^[39]. Unlike in cases of idiopathic intra-cranial hypertension and other causes of intracranial hypertension, mannitol and acetazolamide have not shown effectiveness in management of CM. The use of acetazolamide showed increased rates of metabolic acidosis and more-frequent serious adverse events than subjects who

received placebo^[40]. Metabolic acidosis is thought to be related to the combination of acetazolamide and amphotericin.

The role of steroids in the management of CM-induced intracranial/optic nerve oedema has proved controversial. Seaton *et al*^[41] demonstrated a significant improvement in rates of visual deterioration in patients with *C. gattii* meningitis treated with corticosteroids (12.5% vs 70%, $P=0.007$) in a case series of 26 patients in PNG in 1997. A subsequent randomized, double-blind, placebo-controlled trial assigned patients to dexamethasone plus standard cares versus standard cares alone. *Cryptococcus spp.* was not identified, and all patients in the study had HIV. Mortality rates in the steroid group trended higher, without any noted improvement in visual outcomes, and a significantly higher rate of adverse clinical events^[42].

In conclusion, these cases illustrate the diverse and potentially devastating systemic and ophthalmic manifestations of *C. gattii* infections and highlights the key role ophthalmologists can play in the diagnosis and management of this emerging infection.

ACKNOWLEDGEMENTS

The authors would like to thank Kayla Morris PhD for her assistance with the provision of images for the case report number three.

Foundation: Campbell TG received support from the Hector Maclean Scholarship through the Centre for Eye Research Australia and Department of Surgery, University of Melbourne, Australia.

Conflicts of Interest: Campbell TG receives salary support from Bayer Pharmaceuticals through a unrestricted educational grant to the Centre for Eye Research Australia; McCabe GA, None; McHugh JW, None; Goodwin T, None; Johnson DF, None; Fok A, None.

REFERENCES

- 1 Chen SC, Meyer W, Sorrell TC. *Cryptococcus gattii* infections. *Clin Microbiol Rev* 2014;27(4):980-1024.
- 2 Hagen F, Khayhan K, Theelen B, Kolecka A, Polacheck I, Sionov E, Falk R, Pammen S, Lumbsch HT, Boekhout T. Recognition of seven species in the *Cryptococcus gattii*/*Cryptococcus neoformans* species complex. *Fungal Genet Biol* 2015;78:16-48.
- 3 Kwon-Chung KJ, Boekhout T, Fell JW, Diaz M. (1557) Proposal to conserve the name *Cryptococcus gattii* against *C. hondurians* and *C. bacillisporus* (basidiomycota, hymenomycetes, Tremellomycetidae). *TAXON* 2002;51(4):804-806.
- 4 Lalloo D, Fisher D, Naraqi S, Laurenson I, Temu P, Sinha A, Saweri A, Mavo B. Cryptococcal meningitis (*C. neoformans* var. *gattii*) leading to blindness in previously healthy Melanesian adults in Papua New Guinea. *Q J Med* 1994;87(6):343-349.
- 5 Speed B, Dunt D. Clinical and host differences between infections with the two varieties of *Cryptococcus neoformans*. *Clin Infect Dis* 1995;21(1):28-34.

- 6 Harris JR, Lockhart SR, Debess E, Marsden-Haug N, Goldoft M, Wohrle R, Lee S, Smelser C, Park B, Chiller T. *Cryptococcus gattii* in the United States: clinical aspects of infection with an emerging pathogen. *Clin Infect Dis* 2011;53(12):1188-1195.
- 7 Harris JR, Lockhart SR, Sondermeyer G, Vugia DJ, Crist MB, D'Angelo MT, Sellers B, Franco-Paredes C, Makvandi M, Smelser C, Greene J, Stanek D, Signs K, Nett RJ, Chiller T, Park BJ. *Cryptococcus gattii* infections in multiple states outside the US Pacific Northwest. *Emerg Infect Dis* 2013;19(10):1620-1626.
- 8 Cuetara MS, Jurdado Ruiz-Capillas JJ, Nuñez-Valentin MP, Rodríguez García E, García-Benayas E, Rojo-Amigo R, Rodríguez-Gallego JC, Hagen F, Colom MF. Successful isavuconazole salvage therapy for a *Cryptococcus deuterogattii* (AFLP6/VGII) disseminated infection in a European immunocompetent patient. *Mycopathologia* 2021;186(4):507-518.
- 9 MacDougall L, Fyfe M, Romney M, Starr M, Galanis E. Risk factors for *Cryptococcus gattii* infection, British Columbia, Canada. *Emerg Infect Dis* 2011;17(2):193-199.
- 10 Chen SC, Slavin MA, Heath CH, Playford EG, Byth K, Marriott D, Kidd SE, Bak N, Currie B, Hajkovicz K, Korman TM, McBride WJ, Meyer W, Murray R, Sorrell TC, Australia and New Zealand Mycoses Interest Group (ANZMIG)-Cryptococcus Study. Clinical manifestations of *Cryptococcus gattii* infection: determinants of neurological sequelae and death. *Clin Infect Dis* 2012;55(6):789-798.
- 11 Acheson ES. Exploring the ecological factors behind the 1999 outbreak of *Cryptococcus gattii* sensu lato on Vancouver Island (T). *University of British Columbia*. 2020. <https://open.library.ubc.ca/collections/ubctheses/24/items/1.0394901>
- 12 Parra-Vera H, Espinoza W, Godoy-Martínez P, et al. First report of *Cryptococcus gattii* in Ecuador. *Revista científica digital INSPILIP* 2019;3(1):1-9.
- 13 Berejnoi A, Taverna CG, Mazza M, Vivot M, Isla G, Córdoba S, Davel G. First case report of cryptococcosis due to *Cryptococcus decagattii* in a pediatric patient in Argentina. *Rev Soc Bras Med Trop* 2019;52:e20180419.
- 14 Marr KA. *Cryptococcus gattii* as an important fungal pathogen of western North America. *Expert Rev Anti Infect Ther* 2012;10(6):637-643.
- 15 Baddley J, Perfect J, Chen S. Epidemiology and outcomes of cryptococcosis: description of an international, multi-center cohort. *Interscience Conference on Antimicrobial Agents and Chemotherapy*; Washington DC. 2014.
- 16 Harris JR, Galanis E, Lockhart SR. *Cryptococcus gattii* infections and virulence. *Curr Fungal Infect Rep* 2014;8(1):81-89.
- 17 Springer DJ, Chaturvedi V. Projecting global occurrence of *Cryptococcus gattii*. *Emerg Infect Dis* 2010;16(1):14-20.
- 18 Chau TT, Mai NH, Phu NH, Nghia HD, Chuong LV, Sinh DX, Duong VA, Diep PT, Campbell JI, Baker S, Hien TT, Laloo DG, Farrar JJ, Day JN. A prospective descriptive study of cryptococcal meningitis in HIV uninfected patients in Vietnam-high prevalence of *Cryptococcus neoformans* var *grubii* in the absence of underlying disease. *BMC Infect Dis* 2010;10:199.
- 19 Mitchell DH, Sorrell TC, Allworth AM, Heath CH, McGregor AR, Papanoum K, Richards MJ, Gottlieb T. Cryptococcal disease of the CNS in immunocompetent hosts: influence of cryptococcal variety on clinical manifestations and outcome. *Clin Infect Dis* 1995;20(3):611-616.
- 20 Seaton RA, Verma N, Naraqi S, Wembri JP, Warrell DA. Visual loss in immunocompetent patients with *Cryptococcus neoformans* var. *gattii* meningitis. *Trans R Soc Trop Med Hyg* 1997;91(1):44-49.
- 21 Laurenson IF, Trevett AJ, Laloo DG, Nwokolo N, Naraqi S, Black J, Tefurani N, Saweri A, Mavo B, Igo J, Warrell DA. Meningitis caused by *Cryptococcus neoformans* var. *gattii* and var. *neoformans* in Papua New Guinea. *Trans R Soc Trop Med Hyg* 1996;90(1):57-60.
- 22 Illnait-Zaragozí MT, Ortega-Gonzalez LM, Hagen F, Martínez-Machin GF, Meis JF. Fatal *Cryptococcus gattii* genotype AFLP5 infection in an immunocompetent Cuban patient. *Med Mycol Case Rep* 2013;2:48-51.
- 23 Espino Barros Palau A, Morgan ML, Foroozan R, Lee AG. Neuro-ophthalmic presentations and treatment of Cryptococcal meningitis-related increased intracranial pressure. *Can J Ophthalmol* 2014;49(5):473-477.
- 24 Chen CH, Wang SH, Chen WL, Wang WF, Chen SN. Ocular complications caused by *Cryptococcus gattii* AFLP4/VGI meningitis in an immunocompetent host. *Rev Inst Med Trop Sao Paulo* 2016;58:85.
- 25 Lin CJ, Chen WL, Lin JM, Tien PT, Tsai YY. Endogenous endophthalmitis caused by *Cryptococcus neoformans* Var. *Gattii* mimicking choroidal tumor: From positron-emission tomography/computed tomography to histopathology. *Indian J Ophthalmol* 2017;65(6):526-528.
- 26 Johnson WJ, Blice JP, Lee KK. Bilateral asymptomatic cryptococcal retinitis without choroiditis or vitritis. *Ophthalmology* 2018;125(4):528.
- 27 Bauer M, Wickenhauser C, Haak A, Pazaitis N, Siebolts U, Mawrin C, Strauss C, Rickerts V, Stoevesandt D, Cornely OA, Meis JF, Hagen F. Case report: a fatal case of cryptococcosis in an immunocompetent patient due to *Cryptococcus deuterogattii* (AFLP6/VGII). *JMM Case Rep* 2018;5(10):e005168.
- 28 Rex JH, Larsen RA, Dismukes WE, Cloud GA, Bennett JE. Catastrophic visual loss due to *Cryptococcus neoformans* meningitis. *Medicine* 1993;72(4):207-224.
- 29 Lin XR, Heitman J. The Biology of the *Cryptococcus neoformans* species complex. *Annu Rev Microbiol* 2006;60(1):69-105.
- 30 Lee SC, Casadevall A. Polysaccharide antigen in brain tissue of AIDS patients with cryptococcal meningitis. *Clin Infect Dis* 1996;23(1):194-195.
- 31 Moodley A, Rae W, Bhigjee A. Visual loss in HIV-associated cryptococcal meningitis: a case series and review of the mechanisms involved. *South Afr J HIV Med* 2015;16(1):305.
- 32 Kestelyn P. *Cryptococcus*. In: Gupta V, Nguyen Q, LeHoang P, Agarwal A. (eds) *The Uveitis Atlas* Springer: New Delhi, 2020.
- 33 Small KW, Barshak MB. Cryptococcosis. In: Foster CS, Anesi SD, Chang PY. (eds) *Uveitis*. Springer: Cham, 2021.

- 34 Rigi M, Khan K, Smith SV, Suleiman AO, Lee AG. Evaluation and management of the swollen optic disk in cryptococcal meningitis. *Surv Ophthalmol* 2017;62(2):150-160.
- 35 Molloy SF, Ross B, Kanyama C, *et al.* Fungal burden and raised intracranial pressure are independently associated with visual loss in human immunodeficiency virus-associated cryptococcal meningitis. *Open Forum Infect Dis* 2021;8(4):ofab066.
- 36 Moodley A, Rae W, Bhigjee A, Loubser N, Michowicz A. New insights into the pathogenesis of cryptococcal induced visual loss using diffusion-weighted imaging of the optic nerve. *Neuroophthalmology* 2012;36(5):186-192.
- 37 Moodley A, Naidoo N, Reitz D, Chetty N, Rae W. The optic nerve compartment syndrome in *Cryptococcus*-induced visual loss. *Neuroophthalmology* 2013;37(3):124-128.
- 38 Perfect JR, Dismukes WE, Dromer F, Goldman DL, Graybill JR, Hamill RJ, Harrison TS, Larsen RA, Lortholary O, Nguyen MH, Pappas PG, Powderly WG, Singh N, Sobel JD, Sorrell TC. Clinical practice guidelines for the management of cryptococcal disease: 2010 update by the Infectious Diseases Society of America. *Clin Infect Dis* 2010;50(3):291-322.
- 39 Milman T, Mirani N, Turbin RE. Optic nerve sheath fenestration in cryptococcal meningitis. *Clin Ophthalmol* 2008;2(3):637-639.
- 40 Newton PN, Thai le H, Tip NQ, Short JM, Chierakul W, Rajanuwong A, Pitisuttithum P, Chasombat S, Phonrat B, Maek-A-Nantawat W, Teanadi R, Laloo DG, White NJ. A randomized, double-blind, placebo-controlled trial of acetazolamide for the treatment of elevated intracranial pressure in cryptococcal meningitis. *Clin Infect Dis* 2002;35(6):769-772.
- 41 Seaton RA, Verma N, Naraq S, Wembri JP, Warrell DA. The effect of corticosteroids on visual loss in *Cryptococcus neoformans* var. gattii meningitis. *Trans R Soc Trop Med Hyg* 1997;91(1):50-52.
- 42 Beardsley J, Wolbers M, Kibengo FM, *et al.* Adjunctive dexamethasone in HIV-associated cryptococcal meningitis. *N Engl J Med* 2016;374(6):542-554.