

A novel surgical technique to prevent post-enucleation conjunctival cyst: conjunctival staining with methylthioninium

Xiao-Feng Li, Jiang Qian

Department of Ophthalmology, Fudan Eye & ENT Hospital; NHC Key Laboratory of Myopia, Fudan University; Laboratory of Myopia, Chinese Academy of Medical Sciences, Shanghai 200031, China

Correspondence to: Jiang Qian. Department of Ophthalmology, Fudan Eye & ENT Hospital of Fudan University, 83 Fenyang Road, Shanghai 200031, China. qianjiang58@hotmail.com

Received: 2020-10-12 Accepted: 2020-12-24

DOI:10.18240/ijo.2022.01.24

Citation: Li XF, Qian J. A novel surgical technique to prevent post-enucleation conjunctival cyst: conjunctival staining with methylthioninium. *Int J Ophthalmol* 2022;15(1):167-168

Dear Editor,

Conjunctival cyst of the orbit acquired from enucleation is an infrequent but serious complication^[1-9] which can occur in 3%-7% of patients, more commonly after a secondary procedure^[2]. The most common manifestations are the inability to retain the external prosthesis, foreign body sensation or bleeding^[4]. Treatment by excision, marsupialization, or injection of sclerosing agents (absolute alcohol, trichloroacetic acid, and sodium tetradecyl sulfate)^[5-8] have been proposed. However, recurrent conjunctival incisions may lead to barrier weakness and implant exposure, scarring, and shortening of the conjunctival surface area. Despite the variety of treatments, the cosmetic result can be poor. For example, implant removal or replacement was required in 8 of 9 cases presented by McCarthy *et al*^[1] and 3 of 5 cases by Smit *et al*^[2].

The mechanism of conjunctival cyst in an anophthalmic orbit is postulated as follows^[1]: 1) the inadvertent implantation of a free fragment of conjunctival tissue within Tenon's capsule during enucleation surgery; 2) incarceration of a tongue of conjunctiva that is accidentally inverted in wound closure through Tenon's capsule; 3) epithelial down-growth. To prevent an acquired conjunctival cyst, it is therefore important to close Tenon's capsule and conjunctiva with great care as two separate tissues^[2]. In fact, however, the conjunctiva

may be difficult to distinguish from Tenon's capsule due to surgery-induced tissue swelling and collapsed orbital tissue in secondary implantations^[2]. We report herein the use of conjunctival methylthioninium stain to aid visibility of and distinction between the conjunctiva and Tenon's capsule. Written informed consent was obtained by the patient to allow publication of the present case and any related image and this case study is in accordance with the tenets of the Declaration of Helsinki.

A 45-year-old male, otherwise healthy, with an enophthalmic right eye was referred to our hospital at the patient's request, for cosmetic enhancement. The patient had a history of penetrating trauma and emergent surgical repair to his right eye, one year previously. The vision of the right eye was no light perception and B-scan ultrasound revealed atrophy of the right eye. No abnormality was observed in the left eye. After informed consent was obtained, evisceration surgery was performed under general anesthesia.

After routine sterilization of the area undergoing surgery, a dry cotton-swab was used to remove superfluous fluid in the conjunctival sac, to avoid unnecessary spread of methylthioninium and to facilitate visibility of the area of interest. A second dry cotton-swab was soaked with 10 mg/mL methylthioninium (JUMPCAN Pharmaceutical Group Co.LTD, China), and conjunctival staining was accomplished by rolling this cotton-swab on the conjunctival surface (Figure 1A). A standard procedure evisceration and orbital implant placement was then undertaken. Finally, prior to wound closure, the conjunctiva was separated from Tenon's capsule, facilitated by selective staining of the conjunctiva (Figure 1B). Tenon's capsule (Figure 1C) was sutured using 6-0 absorbable Vicryl (Johnson & Johnson, New Brunswick, New Jersey, USA) followed by conjunctival suture (Figure 1D) using 8-0 absorbable Vicryl (Johnson & Johnson, New Brunswick, New Jersey, USA).

Methylthioninium, as a common mucosal stain, is widely used in gastric endoscopy examinations. In the eye region, it is mainly used for external procedures, such as excision of pterygium. In this report, we used methylthioninium for better visualization of the conjunctiva, particularly at the

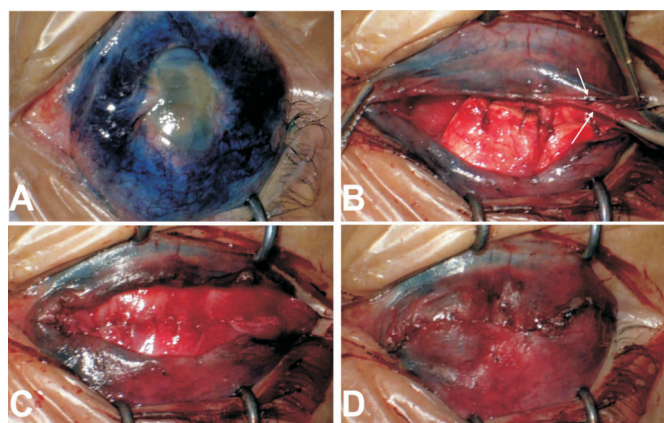


Figure 1 The surgery procedure A: Conjunctiva stained with methylthioninium; B: Clear distinction between conjunctiva (the upper arrow) and Tenon's capsule (the lower arrow) on methylthioninium staining; C: Closure of Tenon's capsule while maintaining tissue separation; D: Closure of conjunctiva.

incision site, which was otherwise not easily distinguished from Tenon's capsule due to tissue swelling. To our knowledge, this is the first report of a procedure of this kind. Although methylthioninium stains capsules, it can be toxic to intraocular structures in concentrations above 0.5%. The effects of accidental injection of methylthioninium into human eyes, such as sterile endophthalmitis, have been reported^[9]. However, in animal models, methylthioninium shows no major side effects on the external surface of the eye^[9], indicating that it is relatively safe in orbital implant surgery. Other stains such as toluidine blue, trypan blue, and indocyanine green, may also be useful for this purpose. Toluidine blue is a dye with similar chemical structure and physicochemical properties to methylthioninium; however, it is approximately five times more expensive than methylthioninium and may not be available in rural ophthalmology units^[10]. Trypan blue and indocyanine green are significantly more expensive, and trypan blue is a potentially carcinogenic vital dye in animal models, limiting their application^[11]. In contrast, methylthioninium is advantageous based on its relatively high availability and safety, and low cost.

In conclusion, the topical application of methylthioninium is a simple, inexpensive, non-invasive approach which can be used for better visualization of the conjunctiva during enucleation and orbital implant surgery, both primary and secondary, so that complete distinction between the conjunctiva and Tenon's

capsule can be achieved and conjunctival cyst may be avoided. Secondary conjunctival inclusion cysts have also been reported after other ocular surgeries, including strabismus surgery, ptosis repair, phacoemulsification with pars plana vitrectomy, and penetrating orbital injury surgery^[12] and this procedure may potentially be used in these surgeries.

ACKNOWLEDGEMENTS

Authors' contributions: Conception and design were performed by Qian J; surgery and writing were performed by Li XF.

Foundation: Supported by the National Natural Science Foundation of China (No.81970835).

Conflicts of Interest: Li XF, None; Qian J, None.

REFERENCES

- 1 McCarthy RW, Beyer CK, Dallow RL, Burke JF, Lessell S. Conjunctival cysts of the orbit following enucleation. *Ophthalmology* 1981;88(1):30-35.
- 2 Smit TJ, Koornneef L, Zonneveld FW. Conjunctival cysts in anophthalmic orbits. *Br J Ophthalmol* 1991;75(6):342-343.
- 3 Yoon JS, Lew H, Kim SJ, Lee SY. Exposure rate of hydroxyapatite orbital implants a 15-year experience of 802 cases. *Ophthalmology* 2008;115(3):566-572.e2.
- 4 Bohman E, Roed Rassmusen ML, Kopp ED. Pain and discomfort in the anophthalmic socket. *Curr Opin Ophthalmol* 2014;25(5):455-460.
- 5 Wong Y, Clarke L, Lau G. A case series of anophthalmic socket cysts excised utilising fibrin sealant. *Orbit* 2018;37(4):254-256.
- 6 Dave T, Taneja S, Tiple S, Basu, Naik MN. Conjunctival retention cysts: outcomes of aspiration and sclerotherapy with sodium tetradecyl sulfate. *Ophthalmic Plast Reconstr Surg* 2019;35(2):165-169.
- 7 Bagheri A, Shahraki K, Yazdani S. Trichloroacetic acid 10% injection for treatment of conjunctival inclusion cysts. *Orbit* 2020;39(2):107-111.
- 8 Gallagher D, Power B, Hughes E, Fulcher T. Management of orbital conjunctival epithelial inclusion cyst using trichloroacetic acid (20%) in an outpatient setting. *Orbit* 2020;39(2):147-149.
- 9 Lim AK, Ulagantheran VV, Siow YC, Lim KS. Methylene blue related sterile endophthalmitis. *Med J Malaysia* 2008;63(3):249-250.
- 10 Steffen J, Rice J, Lecuona K, Carrara H. Identification of ocular surface squamous neoplasia by *in vivo* staining with methylene blue. *Br J Ophthalmol* 2014;98(1):13-15.
- 11 Yetik H, Devranoglu K, Ozkan S. Determining the lowest trypan blue concentration that satisfactorily stains the anterior capsule. *J Cataract Refract Surg* 2002;28(6):988-991.
- 12 Song JJ, Finger PT, Kurlı M, Wisnicki HJ, Iacob CE. Giant secondary conjunctival inclusion cysts: a late complication of strabismus surgery. *Ophthalmology* 2006;113(6):1049.e1-1049.e2.