

Anti-scarring effect of sodium hyaluronate at filtration pathway after filtering surgery in rabbits

Yu-Jue Wang^{1,2,3}, Le-Meng Feng^{1,2,3}, Cheng Zhang^{1,2,3}, Wu-Long Zhang^{1,2,3}, Wei-Tao Song^{1,2,3}

¹National Clinical Research Center for Geriatric Diseases; Xiangya Hospital of Central South University, Changsha 410008, Hunan Province, China

²Eye Center of Xiangya Hospital, Central South University, Changsha 410008, Hunan Province, China

³Hunan Key Laboratory of Ophthalmology, Changsha 410008, Hunan Province, China

Co-first authors: Yu-Jue Wang and Le-Meng Feng

Correspondence to: Wei-Tao Song. National Clinical Research Center for Geriatric Diseases, Xiangya Hospital of Central South University; Eye Center of Xiangya Hospital, Central South University; Hunan Key Laboratory of Ophthalmology, Changsha 410008, Hunan Province, China. wtsong@126.com

Received: 2021-07-14 Accepted: 2021-10-22

Abstract

• **AIM:** To investigate the anti-scarring effect of sodium hyaluronate (HA) at filtration pathway after filtering surgery in a rabbit model.

• **METHODS:** Fifteen healthy adult New Zealand white rabbits were selected for trabeculectomy in both eyes. The right eyes were used as HA group with 0.1 mL HA injected into the anterior chamber at the end of the operation; the left eyes were used with 0.1 mL sodium lactate Ringer's solution (RS) injected into the anterior chamber as RS group. Intraocular pressure (IOP), filtering blebs morphology, inflammatory reaction and complications were observed at the 7, 60, and 90d after surgery.

• **RESULTS:** One day after surgery, the IOP of HA and RS groups were 12.75 ± 1.92 and 10.50 ± 1.59 mm Hg ($P=0.005$). At the 7th day postoperative, the filtering blebs of each group were functional type and TGF- β expression was significantly difference in both groups (0.10 ± 0.01 vs 0.14 ± 0.02 , $P=0.024$). After 60d of the operation, all filtering blebs were scarring and alpha-smooth muscle actin (α -SMA) expression was significantly difference in both groups (0.40 ± 0.04 vs 0.35 ± 0.02 , $P=0.032$). α -SMA positive cells were mainly distributed in the junction of conjunctiva and sclera and around the blood vessels. The collagen volume fraction (CVF) of HA and RS group was $(75.49 \pm 7.01)\%$

and $(79.93 \pm 5.35)\%$ ($P=0.044$). On the 90th day after the operation, CVF was $(82.57 \pm 5.19)\%$ and $(88.08 \pm 1.75)\%$ in HA and RS groups ($P=0.036$). There was no α -SMA positive cell in HA group, while a few positive cells were observed in RS group ($P=0.000$).

• **CONCLUSION:** HA has effect of anti-scar and anti-inflammation on filtration pathway after filtering surgery within 3mo by inhibiting fibroblast proliferation and collagen deposition.

• **KEYWORDS:** sodium hyaluronate; filtering surgery; anti-scarring; glaucoma

DOI: 10.18240/ijo.2022.04.04

Citation: Wang YJ, Feng LM, Zhang C, Zhang WL, Song WT. Anti-scarring effect of sodium hyaluronate at filtration pathway after filtering surgery in rabbits. *Int J Ophthalmol* 2022;15(4):547-553

INTRODUCTION

Glaucoma is the first irreversible blindness disease, characterized by atrophy and depression of the optic disc, visual field defect, and vision decreased, and is often related to the level of intraocular pressure (IOP)^[1-2]. Nowadays the glaucoma treatment often includes two aspects: reducing IOP and protecting the optic nerve. Unfortunately, the results of clinical trials about optic neuroprotective is disappointing. Treatments of reducing IOP is still the only effective method for glaucoma treatment^[3-6], among which, the surgical treatment is easier to achieve the target of lower-level IOP compare to drug and laser^[7]. Trabeculectomy is the most effective surgical method but has many postoperative complications. For example, filtering bubble fiber wrapping is a common postoperative complication^[8], which is also the primary reason leading to the failure of trabeculectomy^[9-10]. In order to solve this problem, researchers have carried out many explorations like using the anti-fiber preparations as adjuvant therapy during surgery^[11-13]. But unfortunately, these methods can induce other side effects, such as endophthalmitis^[14].

Sodium hyaluronate (HA) is a natural component of the human eye, which has high water solubility and is easy to produce^[15-17]. It is widely used as a viscoelastic agent in

ophthalmic surgery^[18-20]. Combined trabeculectomy, which applies detachable suture technology, antimetabolites, anterior chamber puncture technology or intraoperative pre-evaluation of postoperative filtration in trabeculectomy, is a currently common anti-glaucoma surgery^[17]. HA has been widely used in dermatology, joint surgery and many other medical filed. Previous studies showed HA has effects of anti-inflammatory, anti-scarring, and pain-relieving^[21-25]. Whether the HA play an anti-inflammatory effect, thereby reducing the incidence of fibrosis in the filtration channel was not clear. Unfortunately, there are few researches in this area, most clinical studies and animal experiments about the HA use in glaucoma filtering surgery always focus on its effect on maintaining the morphology and function of blebs, and avoid postoperative shallow chamber^[26-31]. However, there are some clinical trials reported that HA could not reduce postoperative complications, but may increase the postoperative intraocular^[22]. We found a small amount of HA injection at the end of combined trabeculectomy can effectively avoid early postoperative low IOP and shallow anterior chamber. Patients with HA assisted anterior chamber formation had better IOP, and their filtering blebs were more diffuse and more inclined to be type I filtering blebs^[20] (Figure 1). In this study we used a preservative-free medical HA gel in an animal experiment to clarify the relationship between HA and fibrosis of the filtration channel after filtration surgery and explore a new way to reduce the complications of filtration surgery in glaucoma patients.

MATERIALS AND METHODS

Ethical Approval Fifteen healthy adult New Zealand white rabbits, weighing 1.8-2.2 kg, not limited to males and females are provided by the Department of Experimental Animals of Central South University. The animals were raised in the Department of Experimental Animals, bred for one week before the experiment. All experimental operations are in compliance with the Central South University Laboratory Animal Welfare Ethics Review Form.

Animals and Groups Fifteen New Zealand white rabbits were numbered sequentially. Because different rabbits had significantly different baseline IOP and wound-healing reactions. Drawing lessons and experience from other studies about filtering surgery in rabbits^[32-34], we performed the surgery on both rabbits' eyes to diminish the impact of individual difference. After the surgery, the right eye was used as HA group, and 0.1 mL medical HA was injected into the anterior chamber, while the left eye was used as the Ringer's solution (RS) group, and 0.1 mL sodium lactate RS was injected into the anterior chamber.

Reagents Medical HA gel was purchased from Bausch & Lomb Company (composed of HA and physiological buffer without any preservatives). RS was purchased from Sichuan

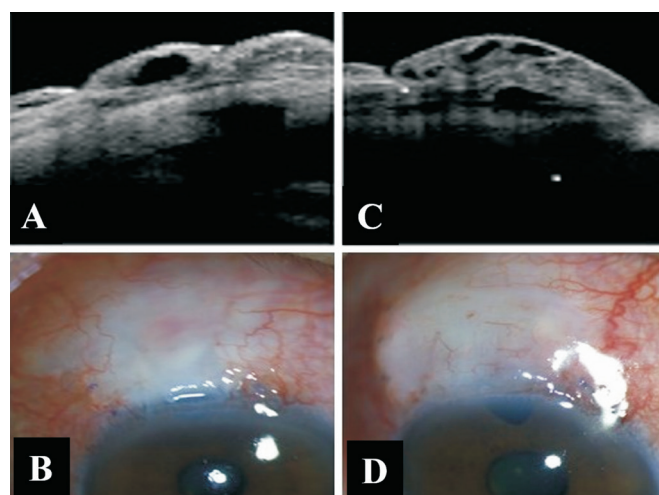


Figure 1 Optical coherence tomography (OCT) and slit-lamp examination of a patient's anterior segment 1mo after surgery A, B: The filtering bleb with sodium lactate Ringer's solution assisted was diffused (type II) with a large low-reflection area under the conjunctiva, slightly thicker wall, and visible filtering way; C, D: The filtering bleb with sodium hyaluronate assisted was multi-cystic (type I) with several low-reflective areas of varying sizes under the conjunctiva, thin walls, and visible filtering way.

Kelun Pharmaceutical Corporation. Mouse anti alpha-smooth muscle actin (α -SMA) monoclonal antibody was purchased from Abcam, UK, rabbit anti transforming growth factor-beta (TGF- β) polyclonal antibody was purchased from Beijing Boaosen Biotechnology Corporation, FITC-labeled mouse anti rabbit IgG fluorescent secondary antibody was purchased from Santa Cruz, USA. SABC-POD(F) (mouse IgG) and DAB color development kit were purchased from Wuhan Boster Bioengineering Corporation.

Trabeculectomy in Rabbit One day before the operation, IOP was measured three times. The rabbits were anesthetized by intravenous injection of 1% sodium pentobarbital solution (3 mL/kg). Oxybucaine hydrochloride eye drop and 1% lidocaine hydrochloride subconjunctival injection were used as local anesthesia. Make a conjunctival flap with the fornix as the base on the upper temporal part to expose the sclera. Make the scleral flap and excised the rectangular trabecular tissue. Cut off the peripheral iris tissue of the corresponding part, and the aqueous humor of the anterior chamber is released. The 0.1 mL of HA gel was injected in anterior chamber and under scleral flap in right eye and 0.1 mL of RS was injected in left eye (Figure 2).

Filtering Bleb Morphology On 1, 7, 28, 60, and 90d after operation, the size, shape, height, and surface blood vessel distribution of the filtering blebs were observed under an operating microscope. Refer to Kronfield classification method^[20]: Type I (microcystic type): the filtering vesicles are microcystic or multi-cystic, with thin walls and pale ischemia

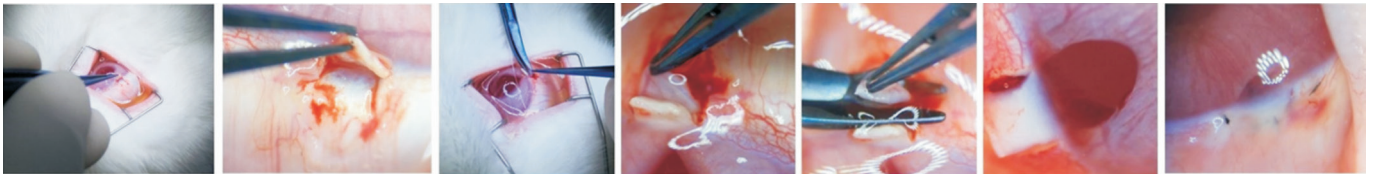


Figure 2 The surgical process of trabeculectomy in rabbit eye.

on the surface; Type II (flat diffuse type): the bubble wall is slightly thicker, slightly raised, diffuse, and the surface is relatively ischemic; Type III (scarring type): no filtering bleb or conjunctival hyperemia and micro bulging, subconjunctival scarring and adhesion on the scleral surface, multi-vascular appearance; type IV (wrap type): limited dome-shaped bulge, thick wall hyperemia, showing cystic hyperplasia. Among them, type I and type II are functional filtering vesicles, and type III and type IV are non-functional filtering vesicles.

Immunohistochemical Staining On the 7th, 60th, and 90th day after the operation, 5 rabbits were randomly selected and sacrificed. Eyeball tissue was immersed in phosphate buffer saline (PBS). Cut off a small amount of corneal tissue. The specimens were immersed in 4% paraformaldehyde-PBS fixative solution at 4°C for 24h, and made frozen sections for the Masson's trichrome staining, α -SMA immunohistochemical staining, and TGF- β immunofluorescence staining.

Statistical Analysis SPSS23.0 statistical software (SPSS Inc., Chicago, IL, USA) was used for data analysis. The difference between two groups was compared with independent sample *t*-test. The difference in different timepoint within the same group was compared with one-way analysis of variance. Data of postoperative complications were analyzed using Chi-square test. $P < 0.05$ was considered statistically significant.

RESULTS

Intraocular Pressure There was no significant difference in IOP between HA and RS group before operation ($P = 0.764$; Table 1). The IOP of the two groups was significantly lower than that of the preoperative. The IOP on 1d after operation in RS group was significantly higher than 7d and 28d after operation ($P = 0.018$), while there were not significantly different at each time period after operation in HA group ($P > 0.05$).

The IOP of RS group decrease significantly at 1d postoperatively, and then slowly reversed. IOP of HA group decreased slowly and remained at a relatively stable level (Figure 3). The IOP in HA group was higher at 1d ($P = 0.005$) and lower at 28d ($P = 0.011$) than that of the RS group after the operation.

Filter Blebs Morphology On the first day after the operation, functional filtering blebs were formed in all the operated eyes, and the filtering blebs were highly bulged and diffuse, accompanied by conjunctival congestion and edema, and the congestion gradually subsided after 3d. On the 7th day after operation, both groups of filtering blebs were diffused with thin

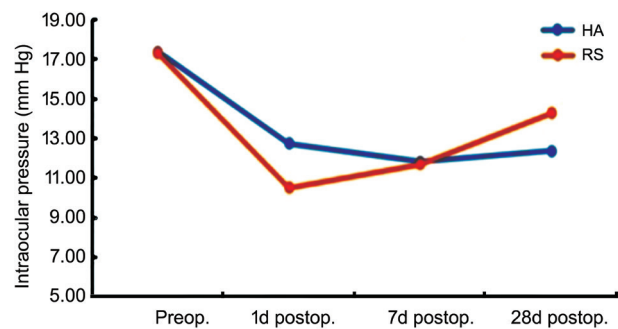


Figure 3 Changes of intraocular pressure in rabbits before and after surgery in two groups RS: Sodium lactate Ringer's solution group; HA: Sodium hyaluronate group.

Time	mean ± SD, mm Hg		
	RS group	HA group	<i>P</i>
Preop.	17.31 ± 2.05	17.38 ± 2.06	0.764
1d postop.	10.50 ± 1.59	12.75 ± 1.92	0.005
7d postop.	11.69 ± 2.18	11.81 ± 1.64	0.537
28d postop.	14.27 ± 1.27	12.36 ± 1.29	0.011

IOP: Intraocular pressure; RS: Sodium lactate Ringer's solution; HA: Sodium hyaluronate.

walls. In the RS group, sparse and slender neovascularization were seen on the surface, while in the HA group, no new blood vessels were seen on the surface of the filter blebs. At 28d postoperatively, the filtering blebs in the RS group were flat and diffuse, with abundant surface new blood vessels; in the HA group, the filtering blebs were flat and diffuse, with a small amount of new blood vessels on the surface, which were formed by the branches and growth of peripheral conjunctival small blood vessels. At 60 and 90d postoperatively, there were no functional filtering blebs in both groups. The filtering blebs were scarred, and a dense vascular network was formed on the surface. Compared with the peripheral conjunctiva, the conjunctiva of the surgical area was rich in blood vessels and irregular in shape (Figure 4).

Postoperative Inflammatory Reaction and Complications

Three eyes (20.00%) and 5 eyes (33.33%) had anterior chamber hemorrhage in HA and RS group respectively ($P = 0.682$) 1d after the operation, which was faded within 7d. One eye (6.67%) in RS group had a shallow anterior chamber (degree I) and recovered after 4d without any treatment.

Masson Staining The collagen fibers in the RS group are tightly arranged and bent and tortuous and disorder in HA group. At 7d after operation, there was no significant difference

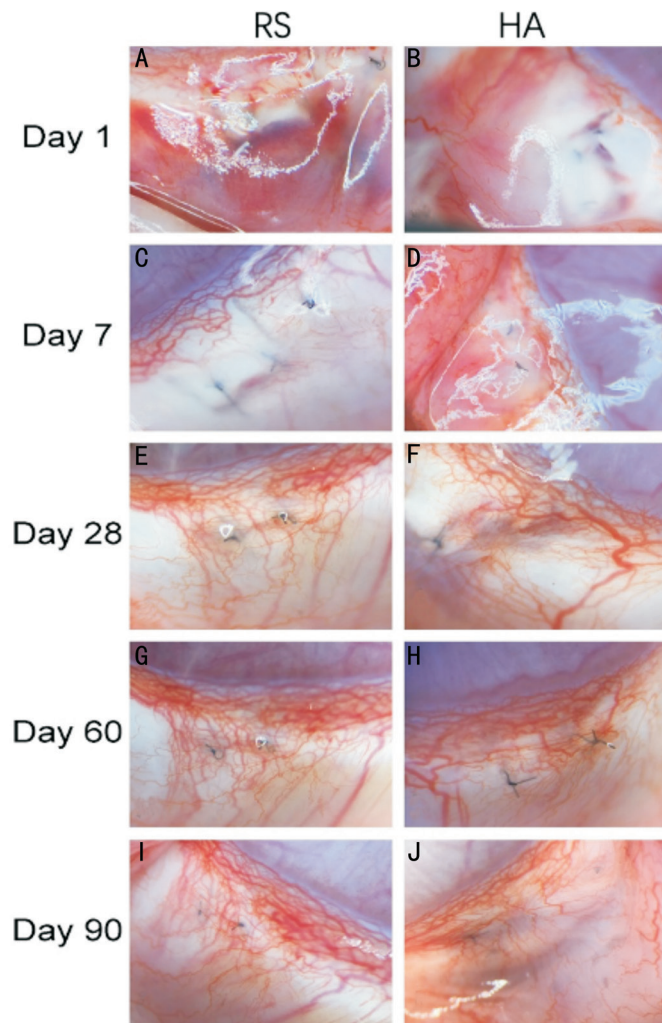


Figure 4 The morphology of filtering blebs after trabeculectomy in rabbits A-B: 1d after operation, the filtering bleb was highly bulged and diffuse, and the conjunctiva was congested and edema in both groups; C: 7d postoperatively in the RS group, the sparse and slender new blood vessels were on the surface; D: 7d after the operation in the HA group, the filtering bleb was with thin walls and no new blood vessels; E: RS group on 28d after the operation, the filtering bleb was flat and diffuse, with abundant surface neovascularization; F: 28d after operation in the HA group, the filtering vesicles were flat and diffuse, and a small amount of new blood vessels were on the surface; G-J: The blebs were scarred with a dense vascular network formed on the surface 60 and 90d after the operation in both groups. RS: Sodium lactate Ringer's solution group; HA: Sodium hyaluronate group.

of collagen volume fraction (CVF) between the two groups ($P=0.389$). It was statistically different at 60 and 90d after operation ($P=0.044, 0.036$; Table 2, Figure 5).

α -SMA Expression At 7d after operation, the expression of α -SMA was obvious in both groups, and α -SMA positive cells showed a diffuse distribution in the conjunctiva and superficial sclera. There was no significant difference of average optical density (AOD) between the two groups ($P=0.501$). At 60d postoperatively, α -SMA positive cells were mainly distributed at the junction of conjunctiva and sclera and gathered around

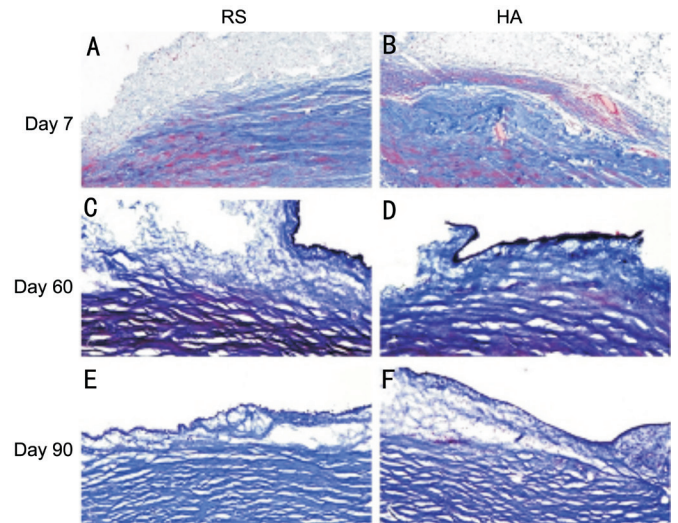


Figure 5 Masson staining ($\times 100$) A, B: 7d after operation; C, D: 60d after operation; E, F: 90d after operation. RS: Sodium lactate Ringer's solution group; HA: Sodium hyaluronate group.

Time	RS group	HA group	<i>P</i>
7d postop.	68.55 \pm 5.91	66.30 \pm 12.16	0.389
60d postop.	79.93 \pm 5.35	75.49 \pm 7.01	0.044
90d postop.	88.08 \pm 1.75	82.57 \pm 5.19	0.036

RS: Sodium lactate Ringer's solution; HA: Sodium hyaluronate.

Time	RS group	HA group	<i>P</i>
7d postop.	0.42 \pm 0.03	0.45 \pm 0.06	0.501
60d postop.	0.40 \pm 0.04	0.35 \pm 0.02	0.032
90d postop.	0.36 \pm 0.01	0.28 \pm 0.00	0.000

RS: Sodium lactate Ringer's solution; HA: Sodium hyaluronate.

Time	RS group	HA group	<i>P</i>
7d postop.	0.14 \pm 0.02	0.10 \pm 0.01	0.024
60d postop.	0.12 \pm 0.01	0.09 \pm 0.01	0.089
90d postop.	0.04 \pm 0.00	0.03 \pm 0.00	0.211

RS: Sodium lactate Ringer's solution; HA: Sodium hyaluronate.

blood vessels. After 90d, a small amount of α -SMA positive cells were under the conjunctiva in the RS group, and there was almost no positive staining in the HA group. The AOD in RS group was significant higher than of the HA group at 60 and 90d after operation ($P=0.032, 0.000$; Figure 6, Table 3).

TGF- β Expression At 7d after operation, the conjunctiva, sclera and filtration channel of the HA group and the RS group showed significant expression of TGF- β , especially in RS group ($P=0.024$). After 60d, the expression of TGF- β was significantly reduced, mainly concentrated in the subconjunctiva. After 90d, there was almost no expression of TGF- β in both groups, and occasionally scattered a small amount of positive staining in the subconjunctiva or deep sclera (Figure 7, Table 4).

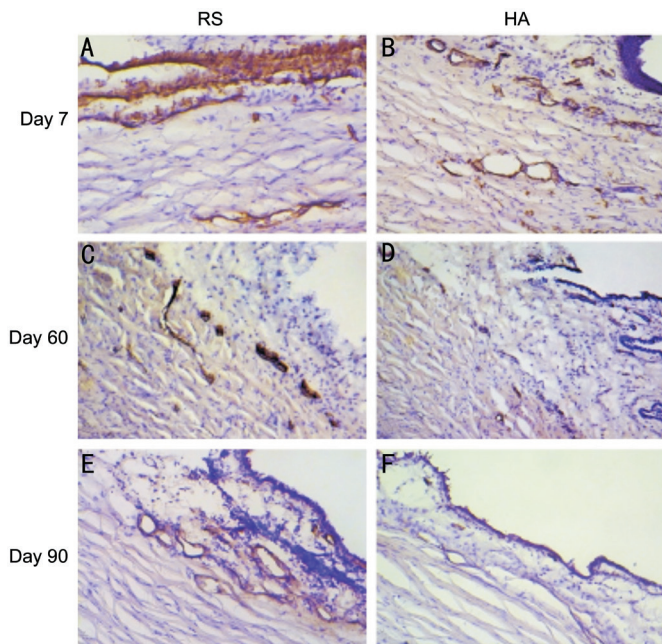


Figure 6 The expression of α -SMA at various times after trabeculectomy A, B: The expression of α -SMA was obvious and α -SMA positive cells were in conjunctiva and superficial sclera diffusely at 7d after the operation; C, D: At 60d after the operation, α -SMA positive cells were mainly distributed at the junction of the conjunctiva and sclera, and gathered around blood vessels; E: 90d after surgery, a small amount of α -SMA positive cells were under the conjunctiva in RS group; F: 90d after surgery, the HA group almost no positive staining. RS: Sodium lactate Ringer's solution group; HA: Sodium hyaluronate group.

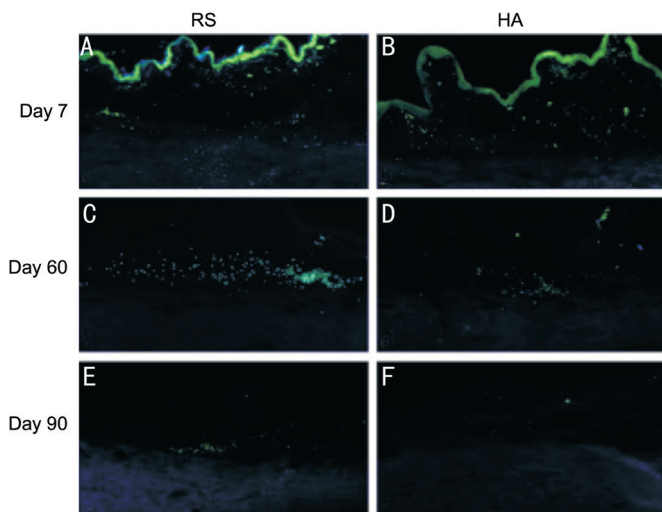


Figure 7 TGF- β expression at various times after trabeculectomy A, B: At 7d postoperatively, TGF- β was expressed in the conjunctiva, sclera and filter channel in both groups; C, D: TGF- β expression is significantly reduced at 60d postoperatively, mainly concentrated in the subconjunctiva; E, F: 90d after surgery, there was almost no TGF- β expression in both groups, and a small amount of positive staining occasionally scattered in the subconjunctiva or deep sclera. RS: Sodium lactate Ringer's solution group; HA: Sodium hyaluronate group.

DISCUSSION

Glaucoma is a type of ophthalmopathy characterized by atrophy and depression of the optic disc, visual field defect, and vision decreased^[1]. Trabeculectomy is currently an important method to reduce IOP and protect visual function. Postoperative filtering bleb scarring is often the primary cause of surgical failure^[9-10]. Previous studies have shown that HA had anti-inflammatory, biocompatibility and biodegradability, and is hopefully to be used to reduce the incidence of filtration channel fibrosis.

It is preliminarily shown that HA has a certain inhibitory effect on the scarring of filtering blebs and is beneficial to maintain the functional morphology of filtering blebs. Meanwhile, it can reduce the incidence of complications, such as anterior chamber hemorrhage and shallow anterior chamber. The results showed that the collagen fibers in the HA group were bent and arranged disorderly, while the collagen fibers in the RS group were dense and tightly arranged. At the same time, the CVF of the RS group was significantly higher than that of the HA group at 60d and 90d after surgery. HA has an inhibitory effect on the deposition of collagen fibers at the filtration channel.

In the process of trabeculectomy wound healing and fibrotic scar formation, fibroblasts in Tenon's capsule are the main cells^[35]. It was found that the α -SMA positive cells were diffusely distributed 7d after the operation, but 90d after the operation, the HA group was almost no positive staining. A small amount of α -SMA positive cells were under the conjunctiva of the RS group. The measurement results of the AOD showed that there was no difference in the two groups at 7d after the operation, while the AOD of the RS group was greater than the HA group at 60 and 90d after the operation, and the difference was statistically significant. The AOD value measured by immunohistochemical staining and the CVF value measured by Masson staining have the same changing trend, suggesting that sodium hyaluronate can inhibit the proliferation and activation of fibroblasts, thereby inhibiting the formation and deposition of collagen fibers.

TGF- β can stimulate the proliferation and migration of human eyeball fascial sac fibroblasts^[36], and play an important role in the process of scar repair after glaucoma trabeculectomy. At 7d postoperatively, TGF- β was significant expression in the conjunctiva, sclera, and filtration channel in both groups. At this time, the AOD value of the RS group was greater than that of the HA group. TGF- β is significantly reduced at 60 and 90d postoperatively. The results show that HA has an inhibitory effect on the expression of TGF- β , which can inhibit the proliferation and migration of fascial capsule fibroblasts, the aggregation of various inflammatory cells, the expression of various growth factors, and the new collagen contraction.

Masson staining shows that the new collagen fibers in the HA group are slender and curved and arranged irregularly.

In conclusion, HA has effect of anti-scar and anti-inflammation on filtration pathway after filtering surgery within 3mo by inhibiting fibroblast proliferation and collagen deposition.

ACKNOWLEDGEMENTS

Foundations: Supported by National Natural Science Foundation of China (No.81974132; No.81770927); National Key R&D Program of China (No.2021YFA1101202); Hunan Provincial Health Commission (No.202207022839).

Conflicts of Interest: Wang YJ, None; Feng LM, None; Zhang C, None; Zhang WL, None; Song WT, None.

REFERENCES

- Jonas JB, Aung T, Bourne RR, Bron AM, Ritch R, Panda-Jonas S. Glaucoma. *Lancet* 2017;390(10108):2183-2193.
- Johnson DH. Clinical Atlas of Glaucoma. *Mayo Clinic Proceedings* 1987;62(3):233-234.
- Schuster AK, Erb C, Hoffmann EM, Dietlein T, Pfeiffer N. The diagnosis and treatment of glaucoma. *Dtsch Arztebl Int* 2020;117(13):225-234.
- He S, Stankowska DL, Ellis DZ, Krishnamoorthy RR, Yorio T. Targets of neuroprotection in glaucoma. *J Ocul Pharmacol Ther* 2018;34(1-2): 85-106.
- Almasieh M, Levin LA. Neuroprotection in glaucoma: animal models and clinical trials. *Annu Rev Vis Sci* 2017;3:91-120.
- Sena DF, Lindsley K. Neuroprotection for treatment of glaucoma in adults. *Cochrane Database Syst Rev* 2013(2):CD006539.
- Perez CI, Singh K, Lin S. Relationship of lifestyle, exercise, and nutrition with glaucoma. *Curr Opin Ophthalmol* 2019;30(2):82-88.
- Edmunds B, Thompson JR, Salmon JF, Wormald RP. The National Survey of Trabeculectomy. III. Early and late complications. *Eye (Lond)* 2002;16(3):297-303.
- Razeghinejad MR, Havens SJ, Katz LJ. Trabeculectomy bleb-associated infections. *Surv Ophthalmol* 2017;62(5):591-610.
- Sugimoto K, Asano-Shimizu K, Murata H, Yamashita T, Asaoka R. Bleb plication for a leaking bleb after trabeculectomy. *J Glaucoma* 2020;29(8):e80-e82.
- Green E, Wilkins M, Bunce C, Wormald R. 5-Fluorouracil for glaucoma surgery. *Cochrane Database Syst Rev* 2014;(2):CD001132.
- Chen CW. Enhanced intraocular pressure controlling effectiveness of trabeculectomy by local application of mitomycin C. *Trans Asia Pac Acad Ophthalmol* 1983;9.
- Fraser S. Trabeculectomy and antimetabolites. *Br J Ophthalmol* 2004;88(7):855-856.
- Gedde SJ, Singh K, Schiffman JC, Feuer WJ; Tube Versus Trabeculectomy Study Group. The tube versus trabeculectomy study: interpretation of results and application to clinical practice. *Curr Opin Ophthalmol* 2012;23(2):118-126.
- Fallacara A, Vertuani S, Panozzo G, Pecorelli A, Valacchi G, Manfredini S. Novel artificial tears containing cross-linked hyaluronic acid: an *in vitro* re-epithelialization study. *Molecules* 2017;22(12):2104.
- Ang BCH, Sng JJ, Wang PXH, Htoon HM, Tong LHT. Sodium hyaluronate in the treatment of dry eye syndrome: a systematic review and meta-analysis. *Sci Rep* 2017;7(1):9013.
- Wang HZ. Expert consensus on compound trabeculectomy in China. *Chinese Journal of Ophthalmology* 2017;53(04):249-251.
- Mohamed YH, Uematsu M, Ueki R, Inoue D, Sasaki H, Kitaoka T. Safety of sodium hyaluronate eye drop with C12-benzalkonium chloride. *Cutan Ocul Toxicol* 2019;38(2):156-160.
- Ángeles GH, Nešporová K. Hyaluronan and its derivatives for ophthalmology: recent advances and future perspectives. *Carbohydr Polym* 2021;259:117697.
- Diekmann H, Fischer D. Glaucoma and optic nerve repair. *Cell Tissue Res* 2013;353(2):327-337.
- Charteris DG, McConnell JM, Adams AD. Effect of sodium hyaluronate on trabeculectomy filtration blebs. *J R Coll Surg Edinb* 1991;36(2):107-108.
- Lopes JF, Moster MR, Wilson RP, Altangerel U, Alvim HS, Tong MG, Fontanarosa J, Steinmann WC. Subconjunctival sodium hyaluronate 2.3% in trabeculectomy: a prospective randomized clinical trial. *Ophthalmology* 2006;113(5):756-760.
- Sakamoto M, Yoshida I, Soden T, Aso K, Hashimoto R, Masahara H, Maeno T. Assessment of the differences in the short-term clinical outcomes of superotemporal and inferonasal Baerveldt glaucoma implantation surgeries performed via the pars plana route. *Guoji Yanke Zazhi(Int Eye Sci)* 2021;21(1):15-20.
- Hangody L, Szody R, Lukasik P, Zgadzaj W, Lénárt E, Dokoupilova E, Bichovsk D, Berta A, Vasarhelyi G, Ficzer A, Hangody G, Stevens G, Szendroi M. Intraarticular injection of a cross-linked sodium hyaluronate combined with triamcinolone hexacetonide (Cingal) to provide symptomatic relief of osteoarthritis of the knee: a randomized, double-blind, placebo-controlled multicenter clinical trial. *Cartilage* 2018;9(3):276-283.
- Batura D, Warden R, Hashemzahi T, Figaszewska MJ. Intravesical sodium hyaluronate reduces severity, frequency and improves quality of life in recurrent UTI. *Int Urol Nephrol* 2020;52(2):219-224.
- Rivera F, Bertignone L, Grandi G, Camisassa R, Comaschi G, Trentini D, Zanone M, Teppex G, Vasario G, Fortina G. Effectiveness of intra-articular injections of sodium hyaluronate-chondroitin sulfate in knee osteoarthritis: a multicenter prospective study. *J Orthop Traumatol* 2016;17(1):27-33.
- Wang X, Dai WW, Dang YL, Hong Y, Zhang C. Five years' outcomes of trabeculectomy with cross-linked sodium hyaluronate gel implantation for Chinese glaucoma patients. *Chin Med J (Engl)* 2018;131(13):1562-1568.
- Chiam PJ, Chen X, Haque MS, Sung VC. Outcome of fixed volume intracameral sodium hyaluronate 1.4% injection for early postoperative hypotony after Baerveldt glaucoma implant. *Clin Exp Ophthalmol* 2018;46(9):1035-1040.
- Mudhol R, Bansal R. Cross-linked hyaluronic acid viscoelastic scleral implant in trabeculectomy. *Indian J Ophthalmol* 2021;69(5):1135-1141.

- 30 Salvo EC Jr, Luntz MH, Medow NB. Use of viscoelastics post-trabeculectomy: a survey of members of the American Glaucoma Society. *Ophthalmic Surg Lasers* 1999;30(4):271-275.
- 31 Alpar JJ. Sodium hyaluronate (Healon) in glaucoma filtering procedures. *Ophthalmic Surg* 1986;17(11):724-730.
- 32 Yin H, Chen X, Hong X, Ma J, Wu F, Wan T, Sang Y, Fu Q, Qin Z, Lyu D, Wu W, Yin J, Yang Y. Effect of SMILE-derived decellularized lenticules as an adhesion barrier in a rabbit model of glaucoma filtration surgery. *BMC Ophthalmol* 2021;21(1):329.
- 33 Kapelushnik N, Leshno A, Singer R, Huna-Baron R, Barkana Y, Skaat A. Er: YAG laser-assisted filtration surgery: initial results in rabbits. *BMC Ophthalmol* 2021;21(1):226.
- 34 Fujimoto T, Nakashima KI, Watanabe-Kitamura F, Watanabe T, Nakamura K, Maki K, Shimazaki A, Kato M, Tanihara H, Inoue T. Intraocular pressure-lowering effects of trabeculectomy versus MicroShunt insertion in rabbit eyes. *Transl Vis Sci Technol* 2021;10(9):9.
- 35 Atreides SP, Skuta GL, Reynolds AC. Wound healing modulation in glaucoma filtering surgery. *Int Ophthalmol Clin* 2004;44(2):61-106.
- 36 Fan J, Shen W, Lee SR, Mathai AE, Zhang R, Xu G, Gillies MC. Targeting the Notch and TGF- β signaling pathways to prevent retinal fibrosis *in vitro* and *in vivo*. *Theranostics* 2020;10(18):7956-7973.