

Immune checkpoint inhibitor-associated ophthalmic adverse events: current understanding of its mechanisms, diagnosis, and management

Yu-Wen Zhou¹, Qian Xu², Yan Wang³, Ruo-Lan Xia¹, Ji-Yan Liu¹, Xue-Lei Ma¹

¹Department of Biotherapy and Cancer Center, West China Hospital, Sichuan University, Chengdu 610041, Sichuan Province, China

²West China Medical Publishers, West China Hospital of Sichuan University, Chengdu 610041, Sichuan Province, China

³Department of Oncology, West China Hospital, the First People's Hospital of Long Quan Yi District, Chengdu 610041, Sichuan Province, China

Co-first authors: Yu-Wen Zhou, Qian Xu, and Yan Wang

Correspondence to: Ji-Yan Liu and Xue-Lei Ma. Department of Biotherapy and Cancer Center, West China Hospital, Sichuan University, 37 Guoxue Xiang Street, Chengdu 610041, Sichuan Province, China. liujiyan1972@163.com; drmaxuelei@gmail.com

Received: 2021-07-15 Accepted: 2021-11-02

Abstract

• Immune checkpoint inhibitors (ICIs) targeting cytotoxic T-lymphocyte antigen 4 and programmed cell death protein 1 receptor/ligand have revolutionized cancer treatment, achieving unprecedented efficacy in numerous malignancies. Despite the excellent therapeutic effects of ICIs, medications, such as pembrolizumab, ipilimumab, nivolumab, atezolizumab, avelumab, and durvalumab, typically cause a broad spectrum of toxicity events termed as immune-related adverse events (irAEs). Out of all irAEs, ophthalmic adverse events occur infrequently and are not comprehensively recognized. The current understanding of ophthalmic irAEs is mainly derived from case reports and case series. In this review, based on relevant articles in the literature and current evidence, we summarize the incidences, manifestations, diagnoses, underlying mechanisms, treatments, and outcomes of ophthalmic irAEs and discuss possible management strategies. A better understanding of these features is critical for managing patients with ICI-associated ophthalmic adverse events.

• **KEYWORDS:** immune checkpoint inhibitor; ophthalmological adverse events; uveitis; neuro-ophthalmic toxicity; retinopathy

DOI:10.18240/ijo.2022.04.19

Citation: Zhou YW, Xu Q, Wang Y, Xia RL, Liu JY, Ma XL. Immune checkpoint inhibitor-associated ophthalmic adverse events: current understanding of its mechanisms, diagnosis, and management. *Int J Ophthalmol* 2022;15(4):646-656

INTRODUCTION

Immune checkpoint inhibitors (ICIs) that target cytotoxic T-lymphocyte antigen 4 (CTLA-4) and programmed cell death protein 1 receptor/ligand (PD-1/PD-L1) pathways have shown robust evidence of antitumor activity in patients with cancer^[1]. These medications include pembrolizumab^[2], ipilimumab^[3], nivolumab^[4-6], atezolizumab^[7], avelumab^[8], and durvalumab^[8] and have been authorized by the Food and Drug Administration (FDA) for numerous cancer therapies^[9]. With the progressive implementation of ICIs in clinical practice, however, a key challenge has emerged: the uncontrolled collateral effects of ICIs on the immune system, which can result immune-related adverse events (irAEs) that can affect all organ systems^[10]. IrAEs comprise common adverse events, such as dermatological, gastrointestinal, hematological, pulmonary, and rheumatic toxicities, nephritis, and endocrinopathy. They also include rare adverse events (arising in <1% of patients), such as neurological, ocular, and cardiac toxicities^[11], which can largely be controlled by glucocorticoid therapy^[12]. Among these toxicities, ophthalmic irAEs, including dry eye, uveitis, ocular myasthenia gravis, uveal effusion, retinal detachment, and conjunctivitis (Figure 1) occur infrequently and are not comprehensively recognized. The current understanding of ophthalmic irAEs is mainly derived from case reports and case series (Table 1)^[13-16]. In this review, to strengthen the understanding of ICI-associated ophthalmic toxicity and enhance the quality of life of patients, we elaborate on the incidences, manifestations, diagnoses, potential mechanisms, treatments, and management of ophthalmic irAEs based on the current knowledge and relevant literature.

POTENTIAL MECHANISM OF OPHTHALMIC TOXICITY

The mechanism of ICI-associated ophthalmic events has yet to be fully understood. The eyes have special mechanisms

Table 1 Published case reports and case series of immune checkpoint inhibitor-associated ophthalmic adverse events

Case reports/ series	Patients	Cancer type	Drugs	Time of onset	Symptoms	Ophthalmologic events	Withdraw the drug	Treatment	The time of recovery	Outcome
Arai <i>et al</i> 2017 ^[13]	55y/M	Melanoma	Nivolumab	2wk after the first infusion	Blurry vision	Acute anterior uveitis with VKH-like eruptions	Yes	Steroid	NR	Improved
Baughman <i>et al</i> 2017 ^[14]	92y/F	Melanoma	Nivolumab	After the third infusion	Bilateral blurred vision	Bilateral uveitis and keratitis	No	Systemic and topical steroid	Within 2wk	Improved
Carrera <i>et al</i> 2017 ^[15]	68y/M	NSCLC	Tremelimumab and durvalumab	4d after the second infusion	Binocular vertical diplopia, ptosis of left upper eyelid	Inflammatory myopathy affecting the extraocular muscles	No	Systemic steroids	1mo	Improved
Conrady <i>et al</i> 2018 ^[16]	57y/M	Melanoma	Pembrolizumab	After 15 infusion	Bilateral, acute vision loss	Uveitis	Yes	Oral steroids	2wk	Improved
Conrady <i>et al</i> 2018 ^[16]	78y/F	Melanoma	Pembrolizumab	Within 1wk	Vision loss, photophobia	Uveitis	No	Systemic steroids	NR	Stable

M: Male; F: Female; NSCLC: Non-small-cell lung cancer; NR: Not reference; VKH: Vogt-Koyanagi-Harada.

to limit the invasion of inflammation and infectious agents, thus protecting visual function^[17-18]. Anatomical mechanisms, such as the presence of the blood-retinal barrier and absence of efferent lymphatic vessels, protect the eyes from infection, whereas immune mechanisms, such as the upregulation of the Fas ligand and tumor growth factor-beta (TGF- β), can prevent inflammation by converting T cells into regulatory T cells and causing immune cell death^[17].

Blockade of these regulatory T cells may trigger adverse reactions^[19], and reprogramming of the cell death pathway may lead to ocular adverse events due to ICI therapy. To further downregulate the inflammatory T-cell activity, retinal pigment epithelial cells express both PD-L1 and CD86, which can interact with PD-1 and CTLA-4, respectively^[18]. High levels of PD-L1 were also found to express in various ocular tissues and may play crucial roles in preventing autoimmunity^[20]. In addition, PD-1 and PD-L2 were expressed on tumor cells of ocular adnexal invasive squamous cell carcinomas to varying degrees; as a consequence, these tumor cells can potentially respond to ICI therapy^[21].

IMMUNE CHECKPOINT INHIBITOR-ASSOCIATED OPHTHALMIC ADVERSE EVENTS

Ophthalmic adverse events have been reported most frequently with ipilimumab, followed by nivolumab and pembrolizumab and subsequently by atezolizumab, avelumab, and durvalumab^[22]. The incidence of ICI-associated ocular side events is <1%^[23]. A total of 15 cases of ocular toxicities were reported in a series of 1474 cases who were treated with nivolumab with or without ipilimumab^[24]. A prospective cohort study recently attempted to explore the relationship between ICIs and ocular adverse events in 745 patients^[25] and observed intraocular inflammation in 5 cases, ocular surface disease in 2 cases, and orbital myopathy in 1 case^[25]. One study has shown that patients receiving ICIs as therapy who developed colitis were also susceptible to episcleritis or uveitis^[26].

Ocular irAEs can occur at any time during treatment, and even after the cessation of ICIs^[10]. However, most (approximately

70%) irAEs typically occur within two months after the initiation of therapy^[22]. A minority of irAEs occurs after 48wk, and these irAEs can involve various parts of the eye and orbit^[23,27]. We reviewed published cases of adverse ophthalmic reactions and found that the time to onset of ophthalmic irAEs was earlier when combined with ICIs (either with other ICIs or other conventional therapies; Figure 2). Apart from the variability of the time to onset, there is variability in the ocular symptoms: the most common clinical manifestation of ICI-related ophthalmic toxicity is dry eyes (3%-24%), uveitis (1%), and myasthenia gravis involved with the eyes (frequency undefined). Other less common ophthalmic adverse events include uveal effusion, retinal detachment, conjunctivitis, ocular myositis, vasculitis, keratitis, episcleritis, vitritis, choroidopathy, and a broad spectrum of neuro-ophthalmic toxicities (Figure 1)^[23,28-31]. Information on various types of ocular adverse events are summarized in Table 2. Most of these adverse reactions can be effectively controlled by periocular, topical, or systemic corticosteroids^[27,32].

Dry Eye Disease Dry eye disease is a presentation that is characterized by tear hyperosmolarity, tear-film instability, ocular surface inflammation, and damage due to reduced tear quantity and/or quality. Dry eye disease associated with ICIs was the first and the most frequently reported ocular surface adverse event with an incidence ranging from 3% to 24%^[33] and presenting with nonspecific eye irritation and as a part of the sicca syndrome^[33-36]. It can also lead to corneal perforation^[34]. ICI-related dry eyes can be effectively managed with topical cyclosporine and artificial tears^[14,37]. One patient had nivolumab-associated corneal graft rejection and did not respond well to systemic or subconjunctival corticosteroids^[20].

Uveitis Uveitis refers to the inflammation of the uvea, a highly vascularized layer between the retina and sclera. Among all ophthalmic toxicities, uveitis is one of the most common adverse reactions. It is associated with anti-CTLA-4 and anti-PD-1/PD-L1 agents, such as ipilimumab, durvalumab, avelumab, pembrolizumab, nivolumab, and atezolizumab.

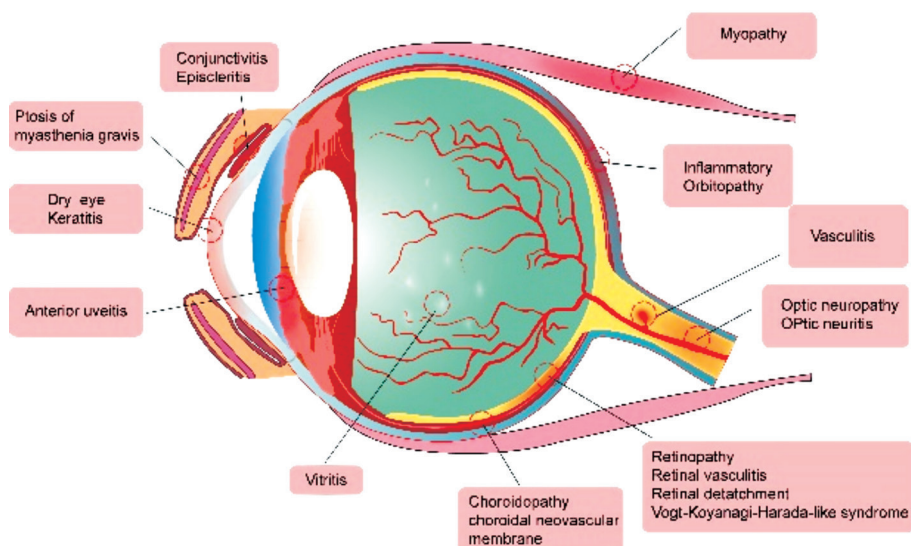


Figure 1 Anatomical diagram of the eye Immune checkpoint inhibitors associated ophthalmic adverse events are indicated based on the affected ocular structure.

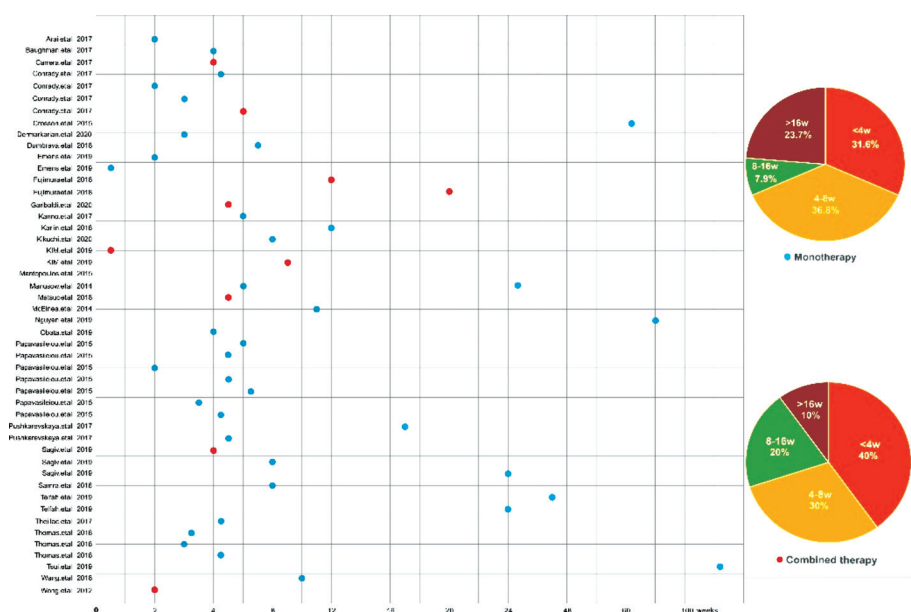


Figure 2 Time to onset of immune checkpoint inhibitors-associated ophthalmic adverse events This figure is built based on the therapy types (monotherapy and combined therapy) of cases. The time when the ICIs-related ophthalmic toxicity occurred is recorded as a dot: the blue dot represents monotherapy and the red dot represents combined therapy. Two pie charts illustrate case percentages of different onset time periods in each group.

Table 2 Information on various types of ocular adverse events

Type of ocular irAEs	Study design	Sample size	Drug employed
Uveitis	Case reports/series	15	Nivolumab/ipilimumab/pembrolizumab/atezolizumab/ipilimumab+nivolumab
Dry eye	Case reports	4	Nivolumab/pembrolizumab
Optic nerve	Case reports	5	Atezolizumab/nivolumab/ipilimumab
VKH-like syndrome	Case reports	8	Nivolumab/ipilimumab
Uveal effusion	Case reports	3	Atezolizumab/nivolumab
Retinal detachment	Case reports	6	Pembrolizumab/atezolizumab/ ipilimumab/nivolumab
Orbital inflammation	Case reports/series	10	Ipilimumab/pembrolizumab/nivolumab/tremelimumab
Inflammatory myopathy	Case reports	4	Tremelimumab+durvalumab/pembrolizumab/ipilimumab
Thyroid eye disease	Case reports	4	Ipilimumab/nivolumab/tremelimumab

irAEs: Immune-related adverse events; VKH: Vogt-Koyanagi-Harada.

There is a lack of data for comparing the incidence, pattern, and occurrence time of uveitis induced by CTLA-4 with PD-1/PD-L1 inhibitors^[38]. Uveitis irAEs can occur in approximately 1% of patients and manifest as anterior-^[39-47], posterior-^[48], or pan-uveitis^[49]. The time to onset after the initial infusion of ICIs ranges broadly from approximately 2wk to 14mo (median time is 9wk). A typical initial chief complaint is conjunctival redness or bilateral blurred vision^[50]. Other symptoms, such as eye pain, photophobia, and floaters are also observed with uveitis^[45]. Nevertheless, the mechanisms of uveitis irAEs have yet to be assessed comprehensively^[23].

Patients with uveitis irAEs can use periocular, topical, or systemic corticosteroids to control inflammation, and intravitreal corticosteroids can be used for treating macular edema^[46,51]. Some severe cases particularly require the cessation of ICI therapy.

Vogt-Koyanagi-Harada (VKH) disease, known as a bilateral diffuse granulomatous uveitis, is diagnosed in patients who receive anti-PD-1 agents^[13]. It presents with blurry vision, xanthopsia, and exudative retinal detachments with bilateral uveitis and is amenable to systemic and occasional topical corticosteroid therapy^[13,52-53].

Orbit and Ocular Adnexa Myasthenia gravis involved with the eye is the most frequently reported adverse event of orbital and ocular adnexa^[54-60]. It can present with blepharoptosis, ocular motility abnormalities, diplopia, or severe systemic symptoms in addition to respiratory distress^[55-60]. These symptoms can be managed with oral/intravenous corticosteroids, intravenous immunoglobulin, pyridostigmine, and plasmapheresis. Severe consequences, such as death from respiratory failure, have also been recorded^[61].

ICI-associated inflammatory orbitopathy is an orbital adverse effect that presents with proptosis, pain, eyelid edema, chemosis, and extraocular motility restriction. One case of orbital myopathy that involved the extraocular muscles was associated with blepharoptosis and dyspnea and required tremelimumab and durvalumab discontinuation and the use of systemic corticosteroids^[15].

Thyroid-like orbitopathy, characterized by ophthalmoplegia due to extraocular muscle involvement and proptosis, may occur in patients treated with ipilimumab even in the absence of thyroid dysfunction^[62-63]. It has been suggested that anti-CTLA-4 agents enhance the activation and proliferation of CD8+ T lymphocytes, facilitating the development of Grave's orbitopathy^[64]. Anti-CTLA-4 in combination with an anti-PD-L1 inhibitor has also shown to be related to Grave's orbitopathy and an inflammatory myopathy of the diplopia, extraocular muscles, ptosis, and weakness^[65-67]. Moreover, inflammatory orbitopathy, orbital inflammatory syndromes, and orbital apex syndrome have been described in several

studies^[68-69]. Systemic corticosteroids can be used to manage these patients^[68,70].

Optic Nerve Neuro-ophthalmic adverse events were first reported in a pediatric patient with grade 4 glioblastoma multiforme in 2018^[71]. It has also been shown to be associated with ipilimumab^[72], but the incidence is very low. Several cases with neurologic adverse events, including optic neuritis, Grave's orbitopathy, papillitis, and myasthenia gravis have been reported to occur at a median onset of 35d after ICI therapy^[73-77]. Papilledema, multiple cranial neuropathies, and cerebellar ataxia with associated nystagmus have also been observed^[78-79]. The manifestations of neuro-ophthalmic adverse events range from mild to severe and present with visual disturbances, including part or full-field vision loss, disc edema, or scotomas^[73,80]. Prompt recognition, treatment, and management are crucial to prevent morbidity^[81]. Most symptoms can be alleviated with corticosteroids, but some severe optic neuropathy requires intravenous immunoglobulin or plasmapheresis^[73]. Of note, severe ophthalmoplegia induced by immunotherapy requires early intervention and treatment because of potentially fatal side events^[82-83].

Retinal Detachment Uveal effusion has been reported in patients treated with anti-PD-1/PD-L1 agents, such as pembrolizumab, nivolumab, and atezolizumab. ICI-associated uveal diffusion usually manifests as symptoms, such as redness, blurry vision, ocular, and serous choroidal detachment including the foveal presence of intraretinal and subretinal fluid^[19]. Although the uveal effusion can also be attributed to intraocular inflammation, ICI-related uveal effusion can resolve after discontinuing the immunotherapy, indicating that ICIs play an important role in causing uveal effusions^[19].

There are isolated reports of serous retinal detachment with or without choroidopathy^[84-85], immune retinopathy^[30], exudative retinal detachment with ciliochoroidal effusion^[86], and melanoma-associated retinopathy with atypical chorioretinal lesions^[87] leading to photophobia and blurry vision that have been treated with variable therapies, including topical and oral corticosteroids, discontinuation of ICIs, or observation alone^[86]. Early cessation of checkpoint inhibitors has favorable visual acuity outcomes^[84].

Conjunctivitis Conjunctivitis in patients treated by ICIs is rarely reported, and the incidence and time to onset varies by patient. In one case study, the patient complained of irritated red eyes without the impairment of vision after 13 doses of nivolumab^[29]. Conjunctiva swab test was negative, and symptoms were not relieved after antibiotic ocular drop treatment. The ophthalmologist's examination revealed bilateral sterile conjunctivitis with no signs of retinal or uveitis lesions. The manifestation was partially improved after topical steroid therapy. Two cases of conjunctivitis have been

reported in a retrospective study, presenting with irritation and conjunctival injection; however, neither required ICI discontinuation^[39,49]. One case improved after treatment with topical corticosteroids^[39].

Other Diseases Ocular myositis was reported in a case with metastatic renal carcinoma. Symptoms such as a subacute presentation of bilateral eyelid ptosis and painless ophthalmoplegia were observed after the second infusion of pembrolizumab. A mild elevation of TSH and CK was found in laboratory tests. A physical examination indicated complete, non-fluctuating, external ophthalmoplegia with bilateral eyelid ptosis^[88]. Deltoid muscle biopsy demonstrated mixed macrophagic/lymphocytic endomysial inflammatory infiltration, with prevalent CD68 and CD8 cells, sometimes expressing PD-1/PD-L1 antigens. 94 MHC-I overexpression in the cytoplasm and sarcolemma was observed in non-necrotic cell clusters. In perifascicular regions, CD56+ cells were also observed. After starting corticosteroid therapy and discontinuing pembrolizumab, the patient's symptoms were relieved and the laboratory tests normalized^[88].

Retinal vasculitis resulting in blurry vision secondary to pembrolizumab has been reported in the setting of metastatic cutaneous melanoma to the vitreous cavity. One patient complained of blurred vision and was treated with prednisolone eye drops. Pembrolizumab was continued, and the tumor lesion achieved complete response after 15 cycles of treatment. The ocular presentation improved after external beam radiotherapy and vitrectomy for the vitreous metastases^[89].

The granulomatous inflammation of lacrimal glands has been rarely reported^[90-91]. The pathogenesis of granulomatous infiltration in the context of ICIs may be attributed to IL-2 secretion by activated T cells and lymphocytic infiltration with CD8+ T cells^[92]. One patient with simultaneous and bilateral keratitis and uveitis in the setting of nivolumab therapy for metastatic melanoma was presented in a case report. The patient presented with bilateral blurred vision after the third dose of nivolumab. Other keratitis types mainly present with corneal haze and pain and can be managed with topical corticosteroids^[14]. Episcleritis induced by ipilimumab was also reported in clinical trials; however, details on therapy and outcomes were not given^[93].

DIAGNOSING IMMUNE CHECKPOINT INHIBITOR-ASSOCIATED OPHTHALMIC TOXICITY

Patients with ophthalmic irAEs require thorough ophthalmologic tests that can assess the presence of ophthalmologic, fundus, neurologic, and systemic disease (Figure 3). Ophthalmic evaluation is the most common form of diagnosis; nearly all patients with ICI-associated ophthalmic toxicity were identified in this manner^[94-95] (Figure 3). Patients with ICI-related ophthalmic toxicity accompanying with fever and flu-

like symptoms were recommended treatment with antinuclear antibody during the periods of adverse events^[94]. Of note, antinuclear antibody usually has good sensitivity but poor specificity for autoimmune disease. The antinuclear antibody evaluation, either using absolute values or changes from baseline, is required to better understand the diagnostic and predictive value in cases with ocular immune-associated adverse reactions^[96].

The examination of neuro-ophthalmic events may be accompanied by a series of imaging studies and ancillary laboratories based on medical history and examination findings, including infectious and autoimmune serologies, MRI, optical coherence tomography (OCT), and cerebrospinal fluid (CSF) examination^[97]. Orbital and cerebral MRI may provide ophthalmologist with valuable diagnostic and prognostic information^[98].

A significant reduction in the visual acuity associated with a nonpainful redness in both eyes was found in ophthalmologic evaluation^[28]. Slit-lamp examination revealed the presence of anterior chamber cells of strong positive, bilateral granulomatous keratic precipitates, bilateral anterior, and posterior synechiae and some pigmentary deposits on the anterior lens capsule that were predominant in the left eye. Fluorescein angiography confirmed unilateral or bilateral papilledema. A light macular edema associated with a subfoveal serous retinal detachment can be revealed *via* OCT^[28].

A wide spectrum of ocular manifestations should be included in the differential diagnosis by ophthalmologists to prevent irreversible vision loss and mortality^[82-83]. It is worth mentioning that melanoma-associated retinopathy, a rare autoimmune disease, has been shown to be associated with the diagnosis of cutaneous melanoma^[99]. It is characterized by various optic disc findings and the presence of antiretinal antibodies. Melanoma-associated retinopathy presents with several forms of chronic visual impairments, which usually develop several months after the diagnosis of melanoma^[33,38]. Melanoma-associated retinopathy occurs with the melanoma diagnosis, regardless of the therapy, and is therefore easily distinguished from ICI-associated ocular toxicity^[87].

TREATMENT AND OUTCOME OF ICI-ASSOCIATED OPHTHALMIC EVENTS

The treatment regimens for ophthalmic irAEs vary depending on the case. Recently, detailed recommendations for the treatment of ICI-induced ophthalmic adverse events have been proposed. For patients with moderate adverse events (CTCAE grade 2, such as those involving the anterior segment), ICIs should be suspended until the symptoms reduce to grade 1 or normalize; corticosteroids may be administered. For patients with severe adverse events (grade 3 or 4, such as those involving the posterior segment), systemic corticosteroids

Case Report/Series	Auto-Antibody	Ophthalmic evaluation	Fundus examination	Slitlamp examination	Anterior chamber	Fundoscopy examination	OCT	Fluorescein angiography	MRI	HLA-DRB1
Arai et al 2017										
Baughman et al 2017										
Carrera et al 2017										
Conrady et al 2017										
Conrady et al 2017										
Conrady et al 2017										
Conrady et al 2017										
Conrady et al 2017										
Conrady et al 2017										
Crosson et al 2015										
Dermarkarian et al 2020										
Dumbrava et al 2018										
Emens et al 2019										
Emens et al 2019										
Fujimura et al 2018										
Fujimura et al 2018										
Garibaldi et al 2020										
Kanno et al 2017										
Karlin et al 2018										
Kikuchi et al 2020										
KIM et al 2019										
KIM et al 2019										
Mantopoulos et al 2015										
Manusow et al 2014										
Matsuo et al 2018										
McInnea et al 2014										
Nguyen et al 2019										
Obata et al 2019										
Papavasileiou et al 2015										
Papavasileiou et al 2015										
Papavasileiou et al 2015										
Papavasileiou et al 2015										
Papavasileiou et al 2015										
Papavasileiou et al 2015										
Papavasileiou et al 2015										
Pushkarevskaya et al 2017										
Pushkarevskaya et al 2017										
Roberts et al 2016										
Sagiv et al 2019										
Sagiv et al 2019										
Sagiv et al 2019										
Samra et al 2016										
Seamone et al 2016										
Telfah et al 2019										
Telfah et al 2019										
Theillac et al 2017										
Thomas et al 2018										
Thomas et al 2018										
Thomas et al 2018										
Tsui et al 2019										
Wang et al 2018										
Wong et al 2012										

Figure 3 Summarized a variety of diagnostic results in published cases reports/case series Diagnostic approaches include autoantibody, ophthalmic evaluation, fundus examination, slit lamp examination, anterior chamber, fundoscopic examination, optical coherence tomography, fluorescein angiography and MRI. Green blocks mean no examinations performed in cases; Yellow blocks represent the negative results; Red blocks represents the positive results.

should be administered. Large doses and long periods of corticosteroids should be avoided because of multiple adverse events that result from it^[100].

In addition to being considered as a drug-associated toxicity, some ophthalmic toxicities, such as uveitis, may serve as a prognostic marker of response to ICIs. Attia *et al*^[101] reported a series of 56 metastatic melanoma patients treated with ipilimumab and found that autoimmunity correlated with the regression of tumor. Among those with severe irAEs, 36% had objective tumor regression compared with 5% of those without irAEs. There was also a report in which one patient developed severe ophthalmic adverse event during treatment with ipilimumab; however, the patient sustained tumor remission^[37]. Of the 15 reviewed cases, tumor regression upon manifestation of uveitis was described in 7 cases in which either a complete or partial response was obtained^[50]. There was a report of a case who was treated with pembrolizumab and soon developed symptoms, including blurred vision, hearing loss, and acute onset ataxia. Simultaneously, a robust regression of metastases

was also detected^[56]. Some severe adverse events of panuveitis, such as a VVKH syndrome induced by ipilimumab, requiring high-dose oral corticosteroids have also been reported^[53]. The sequential administration of nivolumab-associated VKH disease has been reported with a positive clinical outcome^[22].

The above evidence suggested that ICI-associated ophthalmic toxicity may be a potential marker for tumor response. As a result, the administration of corticosteroids requires careful consideration, because of possible compromise of antitumor activities of ICIs. Of note, some patients can also achieve a significant reduction of tumor burden through the symptomatic treatment for ocular adverse effects^[102].

POSSIBLE MANAGEMENT OF OPHTHALMIC ENVENTS AND FUTURE DIRECTIONS

Effective communication with a multidisciplinary team and primary care provider is essential for the prompt recognition and management of ICI-related ophthalmic events. In the era of anticancer immunotherapies, first, it is of great importance

for clinicians to distinguish ICI-related events from potential autoimmune-associated causes and common toxic adverse events. Second, it is vital that ophthalmologists do not mistake uveitis-like manifestations as purely inflammatory. The eye is an immune-privileged organ; even in the setting of an otherwise complete systemic response to therapy, it may be vulnerable to metastases^[89,103]. Two published case reports described cutaneous melanoma metastatic to the vitreous cavity and retina in patients treated with ICIs. These studies elucidated how such manifestations can be confused with inflammatory uveitis but require different management and may have an important impact on prognosis^[89,103]. Third, in the context of a diagnostic dilemma, eliciting a history of systemic irAEs and understanding ophthalmic irAEs that are rarely isolated are critical.

In general, most ophthalmic toxicities can initially be managed by periocular, topical, or systemic corticosteroids. In practice, when the ocular inflammation is mild or only covers the anterior segment, ICI discontinuation might not be required^[50]. Of course, the evaluation for the cessation or discontinuation of treatment will vary on a case-by-case basis depending on the severity and availability of ophthalmologic treatment. In severe or steroid-refractory cases, in which the symptoms are debilitating, it is necessary for ophthalmologists to consult with oncologists in determining the benefits and risk of cessation or continuation of ICIs^[100]. Immunotherapy discontinuation resulting in the spontaneous resolution of symptoms has rarely been reported^[104]. Steroids are required for most patients to alleviate the duration and intensity of symptoms. Alternative immunomodulatory therapies, such as intravenous immunoglobulin or plasma exchange, may offer additional benefits for patients with severe ophthalmologic events^[105].

It is controversial whether ICIs should be re-introduced after recovery from ophthalmic toxicity. Although ophthalmic dysfunction can be significantly improved by corticosteroid therapy, an anti-PD1 agent re-challenge might induce symptom recurrence and even aggravate immune-related toxicities^[106]. In particular, the re-challenge of ICIs after a grade 3 toxicity requires extreme precaution. These recommendations may include some specific genres, such as uveitis, episcleritis, and blepharitis, but do not address other possible ocular presentations. It is important to be aware of the recurrence of adverse events after the re-introduction of ICIs. The management of the recurrence of ophthalmic toxicity is also challenging. As a result, the collaboration of clinical oncologists and ophthalmologists should give careful consideration to patients according to their presentations, outcomes, and alternative cancer therapy options to weigh the pros and cons of reintroducing immunotherapy.

CONCLUSION

ICIs, either alone or in combination with other therapies, can lead to ophthalmic adverse reactions, such as dry eyes, uveitis, ocular myasthenia gravis, uveal effusion, retinal detachment, conjunctivitis, ocular myositis, vasculitis, keratitis, episcleritis, and a wide spectrum of neuro-ophthalmic toxicities. Of all ICI-related ophthalmic events, dry eyes and uveitis are the most common ophthalmic adverse reactions. Although the incidence of ophthalmic toxicities induced by ICIs remains relatively low, oncologists and ophthalmologists must be vigilant for these adverse reactions because permanent damage and blindness can result from neglect. The time to onset and clinical presentations of ophthalmic irAEs are variable. They can occur at any time during treatment, including after the cessation of ICIs with nonspecific symptoms ranging from blurred vision, painless ophthalmoplegia, diplopia, eyelid swelling, eye redness, floaters, exophthalmos, vision loss to shaped scotoma, headaches, and auditory changes. The assessment of ophthalmic evaluation in combination with autoimmune serologies, OCT, CSF, fundus examination, slit-lamp examination, fluorescein angiography, MRI, and biopsy, if necessary, contribute to the diagnosis of ICI-related ophthalmic adverse reactions. Among these diagnostic methods, ophthalmic evaluation is easily performed and has widespread availability. Before the initiation of ICIs, a comprehensive assessment of ophthalmic risk factors and a detailed ophthalmic history should be obtained, particularly for patients with autoimmune disease or pre-existing ophthalmic disease and in the context of ICIs combined with other regimens. For patients with confirmed ophthalmic events, most ophthalmic toxicities can initially be managed by periocular, topical or systemic corticosteroids. In severe or steroid-refractory cases, alternative immunomodulatory therapies, such as intravenous immunoglobulin or plasma exchange, might offer additional benefits. Ophthalmologists need to discuss with oncologists to determine the benefits and risks of discontinuing ICIs. Of note, ICI-associated ophthalmic events may be a potential positive marker for tumor response. In addition, ophthalmic function re-assessments and frequent monitoring are necessary. To better understand these events and provide effective therapy strategies, larger studies are needed.

ACKNOWLEDGEMENTS

Conflicts of Interest: Zhou YW, None; Xu Q, None; Wang Y, None; Xia RL, None; Liu JY, None; Ma XL, None.

REFERENCES

- 1 Esfahani K, Elkrief A, Calabrese C, Lapointe R, Hudson M, Routy B, Miller WH Jr, Calabrese L. Moving towards personalized treatments of immune-related adverse events. *Nat Rev Clin Oncol* 2020;17(8):504-515.
- 2 Larkins E, Blumenthal GM, Yuan WS, He K, Sridhara R, Subramaniam S, Zhao H, Liu C, Yu JY, Goldberg KB, McKee AE, Keegan P, Pazdur

- R. FDA approval summary: pembrolizumab for the treatment of recurrent or metastatic head and neck squamous cell carcinoma with disease progression on or after platinum-containing chemotherapy. *Oncologist* 2017;22(7):873-878.
- 3 Chae YK, Arya A, Iams W, Cruz MR, Chandra S, Choi J, Giles F. Current landscape and future of dual anti-CTLA4 and PD-1/PD-L1 blockade immunotherapy in cancer; lessons learned from clinical trials with melanoma and non-small cell lung cancer (NSCLC). *J Immunother Cancer* 2018;6(1):39.
- 4 Beaver JA, Theoret MR, Mushti S, He K, Libeg M, Goldberg K, Sridhara R, McKee AE, Keegan P, Pazdur R. FDA approval of nivolumab for the first-line treatment of patients with BRAF V600 wild-type unresectable or metastatic melanoma. *Clin Cancer Res* 2017;23(14):3479-3483.
- 5 Hazarika M, Chuk MK, Theoret MR, et al. U.S. FDA approval summary: nivolumab for treatment of unresectable or metastatic melanoma following progression on ipilimumab. *Clin Cancer Res* 2017;23(14):3484-3488.
- 6 Nivolumab gets FDA nod for bladder cancer. *Cancer Discov* 2017;7(4):OF7.
- 7 Narayan P, Wahby S, Gao JJ, et al. FDA approval summary: atezolizumab plus paclitaxel protein-bound for the treatment of patients with advanced or metastatic TNBC whose tumors express PD-L1. *Clin Cancer Res* 2020;26(10):2284-2289.
- 8 Three drugs approved for urothelial carcinoma by FDA. *Cancer Discov* 2017;7(7):659-660.
- 9 Hargadon KM, Johnson CE, Williams CJ. Immune checkpoint blockade therapy for cancer: an overview of FDA-approved immune checkpoint inhibitors. *Int Immunopharmacol* 2018;62:29-39.
- 10 Postow MA, Sidlow R, Hellmann MD. Immune-related adverse events associated with immune checkpoint blockade. *N Engl J Med* 2018;378(2):158-168.
- 11 Johnson DB, Chandra S, Sosman JA. Immune checkpoint inhibitor toxicity in 2018. *JAMA* 2018;320(16):1702-1703.
- 12 Ramos-Casals M, Brahmer JR, Callahan MK, Flores-Chávez A, Keegan N, Khamashta MA, Lambotte O, Mariette X, Prat A, Suárez-Almazor ME. Immune-related adverse events of checkpoint inhibitors. *Nat Rev Dis Primers* 2020;6(1):38.
- 13 Arai T, Harada K, Usui Y, Irisawa R, Tsuboi R. Case of acute anterior uveitis and Vogt-Koyanagi-Harada syndrome-like eruptions induced by nivolumab in a melanoma patient. *J Dermatol* 2017;44(8):975-976.
- 14 Baughman DM, Lee CS, Snysman BE, Jung HC. Bilateral uveitis and keratitis following nivolumab treatment for metastatic melanoma. *Med Case Rep (Wilmington)* 2017;3(2):8.
- 15 Carrera W, Baartman BJ, Kosmorsky G. A case report of drug-induced myopathy involving extraocular muscles after combination therapy with tremelimumab and durvalumab for non-small cell lung cancer. *Neuroophthalmology* 2017;41(3):140-143.
- 16 Conrady CD, Larochele M, Pecan P, Palestine A, Shakoor A, Singh A. Checkpoint inhibitor-induced uveitis: a case series. *Graefes Arch Clin Exp Ophthalmol* 2018;256(1):187-191.
- 17 de Andrade FA, Fiorot SHS, Benchimol EI, Provenzano J, Martins VJ, Levy RA. The autoimmune diseases of the eyes. *Autoimmun Rev* 2016;15(3):258-271.
- 18 Zhou R, Caspi RR. Ocular immune privilege. *F1000 Biol Rep* 2010;2:3.
- 19 Thomas M, Armenti ST, Ayres MB, Demirci H. Uveal effusion after immune checkpoint inhibitor therapy. *JAMA Ophthalmol* 2018;136(5):553-556.
- 20 le Fournis S, Gohier P, Urban T, Jeanfaivre T, Hureauux J. Corneal graft rejection in a patient treated with nivolumab for primary lung cancer. *Lung Cancer* 2016;102:28-29.
- 21 Wolkow N, Jakobiec FA, Afrogheh AH, Eagle RC Jr, Pai SI, Faquin WC. Programmed cell death 1 ligand 1 and programmed cell death 1 ligand 2 are expressed in conjunctival invasive squamous cell carcinoma: therapeutic implications. *Am J Ophthalmol* 2019;200:226-241.
- 22 Dalvin LA, Shields CL, Orloff M, Sato T, Shields JA. Checkpoint inhibitor immune therapy: systemic indications and ophthalmic side effects. *Retina* 2018;38(6):1063-1078.
- 23 Antoun J, Titah C, Cochereau I. Ocular and orbital side-effects of checkpoint inhibitors: a review article. *Curr Opin Oncol* 2016;28(4):288-294.
- 24 Kim JM, Materin MA, Sznol M, Kluger HM, Weiss S, Chow J, Stoessel K, Kombo N, del Priore L, Pointdujour-Lim R. Ophthalmic immune-related adverse events of immunotherapy: a single-site case series. *Ophthalmology* 2019;126(7):1058-1062.
- 25 Bitton K, Michot JM, Barreau E, Lambotte O, Haigh O, Marabelle A, Voisin AL, Mateus C, Rémond AL, Couret C, Champiat S, Labetoulle M, Rousseau A. Prevalence and clinical patterns of ocular complications associated with anti-PD-1/PD-L1 anticancer immunotherapy. *Am J Ophthalmol* 2019;202:109-117.
- 26 Della Vittoria Scarpato G, Fuscillo C, Perri F, Sabbatino F, Ferrone S, Carlomagno C, Pepe S. Ipilimumab in the treatment of metastatic melanoma: management of adverse events. *Onco Targets Ther* 2014;7:203-209.
- 27 Abdel-Rahman O, Oweira H, Petrusch U, Helbling D, Schmidt J, Mannhart M, Mehrabi A, Schöb O, Giryas A. Immune-related ocular toxicities in solid tumor patients treated with immune checkpoint inhibitors: a systematic review. *Expert Rev Anticancer Ther* 2017;17(4):387-394.
- 28 Theillac C, Straub M, Breton AL, Thomas L, Dalle S. Bilateral uveitis and macular edema induced by Nivolumab: a case report. *BMC Ophthalmol* 2017;17(1):227.
- 29 Horisberger A, la Rosa S, Zurcher JP, Zimmermann S, Spertini F, Coukos G, Obeid M. A severe case of refractory esophageal stenosis induced by nivolumab and responding to tocilizumab therapy. *J Immunother Cancer* 2018;6(1):156.
- 30 Reddy M, Chen JJ, Kalevar A, Terribilini R, Agarwal A. Immune retinopathy associated with nivolumab administration for metastatic non-small cell lung cancer. *Retin Cases Brief Rep* 2020;14(2):120-126.

- 31 Watanabe R, Zhang H, Berry G, Goronzy JJ, Weyand CM. Immune checkpoint dysfunction in large and medium vessel vasculitis. *Am J Physiol Heart Circ Physiol* 2017;312(5):H1052-H1059.
- 32 Davis ME, Francis JH. Cancer Therapy with checkpoint inhibitors: establishing a role for ophthalmology. *Semin Oncol Nurs* 2017;33(4):415-424.
- 33 Cappelli LC, Gutierrez AK, Bingham CO 3rd, Shah AA. Rheumatic and musculoskeletal immune-related adverse events due to immune checkpoint inhibitors: a systematic review of the literature. *Arthritis Care Res (Hoboken)* 2017;69(11):1751-1763.
- 34 Nguyen AT, Elia M, Materin MA, Sznol M, Chow J. Cyclosporine for dry eye associated with nivolumab: a case progressing to corneal perforation. *Cornea* 2016;35(3):399-401.
- 35 Hodi FS, Lawrence D, Lezcano C, Wu XQ, Zhou J, Sasada T, Zeng WY, Giobbie-Hurder A, Atkins MB, Ibrahim N, Friedlander P, Flaherty KT, Murphy GF, Rodig S, Velazquez EF, Mihm MC, Russell S, DiPiro PJ, Yap JT, Ramaiya N, van den Abbeele AD, Gargano M, McDermott D. Bevacizumab plus ipilimumab in patients with metastatic melanoma. *Cancer Immunol Res* 2014;2(7):632-642.
- 36 Cappelli LC, Gutierrez AK, Baer AN, Albayda J, Manno RL, Haque U, Lipson EJ, Bleich KB, Shah AA, Naidoo J, Brahmer JR, Le D, Bingham CO 3rd. Inflammatory arthritis and sicca syndrome induced by nivolumab and ipilimumab. *Ann Rheum Dis* 2017;76(1):43-50.
- 37 Papavasileiou E, Prasad S, Freitag SK, Sobrin L, Lobo AM. Ipilimumab-induced ocular and orbital inflammation—A case series and review of the literature. *Ocul Immunol Inflamm* 2016;24(2):140-146.
- 38 Fang T, Maberley DA, Etmnan M. Ocular adverse events with immune checkpoint inhibitors. *J Curr Ophthalmol* 2019;31(3):319-322.
- 39 Zimmer L, Goldinger SM, Hofmann L, et al. Neurological, respiratory, musculoskeletal, cardiac and ocular side-effects of anti-PD-1 therapy. *Eur J Cancer* 2016;60:210-225.
- 40 Kiratli H, Mocan MC, İrkeç M. *In vivo* confocal microscopy in differentiating ipilimumab-induced anterior uveitis from metastatic uveal melanoma. *Case Rep Ophthalmol* 2016;7(3):126-131.
- 41 Miserocchi E, Cimminiello C, Mazzola M, Russo V, Modorati GM. New-onset uveitis during CTLA-4 blockade therapy with ipilimumab in metastatic melanoma patient. *Can J Ophthalmol* 2015;50(1):e2-e4.
- 42 Crosson JN, Laird PW, Debiec M, Bergstrom CS, Lawson DH, Yeh S. Vogt-koyanagi-harada-like syndrome after CTLA-4 inhibition with ipilimumab for metastatic melanoma. *J Immunother* 2015;38(2):80-84.
- 43 Basiliou A, Lloyd JC. Posterior subcapsular cataracts and hypotony secondary to severe pembrolizumab induced uveitis: case report. *Can J Ophthalmol* 2016;51(1):e4-e6.
- 44 Karlin J, Gentzler R, Golen J. Bilateral anterior uveitis associated with nivolumab therapy. *Ocul Immunol Inflamm* 2018;26(2):283-285.
- 45 Kanno H, Ishida K, Yamada W, Nishida T, Takahashi N, Mochizuki K, Mizuno Y, Matsuyama K, Takahashi T, Seishima M. Uveitis induced by programmed cell death protein 1 inhibitor therapy with nivolumab in metastatic melanoma patient. *J Infect Chemother* 2017;23(11):774-777.
- 46 Richardson DR, Ellis B, Mehmi I, Leys M. Bilateral uveitis associated with nivolumab therapy for metastatic melanoma: a case report. *Int J Ophthalmol* 2017;10(7):1183-1186.
- 47 Robinson MR, Chan CC, Yang JC, Rubin BI, Gracia GJ, Sen HN, Csaky KG, Rosenberg SA. Cytotoxic T lymphocyte-associated antigen 4 blockade in patients with metastatic melanoma: a new cause of uveitis. *J Immunother* 2004;27(6):478-479.
- 48 Aaberg MT, Aaberg TM Jr. Pembrolizumab administration associated with posterior uveitis. *Retin Cases Brief Rep* 2017;11(4):348-351.
- 49 Moorthy RS, Moorthy MS, Cunningham ET Jr. Drug-induced uveitis. *Curr Opin Ophthalmol* 2018;29(6):588-603.
- 50 Wang W, Lam WC, Chen L. Recurrent grade 4 panuveitis with serous retinal detachment related to nivolumab treatment in a patient with metastatic renal cell carcinoma. *Cancer Immunol Immunother* 2019;68(1):85-95.
- 51 de Velasco G, Bermas B, Choueiri TK. Autoimmune arthropathy and uveitis as complications of programmed death 1 inhibitor treatment. *Arthritis Rheumatol* 2016;68(2):556-557.
- 52 Matsuo T, Yamasaki O. Vogt-Koyanagi-Harada disease-like posterior uveitis in the course of nivolumab (anti-PD-1 antibody), interposed by vemurafenib (BRAF inhibitor), for metastatic cutaneous malignant melanoma. *Clin Case Rep* 2017;5(5):694-700.
- 53 Wong RK, Lee JK, Huang JJ. Bilateral drug (ipilimumab)-induced vitritis, choroiditis, and serous retinal detachments suggestive of vogt-koyanagi-harada syndrome. *Retin Cases Brief Rep* 2012;6(4):423-426.
- 54 Montes V, Sousa S, Pita F, Guerreiro R, Carmona C. Myasthenia gravis induced by ipilimumab in a patient with metastatic melanoma. *Front Neurol* 2018;9:150.
- 55 Loochtan AI, Nickolich MS, Hobson-Webb LD. Myasthenia gravis associated with ipilimumab and nivolumab in the treatment of small cell lung cancer. *Muscle Nerve* 2015;52(2):307-308.
- 56 Kimura T, Fukushima S, Miyashita A, Aoi J, Jinnin M, Kosaka T, Ando Y, Matsukawa M, Inoue H, Kiyotani K, Park JH, Nakamura Y, Ihn H. Myasthenic crisis and polymyositis induced by one dose of nivolumab. *Cancer Sci* 2016;107(7):1055-1058.
- 57 Johnson DB, Saranga-Perry V, Lavin PJM, Burnette WB, Clark SW, Uskavitch DR, Wallace DE, Dickson MA, Kudchadkar RR, Sosman JA. Myasthenia gravis induced by ipilimumab in patients with metastatic melanoma. *J Clin Oncol* 2015;33(33):e122-e124.
- 58 Hasegawa Y, Kawai S, Ota T, Tsukuda H, Fukuoka M. Myasthenia gravis induced by nivolumab in patients with non-small-cell lung cancer: a case report and literature review. *Immunotherapy* 2017;9(9):701-707.
- 59 Gonzalez NL, Puwanant A, Lu A, Marks SM, Živković SA. Myasthenia triggered by immune checkpoint inhibitors: new case and literature review. *Neuromuscul Disord* 2017;27(3):266-268.
- 60 Chang E, Sabichi AL, Sada YH. Myasthenia gravis after nivolumab therapy for squamous cell carcinoma of the bladder. *J Immunother* 2017;40(3):114-116.

- 61 Makariou D, Horwood K, Coward JIG. Myasthenia gravis: an emerging toxicity of immune checkpoint inhibitors. *Eur J Cancer* 2017;82:128-136.
- 62 McElnea E, Mhéalóid AN, Moran S, Kelly R, Fulcher T. Thyroid-like ophthalmopathy in a euthyroid patient receiving Ipilimumab. *Orbit* 2014;33(6):424-427.
- 63 Min L, Vaidya A, Becker C. Thyroid autoimmunity and ophthalmopathy related to melanoma biological therapy. *Eur J Endocrinol* 2011;164(2):303-307.
- 64 Borodic G, Hinkle DM, Cia YH. Drug-induced Graves disease from CTLA-4 receptor suppression. *Ophthalmic Plast Reconstr Surg* 2011;27(4):e87-e88.
- 65 Gan EH, Mitchell AL, Plummer R, Pearce S, Perros P. Tremelimumab-induced Graves hyperthyroidism. *Eur Thyroid J* 2017;6(3):167-170.
- 66 Sabini E, Sframeli A, Marinò M. A case of drug-induced Graves' orbitopathy after combination therapy with tremelimumab and durvalumab. *J Endocrinol Invest* 2018;41(7):877-878.
- 67 Antonia S, Goldberg SB, Balmanoukian A, Chaft JE, Sanborn RE, Gupta A, Narwal R, Steele K, Gu Y, Karakunnel JJ, Rizvi NA. Safety and antitumour activity of durvalumab plus tremelimumab in non-small cell lung cancer: a multicentre, phase 1b study. *Lancet Oncol* 2016;17(3):299-308.
- 68 Henderson AD, Thomas DA. A case report of orbital inflammatory syndrome secondary to ipilimumab. *Ophthalmic Plast Reconstr Surg* 2015;31(3):e68-e70.
- 69 Hassanzadeh B, DeSanto J, Kattah JC. Ipilimumab-induced adenohypophysitis and orbital apex syndrome: importance of early diagnosis and management. *Neuroophthalmology* 2017;42(3):176-181.
- 70 Sheldon CA, Kharlip J, Tamhankar MA. Inflammatory orbitopathy associated with ipilimumab. *Ophthalmic Plast Reconstr Surg* 2017;33(3S Suppl 1):S155-S158.
- 71 Kartal Ö, Ataş EM. Bilateral optic neuritis secondary to nivolumab therapy: a case report. *Medicina (Kaunas)* 2018;54(5):82.
- 72 Yeh OL, Francis CE. Ipilimumab-associated bilateral optic neuropathy. *J Neuroophthalmol* 2015;35(2):144-147.
- 73 Wilson MA, Guld K, Galetta S, Walsh RD, Kharlip J, Tamhankar M, McGettigan S, Schuchter LM, Fecher LA. Acute visual loss after ipilimumab treatment for metastatic melanoma. *J Immunother Cancer* 2016;4:66.
- 74 Harrison RA, Tummala S, de Groot J. Neurologic toxicities of cancer immunotherapies: a review. *Curr Neurol Neurosci Rep* 2020;20(7):27.
- 75 Park ESY, Rabinowits G, Hamnvik OR, Dagi LR. A case of Graves' ophthalmopathy associated with pembrolizumab (Keytruda) therapy. *J AAPOS* 2018;22(4):310-312.
- 76 Sun MM, Levinson RD, Filipowicz A, Anesi S, Kaplan HJ, Wang W, Goldstein DA, Gangaputra S, Swan RT, Sen HN, Gordon LK. Uveitis in patients treated with CTLA-4 and PD-1 checkpoint blockade inhibition. *Ocular Immunol Inflamm* 2020;28(2):217-227.
- 77 Micaily I, Chernoff M. An unknown reaction to pembrolizumab: giant cell arteritis. *Ann Oncol* 2017;28(10):2621-2622.
- 78 Kawamura R, Nagata E, Mukai M, Ohnuki Y, Matsuzaki T, Ohiwa K, Nakagawa T, Kohno M, Masuda R, Iwazaki M, Takizawa S. Acute cerebellar ataxia induced by nivolumab. *Intern Med* 2017;56(24):3357-3359.
- 79 Zecchini JM, Kim S, Yum K, Friedlander P. Development of Bell's palsy after treatment with ipilimumab and nivolumab for metastatic melanoma: a case report. *J Immunother* 2018;41(1):39-41.
- 80 Hahn L, Pepple KL. Bilateral neuroretinitis and anterior uveitis following ipilimumab treatment for metastatic melanoma. *J Ophthalmic Inflamm Infect* 2016;6(1):14.
- 81 Douglas VP, Douglas KAA, Cestari DM. Immune checkpoint inhibitors. *Curr Opin Ophthalmol* 2019;30(6):426-433.
- 82 Nasr F, El Rassy E, Maalouf G, Azar C, Haddad F, Helou J, Robert C. Severe ophthalmoplegia and myocarditis following the administration of pembrolizumab. *Eur J Cancer* 2018;91:171-173.
- 83 Hellman JB, Traynis I, Lin LK. Pembrolizumab and epacadostat induced fatal myocarditis and myositis presenting as a case of ptosis and ophthalmoplegia. *Orbit* 2019;38(3):244-247.
- 84 Crews J, Agarwal A, Jack L, Xu D, Do DV, Nguyen QD. Ipilimumab-associated retinopathy. *Ophthalmic Surg Lasers Imaging Retina* 2015;46(6):658-660.
- 85 Mantopoulos D, Kendra KL, Letson AD, Cebulla CM. Bilateral choroidopathy and serous retinal detachments during ipilimumab treatment for cutaneous melanoma. *JAMA Ophthalmol* 2015; 133(8):965.
- 86 Tsui E, Madu A, Belinsky I, Yannuzzi LA, Freund KB, Modi YS. Combination ipilimumab and nivolumab for metastatic melanoma associated with ciliochoroidal effusion and exudative retinal detachment. *JAMA Ophthalmol* 2017;135(12):1455-1457.
- 87 Roberts P, Fishman GA, Joshi K, Jampol LM. Chorioretinal lesions in a case of melanoma-associated retinopathy treated with pembrolizumab. *JAMA Ophthalmol* 2016;134(10):1184-1188.
- 88 Garibaldi M, Calabrò F, Merlonghi G, Pugliese S, Ceccanti M, Cristiano L, Tartaglione T, Petrucci A. Immune checkpoint inhibitors (ICIs)-related ocular myositis. *Neuromuscul Disord* 2020;30(5):420-423.
- 89 Manusov JS, Khoja L, Pesin N, Joshua AM, Mandelcorn ED. Retinal vasculitis and ocular vitreous metastasis following complete response to PD-1 inhibition in a patient with metastatic cutaneous melanoma. *J Immunother Cancer* 2014;2(1):41.
- 90 Reuss JE, Kunk PR, Stowman AM, Gru AA, Slingluff CL Jr, Gaughan EM. Sarcoidosis in the setting of combination ipilimumab and nivolumab immunotherapy: a case report & review of the literature. *J Immunother Cancer* 2016;4:94.
- 91 Suozzi KC, Stahl M, Ko CJ, Chiang A, Gettinger SN, Siegel MD, Bunick CG. Immune-related sarcoidosis observed in combination ipilimumab and nivolumab therapy. *JAAD Case Rep* 2016;2(3):264-268.
- 92 Ziegenhagen MW, Müller-Quernheim J. The cytokine network in sarcoidosis and its clinical relevance. *J Intern Med* 2003;253(1):18-30.
- 93 Weber JS, Kähler KC, Hauschild A. Management of immune-related adverse events and kinetics of response with ipilimumab. *J Clin Oncol* 2012;30(21):2691-2697.

- 94 Emens LA, Davis SL, Oliver SCN, Lieu CH, Reddy A, Solomon S, He LM, Morley R, Fassò M, Pirzkall A, Patel H, O'Hear C, Ferrara D. Association of cancer immunotherapy with acute macular neuroretinopathy and diffuse retinal venulitis. *JAMA Ophthalmol* 2019;137(1):96-100.
- 95 Fujimura T, Kambayashi Y, Tanita K, Sato Y, Hidaka T, Otsuka A, Tanaka H, Furudate S, Hashimoto A, Aiba S. HLA-DRB1*04:05 in two cases of Vogt-Koyanagi-Harada disease-like uveitis developing from an advanced melanoma patient treated by sequential administration of nivolumab and dabrafenib/trametinib therapy. *J Dermatol* 2018;45(6):735-737.
- 96 Abeles AM, Abeles M. The clinical utility of a positive antinuclear antibody test result. *Am J Med* 2013;126(4):342-348.
- 97 Petzold A, Wattjes MP, Costello F, Flores-Rivera J, Fraser CL, Fujihara K, Leavitt J, Marignier R, Paul F, Schippling S, Sindic C, Villoslada P, Weinshenker B, Plant GT. The investigation of acute optic neuritis: a review and proposed protocol. *Nat Rev Neurol* 2014;10(8):447-458.
- 98 Horton L, Bennett JL. Acute management of optic neuritis: an evolving paradigm. *J Neuroophthalmol* 2018;38(3):358-367.
- 99 Berson EL, Lessell S. Paraneoplastic night blindness with malignant melanoma. *Am J Ophthalmol* 1988;106(3):307-311.
- 100 Brahmer JR, Lacchetti C, Schneider BJ, Atkins MB, Brassil KJ, Caterino JM, Chau I, Ernstoff MS, Gardner JM, Ginex P, Hallmeyer S, Holter Chakrabarty J, Leighl NB, Mammen JS, McDermott DF, Naing A, Nastoupil LJ, Phillips T, Porter LD, Puzanov I, Reichner CA, Santomaso BD, Seigel C, Spira A, Suarez-Almazor ME, Wang YH, Weber JS, Wolchok JD, Thompson JA, Network NCC. Management of immune-related adverse events in patients treated with immune checkpoint inhibitor therapy: American Society Of Clinical Oncology Clinical Practice Guideline. *J Clin Oncol* 2018;36(17):1714-1768.
- 101 Attia P, Phan GQ, Maker AV, Robinson MR, Quezado MM, Yang JC, Sherry RM, Topalian SL, Kammula US, Royal RE, Restifo NP, Haworth LR, Levy C, Mavroukakis SA, Nichol G, Yellin MJ, Rosenberg SA. Autoimmunity correlates with tumor regression in patients with metastatic melanoma treated with anti-cytotoxic T-lymphocyte antigen-4. *J Clin Oncol* 2005;23(25):6043-6053.
- 102 Austin A, Lietman T, Rose-Nussbaumer J. Update on the management of infectious keratitis. *Ophthalmology* 2017;124(11):1678-1689.
- 103 Kanavati S, Ottensmeier C, Foria V, Krishnan R. Bilateral metastatic cutaneous melanoma to retina and vitreous after ipilimumab treated with pars Plana vitrectomy and radiotherapy. *Retin Cases Brief Rep* 2018;12(3):184-187.
- 104 Ileana Dumbrava E, Smith V, Alfattal R, El-Naggar AK, Penas-Prado M, Tsimberidou AM. Autoimmune granulomatous inflammation of lacrimal glands and axonal neuritis following treatment with ipilimumab and radiation therapy. *J Immunother* 2018;41(7):336-339.
- 105 Hottinger AF. Neurologic complications of immune checkpoint inhibitors. *Curr Opin Neurol* 2016;29(6):806-812.
- 106 Telfah M, Whittaker TJ, C Doolittle G. Vision loss with pembrolizumab treatment: a report of two cases. *J Oncol Pharm Pract* 2019;25(6):1540-1546.