

# Y-splitting medial rectus muscle and recession in treatment for convergence excess esotropia

Li-Juan Huang<sup>1,2</sup>, Yu-Yu Wu<sup>1</sup>, Ning-Dong Li<sup>1,2,3,4</sup>

<sup>1</sup>Department of Ophthalmology, the Second Affiliated Hospital of Fujian Medical University, Quanzhou 362000, Fujian Province, China

<sup>2</sup>Department of Ophthalmology, Beijing Children's Hospital, Capital Medical University, Beijing 100045, China

<sup>3</sup>Key Laboratory of Major Diseases in Children, Ministry of Education, Beijing 100045, China

<sup>4</sup>Department of Ophthalmology, Children's Hospital, Capital Institute of Pediatrics, Beijing 100020, China

**Co-first authors:** Li-Juan Huang and Yu-Yu Wu

**Correspondence to:** Ning-Dong Li. Department of Ophthalmology, the Second Affiliated Hospital of Fujian Medical University, Quanzhou 362000, Fujian Province, China; Department of Ophthalmology, Beijing Children's Hospital, Capital Medical University, Beijing 100045, China; Key Laboratory of Major Diseases in Children, Ministry of Education, Beijing 100045, China; Department of Ophthalmology, Children's Hospital, Capital Institute of Pediatrics, Beijing 100020, China. lnd30@163.com

Received: 2021-06-29 Accepted: 2021-12-09

## Abstract

• **AIM:** To evaluate the surgical outcome of medial rectus (MR) recession with Y-splitting procedure in treatment of esotropia with convergence excess.

• **METHODS:** Medical records were retrospectively reviewed for those patients who underwent surgical treatment for their convergence excess esotropia (CEET) between January 2018 and December 2020. Refractive error was examined by the equipment of the VS100 (Welch Allyn). The surgical approach was bilateral MR recession with Y-splitting. The amount of recession was calculated according to the deviation angle at distance. Ocular movement and ocular alignment at distance and near were evaluated pre- and post-operatively. Binocular sensory status was evaluated by the Bagolini striated glasses at near and distance, and by stereoacuity assessment at near using the Titmus test.

• **RESULTS:** Six patients with CEET were included in this study. Four of them were hyperopia and two of them were myopia. A mean of eso-deviation angle at distance

had been changed from  $27.3 \pm 13.02$  prism diopters (PD) preoperatively to  $1.83 \pm 1.60$  PD postoperatively ( $P < 0.05$ ), while a mean of eso-deviation angle at near had been changed from  $50.00 \pm 20.74$  PD preoperatively to  $6.83 \pm 0.98$  PD postoperatively ( $P < 0.05$ ). Patients had obtained binocular vision postoperatively.

• **CONCLUSION:** The surgical approach of Y-splitting MR and recession is effective in treatment of CEET.

• **KEYWORDS:** Y-splitting; convergence excess; esotropia

**DOI:10.18240/ijo.2022.04.21**

**Citation:** Huang LJ, Wu YY, Li ND. Y-splitting medial rectus muscle and recession in treatment for convergence excess esotropia. *Int J Ophthalmol* 2022;15(4):661-665

## INTRODUCTION

Convergence excess esotropia (CEET) refers to an eso-deviation angle at least 15 prism diopters (PD) larger at near than at distance under the fully optically correction of refractive error<sup>[1]</sup>. Patients with CEET may have a high or a normal accommodative convergence to accommodation (AC/A) ratio, with a refractive status of hyperopia, emmetropia, or even myopia.

Optical correction with bifocal lens is useful for those patients who have orthophoria or esophoria at distance, and esotropia at near due to high AC/A ratio, but not useful for those patients with normal or lower AC/A<sup>[2-4]</sup>. If the patients have an esodeviation angle of more than 8 PD at distance under completely optical correction, they usually cannot compensate their esotropia by fusion, so that they have to accept surgical treatment for their esotropia.

Although some surgical techniques have been reported for CEET treatment, it is still a tough issue for many surgeons to treat this type of esotropia due to the difference between the esodeviation angles at near and distance<sup>[5-8]</sup>. Here, we evaluate the effectiveness of bilateral medial rectus (MR) recession and Y-splitting in surgical treatment of CEET. The technique of muscle Y-splitting has been proved to be effective in reducing the muscle torque and changing the muscle contraction in the secondary gaze position, so that it can be used in resolving excessive adduction when convergence at near.

**Table 1 Clinical data of six patients**

Case	Age (y)	D/N PR (PD)	N-D PR (PD)	Fusion PR	Refractive state (SE)	AC/A PR	Dosage (BMR, mm)	D/N PO (PD)	N-D PO (PD)	Fusion/stereopsis PO
1	9	+18/+40	22	-	R+2.50DS L+1.75DS	4	3	+2/+6	4	+/400"
2	7	+20/+40	20	-	R+1.75DS L+2.25DS	8	3.5	+4/+8	4	+/400"
3	6	+16/+35	19	-	R-3.25DS L-2.00DS	7	3	0/+6	6	+/200"
4	8	+50/+90	40	-	R+3.75DS L+3.50DS	10	5.5	+2/+8	6	+/800"
5	12	+25/+40	15	-	R+0.50DS L+1.25DS	4	4	+3/+7	4	+
6	21	+35/+55	20	-	R-1.25DS L-0.75DS	3	4.5	0/+6	6	+

D/N: Distance/near deviation; PR: Preoperation; N-D: Difference between near and distance deviations; SE: Spherical equivalent; AC/A: Accommodative convergence to accommodation; PO: Postoperation; Dosage: Amount of recession; BMR: Bilateral recession of the MR muscle; +: With fusion function; -: Suppression; PD: Prism diopter.

**SUBJECTS AND METHODS**

**Ethical Approval** Written informed consent was obtained from the patients or the patient’s guardian preoperatively. All protocols adhered to the principles of the Declaration of Helsinki.

**Patients** Medical records were retrospectively reviewed for six patients with CEET who underwent strabismus surgery by the authors from January 2018 to December 2020.

Four of patients had mild to moderate hyperopia, and two of them were myopia. Three of four hyperopia patients had a history of wearing bifocal lens for correcting their esotropia initially for at least 6mo, but had to undergo surgery due to their esotropia at distance even with a fully optical correction for their hyperopia and esotropia. One patient was diagnosed as congenital esotropia combined with accommodative esotropia. All patients were able to fixate with either eye and excluded with amblyopia in a single eye. They were also excluded with paralytic strabismus as well as neurological and psychiatric disorders. All six patients had no surgical history for their esotropia correction. The detailed clinical information was provided in Table 1.

**Pre- and Postoperative Evaluations** Pre- and postoperative evaluations were performed for general ocular conditions (best corrected visual acuity, anterior segment and fundus), ocular movement at nine cardinal gaze positions, ocular misalignments and binocular status. Patients younger than 14y had cycloplegic refraction and those older than 14y had refraction without cycloplegia. The prism and alternate cover test was used to measure the deviation angles at near (33 cm) and distance (6 m) under the conditions of with and without the corrective lens. The AC/A ratio was assessed using the gradient method. The formula was  $AC/A = (PD_2 - PD_1) / 3 D$ .  $PD_1$  is the deviation angle measured by the prism and alternate

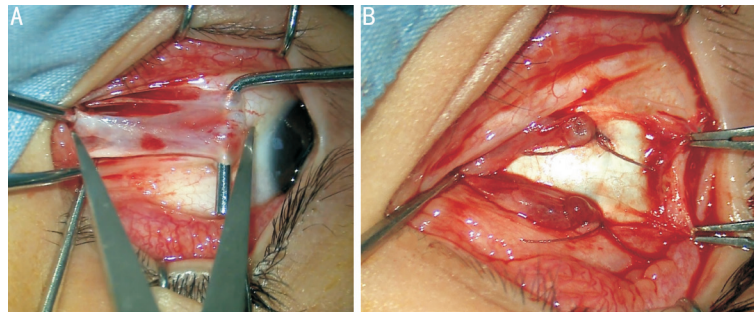
cover test looking at a target at 5 m, while  $PD_2$  is the deviation angle measured with a -3 D lens added to the eye<sup>[1]</sup>. Binocular sensory status was evaluated with the Bagolini striated glasses at near and distance, and by stereoacuity assessment at near using the Titmus test (Stereo Optical Co., Inc., Chicago, IL, USA).

**Surgical Procedures** A fornix incision was performed at the inferonasal region of the operated eye under general anesthesia. After being exposed and hooked, the MR muscle was split longitudinally from its insertion to the location of 15 mm posterior to the insertion into two equal halves with a small hook (Figure 1A). Each half of MR was sutured separately at the 1 mm posterior to the insertion with locking bites using a double armed, 6-0 Vicryl suture, and then severed from the insertions. The two separated MR bundles were recessed and reattached to the globe in a Y-shape with one-tendon-width apart (Figure 1B). The amount of recession was calculated by the deviation angle at distance. Surgical success was defined as a horizontal deviation of <8 PD at near and distance at primary gaze position. Overcorrection was defined as exotropia of  $\geq 10$  PD at distance, and undercorrection was defined as esotropia of  $\geq 10$  PD. The follow-up was scheduled postoperatively at 1d, 1wk, 1, 3, and 6mo.

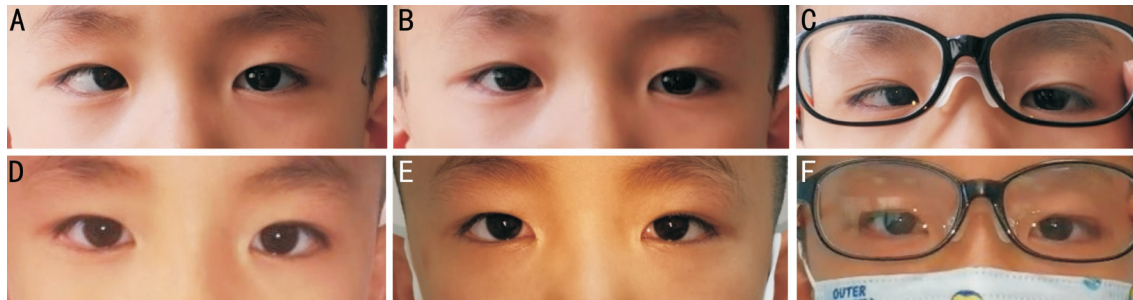**Statistical Analysis** The paired *t*-test was used to compare the mean deviation angles at near and distance, as well as the mean difference between the near and distance deviations pre- and post-operatively. SPSS version 22.0 for Windows (SPSS, Chicago, IL, USA) was used for statistical analysis. A *P* value of <0.05 was considered statistically significant.

**RESULTS**

All six patients with CEET had undergone bilateral MR recession with Y-splitting procedure. The mean esodeviation at the primary position was  $27.3 \pm 13.02$  PD preoperatively



**Figure 1 MR recession and Y-splitting** A: MR splitting to 15 mm posterior to the muscle insertion; B: Two halves of MR were recessed and reattached as Y-shape on the scleral surface.



**Figure 2 Ocular alignments pre- and postoperation** A: CEET patient with myopia (case 3 in Table 1) underwent bilateral MR recession and Y-splitting. His esodeviation angle at near (A) was larger than that at distance (B), and was not able to reduce the near-distance disparity with bifocal lens (C) preoperatively. He had a orthophoria at both near and distance with or without the optical lens postoperatively (D, E, F).

and  $1.83 \pm 1.60$  PD postoperatively at distance ( $P < 0.05$ ). The mean esodeviation at near was  $50.00 \pm 20.74$  PD preoperatively and  $6.83 \pm 0.98$  PD postoperatively ( $P < 0.05$ ). The mean near-distance disparity was significantly reduced from  $22.67 \pm 8.80$  PD preoperatively to  $5.00 \pm 1.09$  PD postoperatively ( $P < 0.05$ ; Tables 1 and 2). Patients had achieved satisfactory surgical outcomes showing a good ocular alignment at near and distance without limitation on any gaze positions (Figure 2). In addition, their sensory status had been improved because patients who didn't have binocular vision had acquired near stereopsis or binocular vision postoperatively.

## DISCUSSION

As mentioned above, surgical treatment for CEET is a tough issue for many doctors due to the distance-near disparity of esodeviation. If the surgical dosage was calculated based on the deviation angle at near, overcorrection would occur at distance. On the other hand, if the surgical dosage was calculated based on the deviation angle at distance, postoperative under-correction would be present, and thus patients would have to wear bifocal lens to correct residual esotropia at near postoperatively. However, for those patients with normal and low AC/A or myopia, bifocal lens could be useless for correction of esotropia at near.

A series of surgical procedures have been designed to decrease the distance-near disparity in CEET, including posterior fixation with sutures on the belly or on the pulley of MR, as well as slanted recession of the MR, Scott's procedure

**Table 2 Mean pre- and postoperative esodeviation angles**

Measurement	mean $\pm$ SD, PD		
	Deviation PR	Deviation PO	P
Distance	27.3 $\pm$ 13.02	1.83 $\pm$ 1.60	<0.05
Near	50.00 $\pm$ 20.74	6.83 $\pm$ 0.98	<0.05
N-D disparity	22.67 $\pm$ 8.80	5.00 $\pm$ 1.09	<0.05

PR: Preoperatively; PO: Postoperatively; N-D disparity: Difference between near and distance deviations.

(simultaneous resection and recession on MR), as well as Y-splitting of MR with recession<sup>[5-9]</sup>.

Posterior fixations with sutures on the belly of muscle, also named as Faden procedure, can reduce effectively the muscle torque at its field of action without disturbance of the primary gaze position, and has been used for the surgical management for CEET because this procedure may produce a restrictive action on the overactive MR at the second gaze position<sup>[6,10]</sup>. However, the main challenge for many doctors is the surgical technique on performing a retro-equatorial suture fixation at the sclera, which in turn would increase the risk of sclera perforation. An alternative approach of Faden procedure is posterior fixation of the muscle pulley with MR recession<sup>[11-12]</sup>, however, we don't have sufficient experience in this procedure. Recently, extraocular muscles have been proved to be compartmentalized by their function. The superior and MR compartment had different contractility in conjugate adduction in similar-magnitude convergence<sup>[13]</sup>. Taking advantage of

the functional difference in the compartments of extraocular muscle, the surgical approaches of slanted recession or slanted resection to weaken or strengthen the corresponding muscle compartments are used to surgical managements for convergence insufficiency exotropia, A-V pattern, as well as CEET in which the lower two-thirds compartments would be recessed farther than the upper one-thirds compartment of MR<sup>[14-16]</sup>. The recessed amount of lower compartments is calculated according to the deviation angle at near, while the surgical amount for the recessed upper compartment is calculated on the deviation angle at distance<sup>[16]</sup>. In our own experience, this surgical approach works very well when the deviation angle is less than 50 PD at distance and the distance-near disparity under 25 PD. If more than these parameters, for example, case 4 in the Table 1, recession of MR would be augmented or resection of later rectus is needed. In addition, the lower compartment of MR is needed to be recessed far more distance than the upper compartment to correct a larger near-distance disparity, which is not easy to operate on a whole muscle rather than on a split muscle.

Scott procedure has the same effect as Faden procedure through simultaneous resection and recession on MR in which the amount of recession is equal to the amount of resection of extraocular muscle, or a bit larger than that of resection<sup>[17-18]</sup>. We think this procedure would benefit for correction of CEET with orthotropia or a small angle of esodeviation. However, for CEET with a moderate or a larger angle of esodeviation, an additional MR recession is needed to counteract the effect caused by MR resection, which could result in limitation on adduction due to large amount of recession.

Y-splitting recession as a secondary and/or unilateral surgery for distance/near esotropia can reduce distance/near disparity<sup>[19]</sup>. Recently, the surgical approach of Y-splitting MR and recession has been proven to be powerful for CEET treatment because of the combined effects of muscle recession and splitting<sup>[9]</sup>. Recession of muscle may decrease the muscle force while Y-splitting may reduce muscle torque similar to the Faden procedure, and they work together to decrease the esotropia and the distance-near disparity. The effectiveness of this procedure is further supported in this study by the satisfactory surgical outcomes from our patients. We agree to that separation of one-muscle width is enough for two halves of MR instead of separating them far away from other each. We feel that the method used by Hoerantner *et al*<sup>[20]</sup> is too complicated in measuring the locations of insertions for two separated MR bundles. The surgical dosage described by Hoerantner *et al*<sup>[20]</sup>. In their method, the amount of recession was on the average of 2.6±0.6 mm. The arms of two separated half muscle were 15 mm longer with an angle of 62.8±5.7 degrees. The rotating torque was able to be changed

significantly by the 15 mm length separation of extraocular muscles through mathematical calculation. Although we didn't calculate the angle of two separated muscle, we think one-tendon-width separation is more easily determined. However, we agree to their opinion that that the splitting distance should be 15 mm or more, so that the muscle torque could be effectively reduced when combination with MR recession. In addition, Bagheri *et al*<sup>[9]</sup> think that two unequal separated arms of MR may produce vertical or torsional deviations. We think their opinion should be confirmed further because a lot of patients with esotropia don't have a good binocular status and are not able to detect torsional deviation even though they have torsion in their fundi. Anyway, we think that MR splitting and recession is a safe and powerful approach in surgical correction of CEET, and easily learned.

#### ACKNOWLEDGEMENTS

**Foundation:** Supported by the National Natural Science Foundation of China (No.81670883).

**Conflicts of Interest:** Huang LJ, None; Wu YY, None; Li ND, None.

#### REFERENCES

- 1 von Noorden GK. *Binocular Vision and Ocular Motility*. 5th ed. St. Louis, Mo.; Mosby-Year Book; 1996:336.
- 2 von Noorden GK, Morris J, Edelman P. Efficacy of bifocals in the treatment of accommodative esotropia. *Am J Ophthalmol* 1978;85(6):830-834.
- 3 Vivian AJ, Lyons CJ, Burke J. Controversy in the management of convergence excess esotropia. *Br J Ophthalmol* 2002;86(8):923-929.
- 4 Lucas E, Bentley CR, Aclimandos WA. The effect of surgery on the AC/A ratio. *Eye (Lond)* 1994;8(Pt 1):109-114.
- 5 Inal A, Ocak OB, Aycit ED, Celik S, Ozturk Karabulut G, Inal B, Taskapili M, Gokyigit B. Medial rectus bridge faden operations in accommodative and partially accommodative esotropia with convergence excess. *J Pediatr Ophthalmol Strabismus* 2017;54(6):369-374.
- 6 Mitchell L, Kowal L. Medial rectus muscle pulley posterior fixation sutures in accommodative and partially accommodative esotropia with convergence excess. *J AAPOS* 2012;16(2):125-130.
- 7 Somer D, Cinar FG, Oral B, Ornek F. Combined recession and resection surgery in the management of convergence excess esotropia with different levels of AC/A ratio. *J AAPOS* 2017;21(1):7.e1-7.e7.
- 8 Khalifa YM. Augmented medial rectus recession, medial rectus recession plus Faden, and slanted medial rectus recession for convergence excess esotropia. *Eur J Ophthalmol* 2011;21(2):119-124.
- 9 Bagheri A, Abbasnia E, Tavakoli M. Modified Y-split and recession of medial rectus muscles in convergence excess esotropia. *Eur J Ophthalmol* 2021;31(6):3386-3393.
- 10 Gharabaghi D, Zanjani LK. Comparison of results of medial rectus muscle recession using augmentation, Faden procedure, and slanted recession in the treatment of high accommodative convergence/

- accommodation ratio esotropia. *J Pediatr Ophthalmol Strabismus* 2006;43(2):91-94.
- 11 Demer JL, Oh SY, Poukens V. Evidence for active control of rectus extraocular muscle pulleys. *Invest Ophthalmol Vis Sci* 2000;41(6):1280-1290.
- 12 Wabulembo G, Demer JL. Long-term outcome of medial rectus recession and pulley posterior fixation in esotropia with high AC/A ratio. *Strabismus* 2012;20(3):115-120.
- 13 Demer JL, Clark RA. Magnetic resonance imaging of differential compartmental function of horizontal rectus extraocular muscles during conjugate and converged ocular adduction. *J Neurophysiol* 2014;112(4):845-855.
- 14 Farid MF, Abdelbaset EA. Surgical outcomes of three different surgical techniques for treatment of convergence insufficiency intermittent exotropia. *Eye (Lond)* 2018;32(4):693-700.
- 15 Ohba M, Ohtsuka K, Osanai H. Treatment for A and V strabismus by slanting muscle insertions. *Binocul Vis Strabismus Q* 2004;19(1):13-20.
- 16 Bayramlar H, Ünlü C, Dag Y. Slanted medial rectus recession is effective in the treatment of convergence excess esotropia. *J Pediatr Ophthalmol Strabismus* 2014;51(6):337-340.
- 17 Ramasamy B, Rowe F, Whitfield K, Nayak H, Noonan CP. Bilateral combined resection and recession of the medial rectus muscle for convergence excess esotropia. *J AAPOS* 2007;11(3):307-309.
- 18 Huang L, Wu Y, Li N. A single inferior rectus muscle surgery for treatment of congenital superior oblique palsy with small deviation in primary position. *Eur J Ophthalmol* 2021;11206721211014377.
- 19 Wipf M, Priglinger S, Palmowski-Wolfe A. Y-split recession of the medial rectus muscle as a secondary and/or unilateral procedure in the treatment of esotropia with distance/near disparity. *J Ophthalmol* 2017;2017:6472690.
- 20 Hoerantner R, Priglinger S, Koch M, Haslwanter T. A comparison of two different techniques for oculomotor torque reduction. *Acta Ophthalmol Scand* 2007;85(7):734-738.