

# Inflammation and dry eye disease—where are we?

Srinivas K Rao<sup>1</sup>, Rishi Mohan<sup>2</sup>, Nikhil Gokhale<sup>3</sup>, Himanshu Matalia<sup>4</sup>, Paras Mehta<sup>5</sup>

<sup>1</sup>Darshan Eye Care & Surgical Centre, Chennai, Tamil Nadu 600040, India

<sup>2</sup>MM Eyetech Institute of Ophthalmology, New Delhi 110024, India

<sup>3</sup>Gokhale Eye Hospital, Mumbai, Maharashtra 400028, India

<sup>4</sup>Narayana Nethralaya, Electronic City, Bangalore 560001, Karnataka, India

<sup>5</sup>Sameep Eye Hospital and Corneal Center, Vadodara 390006, Gujarat, India

**Correspondence to:** Srinivas K Rao. Darshan Eye Care & Surgical Centre, Chennai, Tamil Nadu 600040, India. [srinikrao@gmail.com](mailto:srinikrao@gmail.com)

Received: 2021-01-25 Accepted: 2021-10-25

## Abstract

• The presence of inflammation in dry eye disease (DED) results in increased patient symptomatology, ocular surface damage and worsening tear dysfunction. It also affects the health of meibomian glands and their secretions which further aggravates ocular surface disease. This article reviews current knowledge regarding ocular surface inflammation in DED and explores the relationships between the vicious cycles of DED, inflammation and meibomian gland dysfunction (MGD). The clinical evaluation of eyes with such changes, markers that identify the presence of inflammation on the ocular surface and current treatment options are discussed.

• **KEYWORDS:** dry eye disease; inflammation; meibomian gland dysfunction; vicious cycle; ocular surface disease

**DOI:10.18240/ijo.2022.05.20**

**Citation:** Rao SK, Mohan R, Gokhale N, Matalia H, Mehta P. Inflammation and dry eye disease—where are we? *Int J Ophthalmol* 2022;15(5):820-827

## INTRODUCTION

The Dry Eye Workshop (DEWS) II defines dry eye disease (DED) as a multifactorial disorder of the tears and ocular surface, associated with symptoms of discomfort, visual disturbance, and tear film instability, accompanied by increased osmolarity of the tear film and inflammation of the ocular surface<sup>[1]</sup>. The tear film is part of a larger ocular surface ecosystem, that also comprises the lids and their

adnexa, the blink reflex and lacrimal drainage system, the lacrimal and accessory glands, and the epithelia of the cornea and conjunctiva. These structures function in an integrated manner to provide ocular comfort, clear vision, and maintain the structural integrity of the ocular surface. The co-ordination of these activities is brought about by a complex interplay of various neural, humoral, endocrine, vascular, and immune system inputs, which are also influenced by the environment, the systemic health of the individual and various dietary, social factors and medications<sup>[2]</sup>. A disturbance of this delicate homeostasis results in dysregulation of the balance and disease of the ocular surface, and inflammation plays a major role in this process.

The burden of DED is steadily increasing and it is believed to be one of three rapidly growing eye-problems in the aged, and results in one out of 4 visits to the ophthalmologist<sup>[3]</sup>. There is increasing prevalence worldwide<sup>[4]</sup> especially in the Asian population, with a greater occurrence of meibomian gland dysfunction (MGD), in the elderly<sup>[5]</sup>. However, with changing lifestyles and increasing use of video display terminals (VDT) in low humidity environments, the prevalence of tear dysfunction and ocular surface symptomatology is now steadily increasing in younger patients as well, and they form a significant proportion of those affected<sup>[6]</sup>. The management of this condition has evolved beyond the use of tear substitutes, with the increased understanding of the role of inflammation in ocular surface changes.

Inflammation in general pathology is typified by the four key symptoms described by Celsus—redness, swelling, heat and pain. Virchow critically analyzed these symptoms in inflammation and added loss of function of the inflamed tissues in 1871<sup>[7]</sup>. These tenets apply to the ocular surface as well, and inflammation produces a red eye, often with conjunctival edema, and significant discomfort. If inflammation is left untreated, progression of changes can result in transient visual fluctuations in the early stages and corneal damage and permanent loss of vision in the later stages. Interestingly, inflammation is a defense mechanism that is triggered by damage to living tissues and is intended to protect them from infection and injury. The acute response by the innate immune system, is short-lived, helps to eliminate the noxious agent, and restore the integrity of damaged tissues through repair processes<sup>[8]</sup>. In the presence of a persistent stimulus however,

the adaptive immune response is activated, resulting in chronic inflammation. This triggers a self-perpetuating vicious cycle which makes multiple abortive attempts at healing, resulting in scarring and damage of the ocular surface<sup>[9]</sup>. Although the association between DED and inflammation has been known for the past 40y<sup>[10]</sup>, the exact role of the latter in the disease process, its temporal evolution and the processes involved at the cellular and molecular levels are still being elucidated. It is now understood that inflammation is both a cause and a consequence of DED. This article explores current knowledge in this area and attempts to answer the following issues related to ocular surface inflammation in DED.

### **DYSREGULATION OF THE OCULAR SURFACE AND INFLAMMATION**

Hyperosmolarity and tear film instability are considered as primary events that initiate the various changes seen in the ocular surface in DED<sup>[1]</sup>. These result from a decrease in production of aqueous tears or an increase in evaporative loss of the tear film. The hyperosmotic tear film activates stress-associated mitogen-activated protein kinases in the ocular surface epithelial cells, such as c-Jun N-terminal kinase, and p38<sup>[11]</sup>. The mitogen-activated protein kinase signaling pathway then initiates a sequence of events that result in the accumulation of various mediators, and inflammation of the ocular surface. The various mechanisms by which such changes occur include 1) A decrease in tear secretion-occurs in diseases that cause lacrimal gland inflammation and destruction such as Sjögren's syndrome, other autoimmune conditions, graft versus host disease (GVHD), and Stevens-Johnson syndrome (SJS). Factors such as chronic contact lens wear, topical medications containing preservatives, and surgical procedures or other causes of neurotrophin can affect the afferent arm of the feedback system on the ocular surface. 2) Altered tear distribution and turnover-occur in lid margin irregularities, lax lids, or abnormalities in lid position, and conjunctivochalasis. Alterations in the regularity of the ocular surface like pterygia or pinguecula, or post-surgical alterations can result in reduced wettability of portions of the ocular surface, with desiccation and epithelial stress. 3) Increased evaporative loss of the tear film. Dysfunction of the meibomian glands can result in reduced or excessive lipid secretion onto the surface, or an alteration in the quality of meibum can be caused by eye surgery, hormonal disturbances, floppy eyelid syndrome, giant papillary conjunctivitis, rosacea, and the presence of *Staphylococcal* or *Demodex* blepharitis. A poor blink rate can be related to prolonged use of VDTs or from conditions such as Parkinsonism or thyroid eye disease that can reduce the blink rate. Environmental conditions that result in increased temperature, low humidity and or excess air flow across the ocular surface can also result in increased tear evaporation.

### **INFLAMMATION AS A PROTECTIVE OR DESTRUCTIVE RESPONSE**

Many of the initiating conditions occur in an acute manner and the resulting acute inflammatory response is a short-lived process that is orchestrated by the innate immune defense. Satisfactory resolution of the condition occurs when the noxious stimulus or offending condition is removed, e.g., when a toxic topical medication is stopped. In DED, however, the persistence of hyperosmolarity and frictional trauma to the ocular surface caused by insufficient lubrication, continue to act as drivers of inflammation<sup>[12]</sup>. With the persistence of the insult, the adaptive immune system is activated and chronic inflammation results. The perpetuation of inflammation results in damage to the ocular surface, further dysregulation of the immune system and an amplification of the inflammatory response. A vicious cycle of inflammation is then formed, which perpetuates itself independent of the initial insult.

### **INFLAMMATION**

**Cause and Effect** Tear film hyperosmolarity, instability and inflammation tend to co-exist. As discussed in the first section, the tear film disturbance affects epithelial cells and triggers the inflammatory cascade. As the DED progresses, so does the inflammation, and damages the surface epithelium, nerves, and goblet cells, worsening the DED. Inflammation also results in changes in the meibomian glands (MGs) and MGD further perpetuates the cycle of DED. Eventually, DED becomes an irreversible chronic inflammatory condition that is self-perpetuating, concurrent with a similar self-perpetuating vicious cycle of inflammation. In these conditions, DED is the initiating event and triggers inflammation.

In other systemic immune-mediated conditions like Sjögren's syndrome, lymphocyte infiltration in the lacrimal glands can result in damage and fibrosis<sup>[13]</sup>. This results in reduced tear secretion and inflammatory cytokines in the tears from the affected gland. In GVHD an increased density of dendritic cells (DC) has been reported in the cornea<sup>[14]</sup>. In the same condition, infiltration of inflammatory cells in the MGs has been noted and postulated to cause excessive fibrosis and atrophy of these glands<sup>[15]</sup>. Similarly, in otherwise normal eyes, the occurrence of SJS results in a pro-inflammatory cytokine storm in the tears of patients, causing ocular surface damage. In systemic inflammatory conditions, inflammation acts as the trigger that damages the ocular surface and DED then ensues.

Recently, the Asia Dry Eye Society (ADES) defined dry eye as "a multifactorial disease characterized by an unstable tear film causing a variety of symptoms and/or visual impairment potentially accompanied by ocular surface damage"<sup>[16]</sup>. They emphasize the importance of the unstable tear film, and described an entity termed short tear film break-up time (TFBUT) dry eye, seen in VDT workers. They created a rat

model to mimic these changes and were able to show that there was lacrimal gland dysfunction, as evidenced by a decrease in tear secretion, which resolved when the desiccating stimulus was removed<sup>[17]</sup>. In another report, infiltration of immune cells was not noted in the lacrimal glands of VDT workers, unlike that seen in the glands of patients with Sjögren's syndrome. From these findings, they proposed a non-inflammatory mechanism for VDT work-related dry eye, in which the tear secretion disorder is probably related to a poor blink rate<sup>[18]</sup>. However, in this condition if the stimulus persists long enough it is likely that both DED and inflammation can occur, and it is unclear as to which of these could be the initial event.

Thus, it appears that a damaged ocular surface can set up an inflammatory response, which is initially an acute, self-limited response with symptoms and surface damage, but symptom resolution and damage repair occur after the trigger has been removed. However, in DED the persistence of the insult results in the creation of a chronic inflammatory state. In other conditions, an inflammatory condition affects the otherwise normal tissues of the ocular surface and the tear secretory glands, and the resultant damage produces DED. Although the pathways for inflammation to enter the cycle of DED can differ, once the DED state is established, concurrent inflammation is the norm, and each help in the persistence and perpetuation of the other. Inflammation is therefore, both a cause and a consequence of DED. Recent reports from Japan indicate<sup>[19]</sup> that there can also possibly be a non-inflammatory subset of dry eye in VDT workers, although it is possible that the persistence of these changes would result in the eventual onset of inflammation in such eyes. It appears therefore, that the temporal sequence of inflammation and DED causation can vary according to the associated disease and does not follow a uniform course in all eyes.

#### **Pathophysiology of Inflammation and Clinical Implications**

All immune processes share certain common characteristics. They are triggered by stimuli and recognition of the noxious agent is facilitated by cells which can present the antigen to immune cells in the appropriate lymphatic processing center. In the center, there is activation of the effector immune cells, which travel back to the target tissue *via* lymphatics to initiate the inflammatory response and eliminate the offending agent.

In an uninflamed ocular surface, the presence of an antigen which is considered harmless, results in the production of a tolerogenic antigen presenting cell (APC) by the epithelial cell, by as yet unrecognized mechanisms. These APCs are able to produce T helper cell subsets in the lymph nodes, which then travel back to the ocular surface *via* lymphatics. On subsequent exposure to the antigen, these T helper cells are activated and immune system activity is regulated to result in a quiet ocular surface. When the epithelial cells are damaged in DED

however, the protective mechanism is lost, and the APCs now produce effector T cells in the lymph nodes, which are able to provide an escalation of the immune response on the ocular surface and increased inflammation.

In the ocular surface, a stressful stimulus, which can be environmental, microbial, endogenous, hormonal, or genetic, results in activation of APCs and DCs. These travel to the regional lymph nodes through afferent lymphatic vessels, where they prime naive T cells. These transform into CD4+ T-helper cell subsets T<sub>H</sub>1 and T<sub>H</sub>17 and migrate through the efferent vasculature back to the ocular surface, where they induce epithelial damage and cytokine release<sup>[20]</sup>.

The cells involved in this process include the APCs, effector T cells, regulatory T cells and natural killer (NK) cells. The effector T cells produce inflammation, while the regulatory T cells suppress the immune response. The presence of effector cells in the ocular surface initiates a cascade of events that requires the presence of multiple agents.

1) Cytokines are signaling molecules that mediate intercellular communication. 2) Interleukins are cytokines that aid signalling between lymphocytes. 3) Chemokines are cytokines that are responsible for targeted migration of immune cells, a process termed chemotaxis. 4) Matrix metalloproteinases (MMP) are endopeptidases involved in tissue remodeling. 5) HLA-DR, fas and fas ligand are involved in antigen presentation and apoptosis. 6) Cell adhesion molecules are surface molecules that enhance cell migration by binding to extracellular matrix.

The affected epithelial cells in DED stimulate the inflammatory cascade involving mitogen-activated protein kinases and nuclear factor  $\kappa$ -light-chain-enhancer of activated B cell signaling pathways, cytokines [interleukin (IL)-1 $\alpha$ , IL-1 $\beta$ , tumor necrosis factor (TNF)- $\alpha$ , and MMP-9]<sup>[21]</sup>. T<sub>H</sub>1 and T<sub>H</sub>17 can initiate the release of additional inflammatory mediators like interferon  $\gamma$ , TNF- $\alpha$ , IL-2 and IL-17. These results in goblet cell dysfunction and death and disruption of corneal barrier function, and this is further aided by the presence of MMP-9. These changes result in deterioration of tear function and epithelial cell damage, which promotes more inflammation. IL-17 also promotes corneal lymphangiogenesis in DED, and these vessels provide a potential route by which APCs can travel to the lymph nodes, and activated T cells back to the ocular surface. IL-17 can also upregulate the expression of MMP-9<sup>[22]</sup>. The presence of IL-6 has been reported to correlate with the severity of irritation symptoms.

The final effects produced by these processes result in epitheliopathy, neuropathy and lymphangiogenesis. Unfortunately, each of these can further induce the production of mediators and facilitate the propagation of the inflammatory response. The inflammatory cytokines are also able to induce the expression of corneal envelope precursors by the ocular

surface epithelium, which results in keratinization of MG orifices, and MGD<sup>[23]</sup>. Thus, the changes initiated by DED result in cell apoptosis, recruitment of inflammatory cells and their mediators, T lymphocyte activity, loss of goblet cells, changes in the MG and lacrimal glands, nerve damage, and lymphangiogenesis. Each of these changes influences the other and this chain of events results in an escalating cascade of inflammation, which forms a vicious cycle, which can perpetuate itself in a chronic manner.

**Related Vicious Cycles of Dry Eye Disease, Meibomian Gland Dysfunction and Inflammation** The concept of a vicious cycle has been proposed for DED, inflammation and MGD by various authors. The pathophysiologic mechanisms in DED were detailed in the DEWS II report. Tear hyperosmolarity and tear film instability are described as key drivers of DED. These can be caused by low aqueous tear flow and or increased evaporation and trigger the release of inflammatory mediators into the tear fluid, initiating an inflammatory cascade. The resulting damage to the corneal and conjunctival cells causes cell death by apoptosis, goblet cell loss, and reduced mucus secretion. These further aggravate tear film hyperosmolarity and instability, thus perpetuating the vicious cycle of DED<sup>[1]</sup>.

While the exact mechanisms responsible for ocular surface inflammation in DED are yet unclear, it appears that desiccating environmental stress and changes in tear fluid composition may be important triggers. Interestingly, these are also the triggers for initiating the changes that result in the vicious cycle in DED. In certain subsets of patients, like those with Sjögren's syndrome, dysfunction of intrinsic immunoregulatory pathways may result in exacerbation of these pro-inflammatory stimuli. Similarly, in those with age-related or disease-related androgen deficiency, local autoimmune reactions may be promoted, worsening the inflammation. When exposed to a hyperosmolar state, corneal epithelial cells initiate the production of pro-inflammatory molecules. These cytokines trigger the production of adhesion molecules by vascular endothelial and epithelial cells in the conjunctiva, and this results in chemotactic recruitment and retention of inflammatory cells on the ocular surface. The net effect of these changes is to produce epithelial apoptosis, and this damage can be detected by ocular surface staining. Some of these mediators are also responsible for the symptoms accompanying ocular surface inflammation. Also, these cytokines release MMPs, and the interaction between these further escalates the inflammation. Accompanying these changes is cytokine-mediated apoptosis of glandular epithelia, which results in reduced tear secretion. Thus, the damaged ocular surface in DED promotes inflammation, which in turn results in further damage to the surface, and in the absence

of treatment, the vicious cycle of inflammation becomes self-perpetuating, along with that of DED<sup>[24]</sup>.

Recent interest in the physiology and function of the MGs has emphasized their importance in maintaining a healthy tear film and ocular surface homeostasis. One of the key triggers that initiates the vicious cycle in DED is increased evaporation of the tear film. The lipid layer of the tear film is essential to maintain the integrity of the tear film between blinks and prevent desiccation of the ocular surface epithelium. In health, the normal secretions of the MGs, and a healthy blink mechanism allow expression of the appropriate amount of meibum onto the lid margin, from where it is spread across the tear film. In MGD, there can be excess secretion of the meibum which can contaminate the epithelial glycocalyx resulting in poor wettability, or there can be reduced secretion resulting in inadequate protection for the tear film and increased evaporation. If there is significant inflammation in the glands, the quality of the oil can be altered. This can also occur when there is excessive bacterial or *Demodex* infestation and this can affect the quality of the lipid film and result in irritation and inflammation. The changes in the MGs can be initiated by a number of causes, resulting in dysfunction, which can promote or worsen DED and inflammation<sup>[25]</sup>. In DED as well, the affected ocular surface epithelium releases cornified envelope precursors and these can cause keratinization of the MG orifices, resulting in MGD. These changes result in a vicious cycle of MGD changes, that become self-perpetuating with time. Thus, as with inflammation, while the temporal evolution of DED and MGD is not clear, it appears that MGD can both cause and result from DED<sup>[26]</sup>.

Although DED, inflammation, and MGD have their own vicious cycles of causation and perpetuation, they are interlinked and share some common pathophysiology (Figure 1). Thus, in a chronic disease state, it appears that while one or more of these may be the trigger, gradually, recruitment of the others results in the co-occurrence of all three processes. Further, the interaction between these pathophysiologic cycles results in escalation and perpetuation of all the cycles, with resultant ocular surface damage driven by the inflammatory changes.

**Terminating Inflammation of the Ocular Surface** McMonnies<sup>[27]</sup> has suggested that risk factors for DED should be classified as modifiable and non-modifiable. An example of the former would be environmental conditions like exposure to low humidity environments, while the latter would be age- and sex-related changes in aqueous and lipid production. Identifying these risk factors would help address the specific mechanisms driving DED and inflammation in an individual patient. He suggests that inflammation can be categorized as that occurring on the ocular surface, in the lacrimal gland and in the MGs. The first is easily accessed by topical

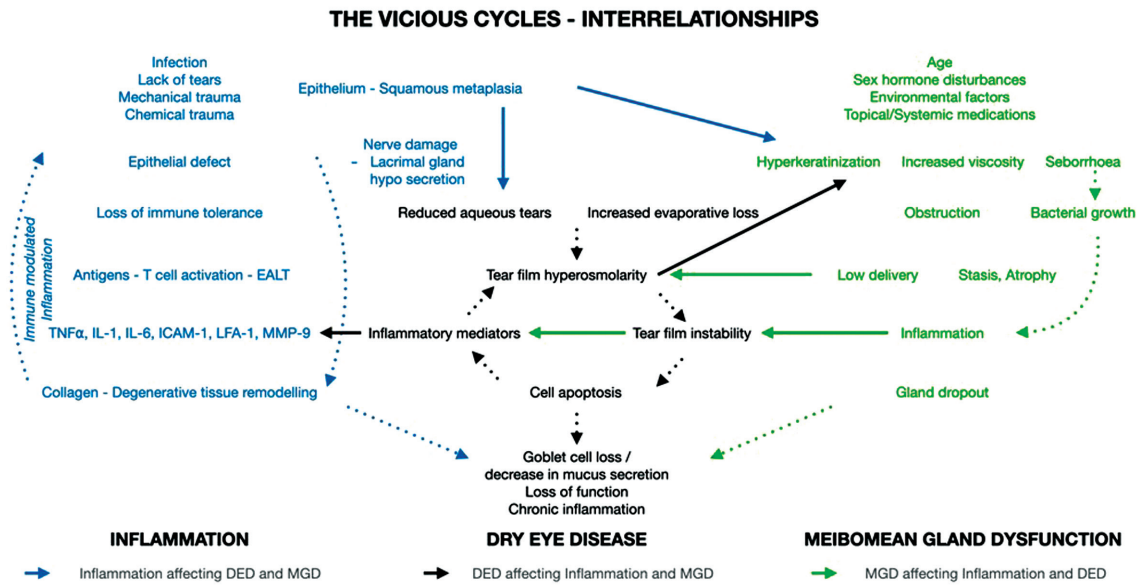


Figure 1 Vicious cycles of DED, inflammation and MGD and their relationships.

medications and hence may respond quickly. However, in the latter two conditions, the inflammation is harder to manage and may require increased frequency, dosage, and duration of topical treatment, with possible supplementation using oral medications as well.

It is clear that with time early DED becomes an irreversible chronic inflammatory condition exacerbated by reduced tear flow, increased tear evaporation and neural fatigue from repeated stimulation. It is also evident that without treatment, a self-perpetuating vicious cycle of inflammation results, which leads to a treatment-refractory disease and permanent damage to the ocular surface. Since the initiating factors are known, *viz.*, tear film instability and hyperosmolarity, an ideal treatment should help patients with early DED exit this vicious cycle, or ideally prevent them from entering it. Thus, it appears that treatment that is focused on eradicating tear film instability, inflammation and epithelial damage and promotes healing of the ocular surface, may restore normal homeostasis, and help the patient exit the cycle. Rolando *et al*<sup>[28]</sup> suggest that this can depend on the stage of disease at which the patient presents, as well as the subset of disease that is present. For *e.g.*, a patient with Sjögren's syndrome and a patient with DED following photo-refractive surgery may present with similar symptoms. However, the former is unlikely to resolve over time, while the latter is essentially a self-limited problem. They therefore suggest that DED be evaluated using the frequency of symptoms. 1) Sporadic: when the symptoms are present in specific situations, but not constant; 2) Intermittent: when symptoms are present all or most of the time in specific situations; 3) Persistent: when symptoms occur almost daily but do not last all day long; and 4) Permanent (chronic): when symptoms occur daily and last almost all day long.

They suggest that in the first two conditions, it may be possible for the patient to exit the vicious cycle, unlike the latter two conditions, where the ability to compensate for the ocular surface changes may have been lost and this is essentially a condition that requires prolonged or lifelong therapy.

**Clinical Evaluation of Ocular Surface Inflammation** With increasing knowledge of various conditions that impact the ocular surface and result in the three distinct but inter-related vicious cycles of DED, inflammation and MGD, the triggers for each must be considered when evaluating a patient with ocular surface inflammation. Factors that can affect these have been listed in detail in the DEWS II report, and include increasing age, female sex, contact lens wear, allergies, infections of the conjunctiva, topical or systemic medications, sex hormone imbalances, ocular surgery, neurotrophs, Sjögren's syndrome and other autoimmune conditions, systemic conditions like Parkinsonism and thyroid eye disease, conjunctivochalasis or lid margin abnormalities, poor blink, and environmental conditions of low humidity. Apart from examining tear function, and the presence of anterior and posterior lid margin inflammation, an awareness of these other factors can help categorize the patients and allow for a better management of ocular surface inflammation.

**Tests for Ocular Surface Inflammation** It is obviously important to recognize the presence of ocular surface inflammation. Clinically, conjunctival hyperemia is a simple, but effective sign of inflammation of the ocular surface. The location and extent of the redness associated with the presence of edema provides clues as the cause and severity of the inflammation. In ocular surface inflammation related to DED, the redness is diffuse, and the extent can either be graded semi-quantitatively or by using photographic standards like

the Efron or CCLRU scales. The quantification can also be done with the help of an automated measurement and digital image analysis. If the inflammation is intraocular as in uveitis, the redness is often more in the circumcorneal region, while in scleritis and episcleritis it is more often localized to the inflamed area. In conjunctivitis, the redness in the palpebral conjunctiva often exceeds that in the bulbar conjunctiva and there is associated watering or discharge depending on the cause of the infection. Redness limited to the superior limbal and bulbar conjunctiva suggests limbic keratoconjunctivitis, while that limited to the inferior bulbar conjunctiva often with conjunctival staining, suggests medication toxicity.

A study by Yang *et al*<sup>[29]</sup> noted that conjunctival staining with lissamine green using the SICCA grading system was useful in measuring the extent of ocular surface inflammation. They correlated the staining scores with the levels of interferon- $\gamma$ , IL-6, IL-17, and MMP-9 in two groups of patients with non-Sjögren's syndrome DED and Sjögren's syndrome DED. Although corneal staining scores with fluorescein showed positive correlations with interferon- $\gamma$ , IL-17, and MMP-9, the correlation coefficients were lower than that seen with conjunctival staining<sup>[29]</sup>.

Another sign that has been described is the presence of lid parallel conjunctival folds (LIPCOF), and their number and height can vary depending on the severity and duration of the chronic inflammatory DED. They are most often seen adjacent to the temporal corner of the lower lid and may explain the irritation that often occurs in this area. They are believed to occur due to the effect of the increased amounts of MMP-9, which dissolve the extracellular matrix of the conjunctiva to create space for the activity of the leucocytes at the site of the defense action. The increased friction during blinking in eyes with less tears, causes the loosened conjunctiva to form folds along the lid margin<sup>[30]</sup>.

Apart from these clinical signs, the use of point-of-care tests like the tear lab analysis device (TearLab Corp, Escondido, CA, USA) to measure tear osmolarity, or the Inflamm Dry (Quindel Inc, San Diego, CA, USA) to detect the presence of MMP-9 at levels greater than 40 ng/mL can be used as objective markers of inflammation on the ocular surface. There are tests being developed for other biomarkers of inflammation as well. Confocal microscopy can be used to look for the presence of inflammatory cells, epithelial changes, and the nerve plexus in such eyes<sup>[31]</sup>. Although these tests provide objective measures, the cost of the device and the per test cost are deterrents for their routine clinical use, apart from issues with the collection of tear samples without reflex tearing, and the variability in the osmolarity values with diurnal changes and also with repeat testing. MMP-9 is one of the markers for inflammation, and since the test only detect values higher than

40 ng/mL (normal values are 10 ng/mL), early inflammation may be missed. There is also the possibility that in some eyes the inflammation may produce markers other than MMP-9, while in some eyes MMP-9 can be produced in conditions other than DED. One of the ways that these tests can be useful however, is when the osmolarity is normal in an eye with elevated MMP-9 and this may suggest that the inflammation is due to causes other than DED.

**Treatment of Ocular Surface Inflammation** Various options are available to treat inflammation in DED. These include tear substitutes which help to counter the hyperosmolarity, replenish tear volume on the surface, reduce friction-related damage to the ocular surface, and aid in diluting and removing noxious stimuli from the ocular surface, especially if there is significant blepharitis and MGD. Various options are available and the discussion of the choice of these is beyond the scope of this article. In eyes with less mucus, mucin analogues like Rebamipide and Diquafosol can be tried. Oral pilocarpine can be used as a secretagogue.

In MGD, the traditional methods of treatment have included heat, massage, and antibiotic ointments, and these can now be performed using devices such as Lipiflow. A more recent approach is the use of pulsed light therapy to induce the MGs to produce secretions that have a more physiological composition. Probing of the glands has also been described when there is meibomian sicca. In addition to these, the use of azithromycin ointment has been found to be helpful and if there is significant *Demodex* infestation, tea tree oil can be used<sup>[32]</sup>. Oral macrolide antibiotics like tetracycline, doxycycline, and azithromycin have antibacterial and anti-inflammatory properties and are helpful as lipid-modifying agents in MGD.

In evaporative DED, tear products that contain lipids can be useful, and if unavailable, using punctal occlusion strategies can help. When this is done however, there can be an associated increase in inflammation since tear drainage has been affected and hence a short course of a low-potency steroid eye drops like fluorometholone or loteprednol must be added. Steroids work on all arms of the inflammatory process in the ocular surface and are hence very effective but cannot be used in the long-term as this is associated with various side effects.

When long term control of inflammation is desired, 0.05% or 0.1% cyclosporine A (CsA) drops, 0.03% or 0.1% tacrolimus ointment and 5% Lifitegrast can prove helpful. These work to reduce T-cell activity and hence suppress inflammation. Of these, the most experience is with 0.05% CsA drops, and therapy should last at least 6 to 12mo to obtain an optimal effect. If no effect is noted after 6mo of use, then it should be discontinued, and another approach must be tried. It has been noted that there is a 40% risk of relapse of symptoms on

cessation of therapy and therefore CsA must be tapered and stopped over several weeks. If symptoms recur, CsA must be started again as quickly as possible. When initiating treatment with CsA drops, they are often combined with a low-potency topical steroid and this has been termed “bridging”. Since CsA drops take 3 to 6wk to act, the addition of the steroid provides more rapid resolution of the inflammation at the start. CsA drops are also irritating on application, and the concomitant use of steroids may help increase acceptance. In conditions like Sjögren’s syndrome, it may not be possible to discontinue the CsA drops as the underlying systemic condition maintains the inflammation on the ocular surface<sup>[33]</sup>.

Other options include topical vitamin A ointment, auto serum tears in advanced surface damage, and oral immunosuppressives in systemic disease. However, as with the use of long-term topical and oral steroids, immunosuppressive use can be associated with significant side effects, and these must be monitored for and appropriate therapy modification or cessation must be considered if these changes occur. Modifying the ocular and general environmental factors and altering the topical and oral medications where possible, can also help<sup>[31]</sup>. The role of nutrition and nutritional supplements including omega-3 fatty acids, vitamins A, B12, C, D, selenium, curcumin and flavonoids continue to be explored<sup>[34]</sup>. Surgical measures to reconstruct the ocular surface may be considered in eyes with advanced damage.

**Consequences of Inadequately Treated Ocular Surface Inflammation** As mentioned in the previous section, multiple options exist to treat patients with inflammation of the ocular surface. However, the treatment should be tailored to each patient based on the assessment of the causative factors, the stage and severity of the disease, underlying systemic conditions, and patient symptomatology. The goals of treatment would be to eradicate the causative noxious stimuli where possible, and if that is not possible to quell or reduce the inflammation using the options available. The treatment must aim to reduce tear hyperosmolarity, heal the ocular surface, provide sufficient lubrication, and reduce inflammation and patient symptomatology.

In patients presenting early, aggressive treatment can be considered with the goal of exiting the patient from the vicious cycle, while in the more chronic cases, a tempered approach with the idea of maintaining the health of the ocular surface must be considered. Systemic conditions must be appropriately managed, often in conjunction with the appropriate specialist. Hence, while ocular inflammation is invariably an accompaniment of DED, its management must be considered on an individual basis. A proper assessment of the conditions present and the available treatment options in the clinical setting must be considered, and a mesh approach trying to

match the two must be adopted. It is important for both the patient and the ophthalmologist to recognize that DED is a chronic condition, which if improperly treated, can result in an escalating cascade of inflammation and ocular surface damage. Hence, while tear substitutes are used, it is also necessary to control inflammation and to recognize other aggravating and contributory factors, which must also be adequately treated.

#### **FUTURE**

Much research is being done on various aspects of DED and inflammation, and the future focus will be on identifying important biomarkers that are responsible for the changes we see on the ocular surface, developing non-invasive methods to investigate the pathogenesis and severity of various types of dry eye, which will also allow better monitoring of the patient’s condition over time and the response to therapy. A recent study in a mouse model of dry eye suggested that corneal autophagy was involved in ocular surface inflammation. Treatment with inhibitors of autophagy resulted in increased levels of inflammation, and the authors suggest that agents that regulate autophagy may have a role in relieving ocular surface inflammation<sup>[35]</sup>. It is possible that the recognition of the important molecular and chemical agents that take part in the inflammatory cascade on the ocular surface will allow the development of newer treatment strategies targeting these actions.

#### **ACKNOWLEDGEMENTS**

Allergan India provided travel support and logistics for discussions among the authors that facilitated the writing of this manuscript. We acknowledge TuracoZ Healthcare Solutions ([www.turacoZ.com](http://www.turacoZ.com)) for support in the preparation of this manuscript.

**Conflicts of Interest:** Rao SK, None; Mohan R, None; Gokhale N, None; Matalia H, None; Mehta P, None.

#### **REFERENCES**

- 1 The definition and classification of dry eye disease: report of the Definition and Classification Subcommittee of the International Dry Eye WorkShop (2007). *Ocul Surf* 2007;5(2):75-92.
- 2 Gipson IK. The ocular surface: the challenge to enable and protect vision: the Friedenwald lecture. *Invest Ophthalmol Vis Sci* 2007;48(10):4390; 4391-4398.
- 3 Schein OD, Muñoz B, Tielsch JM, Bandeen-Roche K, West S. Prevalence of dry eye among the elderly. *Am J Ophthalmol* 1997; 124(6):723-728.
- 4 The epidemiology of dry eye disease: report of the Epidemiology Subcommittee of the International Dry Eye WorkShop (2007). *Ocul Surf* 2007;5(2):93-107.
- 5 Nichols KK, Foulks GN, Bron AJ, Glasgow BJ, Dogru M, Tsubota K, Lemp MA, Sullivan DA. The international workshop on meibomian gland dysfunction: executive summary. *Invest Ophthalmol Vis Sci* 2011;52(4):1922-1929.

- 6 Franck C, Palmvang IB. Break-up time and lissamine green epithelial damage in 'office eye syndrome'. Six-month and one-year follow-up investigations. *Acta Ophthalmol (Copenh)* 1993;71(1):62-64.
- 7 Scott A, Khan KM, Cook JL, Duronio V. What is "inflammation"? Are we ready to move beyond Celsus? *Br J Sports Med* 2004;38:248-249.
- 8 Thoo L, Noti M, Krebs P. Keep calm: the intestinal barrier at the interface of peace and war. *Cell Death Dis* 2019;10(11):849.
- 9 Jiminez JA, Uwiera TC, Douglas Inglis G, Uwiera RR. Animal models to study acute and chronic intestinal inflammation in mammals. *Gut Pathog* 2015;7:29.
- 10 Damato BE, Allan D, Murray SB, Lee WR. Senile atrophy of the human lacrimal gland: the contribution of chronic inflammatory disease. *Br J Ophthalmol* 1984;68(9):674-680.
- 11 de Paiva CS, Pangelinan SB, Chang E, Yoon KC, Farley WJ, Li DQ, Pflugfelder SC. Essential role for c-Jun N-terminal kinase 2 in corneal epithelial response to desiccating stress. *Arch Ophthalmol* 2009;127(12):1625-1631.
- 12 Knop E, Knop N, Brewitt H. Dry eye disease as a complex dysregulation of the functional anatomy of the ocular surface. New concepts for understanding dry eye disease. *Ophthalmologe* 2003;100(11):917-928.
- 13 Yoshida A. Lymphocytic infiltration of the conjunctiva and the salivary gland in Sjögren's syndrome. *Arch Ophthalmol* 1993;111(1):21.
- 14 He JL, Ogawa Y, Mukai S, Saijo-Ban Y, Kamoi M, Uchino M, Yamane M, Ozawa N, Fukui M, Mori T, Okamoto S, Tsubota K. *In vivo* confocal microscopy evaluation of ocular surface with graft-versus-host disease-related dry eye disease. *Sci Rep* 2017;7(1):10720.
- 15 Ban Y, Ogawa Y, Ibrahim OMA, Tatematsu Y, Kamoi M, Uchino M, Yaguchi S, Dogru M, Tsubota K. Morphologic evaluation of meibomian glands in chronic graft-versus-host disease using *in vivo* laser confocal microscopy. *Mol Vis* 2011;17:2533-2543.
- 16 Tsubota K, Yokoi N, Shimazaki J, Watanabe H, Dogru M, Yamada M, Kinoshita S, Kim HM, Tehah HW, Hyon JY, Yoon KC, Seo KY, Sun XG, Chen W, Liang LY, Li MW, Liu ZG, Society ADE. New perspectives on dry eye definition and diagnosis: a consensus report by the Asia dry eye society. *Ocul Surf* 2017;15(1):65-76.
- 17 Nakamura S, Kinoshita S, Yokoi N, Ogawa Y, Shibuya M, Nakashima H, Hisamura R, Imada T, Imagawa T, Uehara M, Shibuya I, Dogru M, Ward S, Tsubota K. Lacrimal hypofunction as a new mechanism of dry eye in visual display terminal users. *PLoS One* 2010;5(6):e11119.
- 18 Kamoi M, Ogawa Y, Nakamura S, *et al.* Accumulation of secretory vesicles in the lacrimal gland epithelia is related to non-Sjögren's type dry eye in visual display terminal users. *PLoS One* 2012;7(9):e43688.
- 19 Kamoi M, Ogawa Y, Nakamura S, Dogru M, Nagai T, Obata H, Ito M, Kaido M, Kawakita T, Okada Y, Kawakami Y, Shimmura S, Tsubota K. Accumulation of secretory vesicles in the lacrimal gland epithelia is related to non-Sjögren's type dry eye in visual display terminal users. *PLoS One* 2012;7:e43688.
- 20 Stern ME, Schaumburg CS, Pflugfelder SC. Dry eye as a mucosal autoimmune disease. *Int Rev Immunol* 2013;32(1):19-41.
- 21 de Paiva CS, Corrales RM, Villarreal AL, Farley WJ, Li DQ, Stern ME, Pflugfelder SC. Corticosteroid and doxycycline suppress MMP-9 and inflammatory cytokine expression, MAPK activation in the corneal epithelium in experimental dry eye. *Exp Eye Res* 2006;83(3):526-535.
- 22 Yagi Y, Andoh A, Inatomi O, Tsujikawa T, Fujiyama Y. Inflammatory responses induced by interleukin-17 family members in human colonic subepithelial myofibroblasts. *J Gastroenterol* 2007;42(9):746-753.
- 23 Corrales RM, de Paiva CS, Li DQ, Farley WJ, Henriksson JT, Bergmanson JPG, Pflugfelder SC. Entrapment of conjunctival goblet cells by desiccation-induced cornification. *Invest Ophthalmol Vis Sci* 2011;52(6):3492-3499.
- 24 Knop E, Knop N. Inflammation in dry eye disease - information on diagnostic testing and therapy using the scientific online information. *Klin Monbl Augenheilkd* 2020;237:627-636.
- 25 Mizoguchi S, Iwanishi H, Arita R, Shirai K, Sumioka T, Kokado M, Jester JV, Saika S. Ocular surface inflammation impairs structure and function of meibomian gland. *Exp Eye Res* 2017;163:78-84.
- 26 Baudouin C, Messmer EM, Aragona P, Geerling G, Akova YA, Benítez-del-Castillo J, Boboridis KG, Merayo-Llodes J, Rolando M, Labetoulle M. Revisiting the vicious circle of dry eye disease: a focus on the pathophysiology of meibomian gland dysfunction. *Br J Ophthalmol* 2016;100(3):300-306.
- 27 McMonnies CW. Dry eye disease immune responses and topical therapy. *Eye Vis (Lond)* 2019;6:12.
- 28 Rolando M, Zierhut M, Barabino S. Should we reconsider the classification of patients with dry eye disease? *Ocul Immunol Inflamm* 2021;29(3):521-523.
- 29 Yang S, Lee HJ, Kim DY, Shin S, Barabino S, Chung SH. The use of conjunctival staining to measure ocular surface inflammation in patients with dry eye. *Cornea* 2019;38(6):698-705.
- 30 Meller D, Li DQ, Tseng SC. Regulation of collagenase, stromelysin, and gelatinase B in human conjunctival and conjunctivochalasis fibroblasts by interleukin-1beta and tumor necrosis factor-alpha. *Invest Ophthalmol Vis Sci* 2000;41(10):2922-2929.
- 31 Pleyer U, Geerling G, Schrader S, *et al.* If artificial tears are not enough. The importance of inflammatory processes in dry eye disease. Practical aspects of anti-inflammatory therapy of dry eye disease. *Klin Monbl Augenheilkd* 2020;237:655-658.
- 32 Luo XH, Li J, Chen C, Tseng S, Liang LY. Ocular demodicosis as a potential cause of ocular surface inflammation. *Cornea* 2017;36(Suppl 1):S9-S14.
- 33 Hossain P. Cyclosporine in ocular surface inflammation. *Eye (Lond)* 2017;31(5):665-667.
- 34 Pellegrini M, Senni C, Bernabei F, Cicero AFG, Vagge A, Maestri A, Scordia V, Giannaccare G. The role of nutrition and nutritional supplements in ocular surface diseases. *Nutrients* 2020;12(4):E952.
- 35 Ma SS, Yu Z, Feng SF, Chen HJ, Chen HY, Lu XH. Corneal autophagy and ocular surface inflammation: a new perspective in dry eye. *Exp Eye Res* 2019;184:126-134.