

Combined central retinal artery and vein occlusion associated with primary antiphospholipid syndrome treated by injection of dexamethasone intravitreal implant and anticoagulant therapy: a case report

Bing-Wen Lu, Li-Ke Xie, Xiao-Feng Hao, Xiao-Yan Zhang, Jie Luo

Department of Ophthalmology, Ophthalmology Hospital of China Academy of Traditional Chinese Medicine, Beijing 100040, China

Correspondence to: Li-Ke Xie. Department of Ophthalmology, Ophthalmology Hospital of China Academy of Traditional Chinese Medicine, 33 Lugu Road, Shijingshan District, Beijing 100040, China. bjxielike@sina.com

Received: 2022-01-08 Accepted: 2022-02-25

DOI:10.18240/ijo.2022.06.25

Citation: Lu BW, Xie LK, Hao XF, Zhang XY, Luo J. Combined central retinal artery and vein occlusion associated with primary antiphospholipid syndrome treated by injection of dexamethasone intravitreal implant and anticoagulant therapy: a case report. *Int J Ophthalmol* 2022;15(6):1027-1029

Dear Editor,

We present a case of combined central retinal artery and vein occlusion associated with primary antiphospholipid syndrome (APS) treated by injection of dexamethasone intravitreal implant (Ozurdex®) and anticoagulant therapy. Written informed consent was obtained by the patient to allow publication of this case. The study was conducted in accordance with the tenets of the Declaration of Helsinki.

APS is an autoimmune thrombophilic state characterized by multi-organ arterial and/or venous thrombosis and/or pregnancy morbidity, associated with circulating antiphospholipid antibodies (aPL) including lupus anticoagulant, anticardiolipin (aCL), and anti-β₂-glycoprotein antibody^[1]. Primary APS occurs in patients without any underlying disorders, whereas secondary APS is accompanied by autoimmune diseases, most commonly systemic lupus erythematosus (SLE)^[2].

The most common ocular involvement in APS includes retinal artery or vein occlusion, arterial ischemic optic neuropathy, and retinal vasculitis^[3]. Presentation of a combination of central retinal artery occlusion (CRAO) and central retinal vein

occlusion (CRVO) in primary APS is extremely rare, which could not be diagnosed until the ocular symptom occurred.

A 12-year-old female visited our hospital because of a sudden loss of vision in her right eye for 2wk. One day before the initial onset, a similar symptom lasting an hour occurred in the same eye, but spontaneously recovered. She denied any history of connective tissue disease or other systemic illness, nor did she have a history of drug abuse. Family history was also unremarkable.

Ophthalmic examination revealed that her best corrected visual acuity (BCVA) was 6/60 in the right eye and 6/6 in the left eye. A relative afferent pupillary defect was seen in the right eye. Slit-lamp examination in both eyes was normal. The right fundus showed engorged and tortuous retinal veins, diffuse flame-shaped retinal hemorrhages, hard exudates, cotton-wool-spots, a pale and edematous retina and a swollen disc (Figure 1A), whereas the left fundus appeared normal (Figure 1B). Mild macular edema and significantly reduced macular perfusion in the right eye was revealed by optical coherence tomography angiography (OCTA; Figure 2A). Macular sensitivity of the right eye, measured by microperimetry, was remarkably reduced when compared to the left eye (Figure 3A). Ischemic areas in OCTA, especially the deep capillary layer, correlated with lower macular sensitivity on microperimetry.

Multiple clinical and laboratory investigations were performed to determine the underlying causative disease. She was investigated for cardiovascular diseases, hyperlipidemia, diabetes, hypertension, infections, and autoimmune disorders. The echocardiogram revealed clinically insignificant mild tricuspid regurgitation. Duplex carotid ultrasonography appeared normal on both sides. Laboratory investigations included complete blood count, erythrocyte sedimentation rate, serum lipids, antineutrophilic cytoplasmic antibodies, homocysteine, rheumatoid factors, aPL, and functional assays for protein C and protein S to detect the hypercoagulable state. All the investigations were relatively normal except that

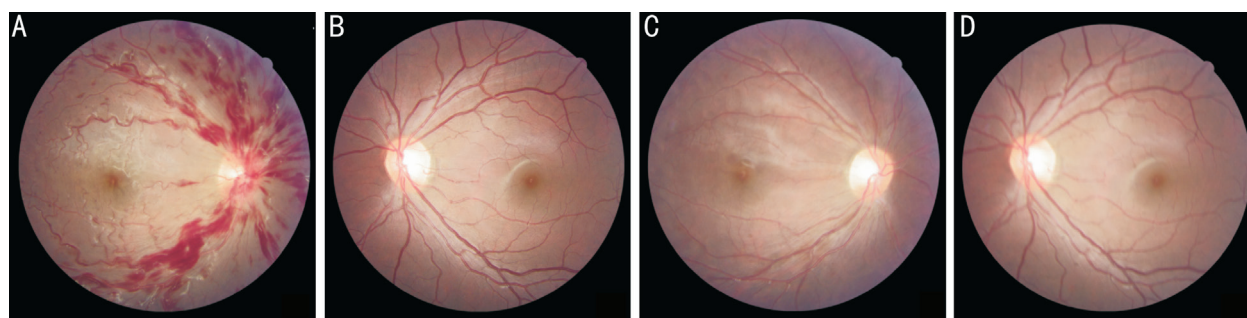


Figure 1 Fundus examination of the 12-year-old female patient A: Fundus color photograph of the right eye at the first examination; B: Fundus color photograph of the left eye at the first examination; C: Fundus color photograph of the right eye in the following 4wk; D: Fundus color photograph of the left eye in the following 4wk.

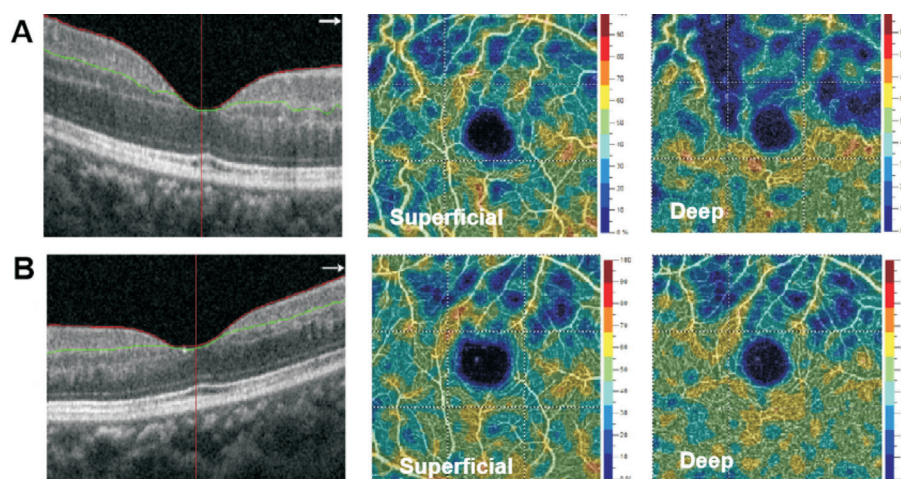


Figure 2 OCTA examination of the right eye of the 12-year-old female patient A: OCTA map of the macular area at the first examination; B: OCTA map of the macular area in the following 4wk. OCTA: Optical coherence tomography angiography.

the level of anti- β 2-glycoprotein antibody was 31.46 RU/mL (normal <20 RU/mL). Although not included in the diagnostic criteria^[4], the value of anti- β 2-glycoprotein antibody has a high specificity for APS^[5]. Therefore, the diagnosis of primary APS was conjectured based on positive serum anti- β 2-glycoprotein antibody and clinical manifestation of retinal thrombosis.

The young patient was hospitalized and immediately referred to a hematologist, under whose guidance, oral anticoagulants of 150 mg aspirin was given per day. Intravitreal injection of dexamethasone intravitreal implant was given on the second day of admission. In the following 4wk, her BCVA of the right eye recovered from 6/60 to 6/6, the flame-shaped retinal hemorrhages as well as retinal edema regressed gradually to a normal appearance (Figure 1C, 1D), the average macular sensitivity of the right eye improved from 10.3 to 15.2 dB (Figure 3B), and macular perfusion greatly improved in both capillary layers except for few ischemic areas above the macula (Figure 2B). Intravitreal dexamethasone was safe and well tolerated since there were no significant complications such as intraocular pressure hypertension and cataract during the follow-up. After being discharged from hospital, she was closely followed up for more than 1y, and prothrombin time

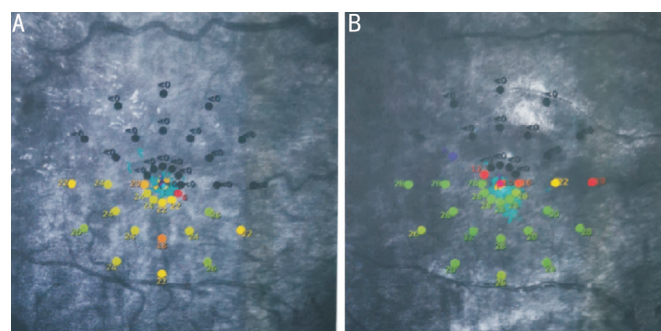


Figure 3 Macular sensitivity map of the right eye of the 12-year-old female patient A: Macular sensitivity map at the first examination; B: Macular sensitivity map in the following 4wk.

was regularly monitored during her visits. The retina regained a normal appearance and no further thrombotic event occurred after 2mo of intravitreal injection. During the 1-year follow-up, repeated serologic studies showed that serum anti- β 2-glycoprotein antibody had returned to normal. Her rapid recovery suggests that prompt diagnosis and treatment of ocular symptoms associated with this disease is essential for recovery of retinal function and morphology. The pathogenesis of primary APS is complex and multi-factorial.

One recent study suggested that retinal vein occlusion could behave as an organ-specific manifestation of APS^[6]. Traditional medications that have been implemented for the treatment of primary APS include anticoagulant therapy. More recently, anti-vascular endothelial growth factor (VEGF) therapies have been introduced as an acceptable alternative to alleviate ocular symptoms^[7]. Since various factors are involved in its pathogenesis, among which inflammation plays an important role, we believe that Ozurdex, an approved dexamethasone intravitreal implant, might be more effective in alleviating macular edema and improving visual acuity based on its anti-inflammatory mechanism, which is key in initiating procoagulant activity^[8].

In summary, we present a case of combined CRAO and CRVO in a patient with primary APS. Prompt diagnosis and treatment of ocular symptoms associated with this disease is detrimental. Despite anticoagulation therapy, the patient was treated by injection of dexamethasone intravitreal implant (Ozurdex[®]), illustrating the effectiveness of anti-inflammatory agents. This case emphasized the importance of systemic evaluation, in patients with combined CRAO and CRVO without conventional risk factors, especially in atypical young patients.

ACKNOWLEDGEMENTS

Foundations: Supported by National Natural Science Foundation of China (No.82174445); Natural Science Foundation of Beijing of China (No.7192235).

Conflicts of Interest: Lu BW, None; Xie LK, None; Hao XF, None; Zhang XY, None; Luo J, None.

REFERENCES

- 1 Sammaritano LR. Antiphospholipid syndrome. *Best Pract Res Clin Rheumatol* 2020;34(1):101463.
- 2 Kokosi M, Lams B, Agarwal S. Systemic lupus erythematosus and antiphospholipid antibody syndrome. *Clin Chest Med* 2019;40(3): 519-529.
- 3 Suvajac G, Stojanovich L, Milenkovich S. Ocular manifestations in antiphospholipid syndrome. *Autoimmun Rev* 2007;6(6):409-414.
- 4 Wilson WA, Gharavi AE, Koike T, Lockshin MD, Branch DW, Piette JC, Brey R, Derksen R, Harris EN, Hughes GR, Triplett DA, Khamashta MA. International consensus statement on preliminary classification criteria for definite antiphospholipid syndrome: report of an international workshop. *Arthritis Rheum* 1999;42(7):1309-1311.
- 5 Audrain MAP. Value of autoantibodies to beta2-glycoprotein 1 in the diagnosis of antiphospholipid syndrome. *Rheumatology* 2002;41(5): 550-553.
- 6 Hernández JL, Sanlés I, Pérez-Montes R, Martínez-Taboada VM, Olmos JM, Salmón Z, Sierra I, Escalante E, Napal JJ. Antiphospholipid syndrome and antiphospholipid antibody profile in patients with retinal vein occlusion. *Thromb Res* 2020;190:63-68.
- 7 Jabrane M, Ez-Zahraoui MR, Hajji I, Fadili W, Moutaouakil A, Laouad I. Central retinal vein occlusion in a patient on hemodialysis secondary to antiphospholipid syndrome: case report. *Nephrol Ther* 2017;13(4):245-247.
- 8 Mathis T, Cerquaglia A, Weber M, Guillarme-Sallit R, Malclès A, Voirin N, Servant M, Sudhalkar A, Bilgic A, Denis P, Sève P, Bodaghi B, Kodjikian L. Uveitis treated with dexamethasone implant. *Retina* 2021;41(3):620-629.