

Comparison of minimally invasive glaucoma surgery with trabecular micro-bypass stent and microhook *ab interno* trabeculotomy performed in conjunction with cataract surgery

Naoto Tokuda, Yasushi Kitaoka, Ayaka Tsukamoto, Yasuhiro Toyoda, Yusuke Yamada, Kana Sase, Hitoshi Takagi

Department of Ophthalmology, St Marianna University School of Medicine, 2-16-1 Sugao Miyamae-ku Kawasaki-shi, Kanagawa 216-8851, Japan

Correspondence to: Naoto Tokuda. Department of Ophthalmology, St Marianna University School of Medicine, 2-16-1 Sugao Miyamae-ku Kawasaki-shi, Kanagawa 216-8851, Japan. tokunao@nifty.com

Received: 2021-04-08 Accepted: 2022-01-26

Abstract

• **AIM:** To evaluate the effectuality and safety of cataract surgery combined with either *ab interno* trabeculotomy by the microhook (μ LOT) or a single iStent[®] trabecular bypass implantation (iStent) in eyes with cataract and mild-to-moderate glaucoma.

• **METHODS:** This study enrolled subjects with mild-to-moderate open angle glaucoma with visually significant cataract who used two or more ophthalmic antiglaucoma agents between 60 and 90y of age. Patients underwent cataract surgery cooperated with either implantation of an iStent (iStent-phaco) or excisional goniotomy with the μ LOT (μ LOT-phaco). Patients underwent μ LOT-phaco in the eye with lower the mean deviation, according to the Humphrey field analyzer, while iStent-phaco was carried out on the other eye. Intraocular pressure (IOP) pre- and post-surgery, alterations in anterior chamber flare (ACF), and corneal endothelial cell density (ECD) were estimated.

• **RESULTS:** Twenty subjects were enrolled (mean age: 73.6 ± 7.3 y). The mean medicated preoperative IOP was 16.7 mm Hg in the μ LOT and 16.2 mm Hg in the iStent eyes. The mean final IOP at 12mo was 13.6 mm Hg in the μ LOT eyes and 13.6 mm Hg in the iStent eyes, representing a 17.8% and 17.2% reduction, respectively. The preoperative ACF in the μ LOT eyes was 9.5 pc/ms and it returned to normal in 30d postoperatively, with a value of 11.4 pc/ms. In the iStent eyes, ACF was 9.6 pc/ms preoperatively and it returned to normal by 7d postoperatively (11.2 pc/ms at

day 7), demonstrating that postoperative inflammation was less in the iStent eyes. The corneal ECD in both groups was not significantly decreased.

• **CONCLUSION:** In this study, iStent and μ LOT are both effective through 12mo of follow-up. Safety is more favorable in the iStent eyes, based on early anterior chamber inflammation.

• **KEYWORDS:** minimally invasive glaucoma surgery; iStent; *ab interno* trabeculotomy

DOI:10.18240/ijo.2022.07.07

Citation: Tokuda N, Kitaoka Y, Tsukamoto A, Toyoda Y, Yamada Y, Sase K, Takagi H. Comparison of minimally invasive glaucoma surgery with trabecular micro-bypass stent and microhook *ab interno* trabeculotomy performed in conjunction with cataract surgery. *Int J Ophthalmol* 2022;15(7):1082-1088

INTRODUCTION

In recent years, minimal invasiveness has become a focus point in surgery, including in glaucoma surgery. Minimally invasive glaucoma surgery (MIGS)^[1] does not require conjunctival incision or scleral flap incision that is performed in trabeculectomy. MIGS does not have the same excellent intraocular pressure (IOP) reduction as trabeculectomy. However, MIGS is a safe glaucoma surgery because it does not cause serious complications, including filtering bleb infection^[2] and hypotonic maculopathy^[3], that are caused by trabeculectomy. MIGS include procedures using a Trabectome^[4], 360° *ab interno* trabeculotomy^[5], goniotomy with the Kahook Dual Blade^[6], microhook *ab interno* trabeculotomy (μ LOT)^[7], and others. In our hospital, μ LOT is often carried out in subjects with early to middle stage glaucoma in consideration of efficacy, safety, and cost.

In MIGS, there is also a method for implanting the device in the eye. The iStent[®] trabecular micro-bypass stent (Glaukos Corporation, Laguna Hills, CA, USA) is used when implanting titanium micro shunts into the trabecular meshwork. The

concept of this method is to reduce the IOP by reconstructing the flow of aqueous humor into the trabecular meshwork or Schlemm's canal by decreasing the resistance of the trabecular meshwork^[8]. The iStent can lower the IOP and decreased reliance on IOP-reducing drugs compared to cataract surgery alone^[9-10]. The iStent has been approved by the US Food and Drug Administration (FDA) for use only in combination with cataract surgery (iStent-phaco).

The effectuality and safety of the iStent-phaco and of μ LOT cooperated with cataract surgery (μ LOT-phaco) have been reported separately^[7-11], but there has been no report comparing the effects of μ LOT-phaco and iStent-phaco. Comparison of the iStent-phaco and μ LOT-phaco in the right and left eyes of the same patient would allow more detailed examination. In addition, there has been no report regarding to the anterior chamber inflammation in comparison between these surgeries. Therefore, in this study, we performed iStent-phaco in one eye and μ LOT-phaco in the other eye of the same patient and evaluated the anterior chamber inflammation and compared the effects and complications of these two MIGS procedures.

SUBJECTS AND METHODS

Ethical Approval This retrospective clinical cohort study was approved by the local ethics committee (St Marianna University School of Medicine Ethics Committee, certificate approval number: 4029) and adhered to the regulations of good clinical practice and the tenets of the Declaration of Helsinki. All patients provided written informed consent for participation in the study.

Study Design Patients underwent cataract surgery (Constellation Vision System: Alcon) cooperated with implantation of an iStent (iStent-phaco) in one eye and excisional goniotomy with the μ LOT (μ LOT-phaco) in other eye by a single surgeon (Tokuda N) at the St Marianna University School of Medicine, between June 2017 and June 2019. The eye with lower the mean deviation (MD) was chosen for μ LOT-phaco. Patients were evaluated preoperatively and again at 1 and 3d, 1 and 2wk, and every month up to 1y postoperatively. Each investigation contained assessment of best-corrected visual acuity (BCVA), IOP, and number of ophthalmic antiglaucoma agents used. We delineated failure conforming to the post-operation IOP levels with or without ophthalmic antiglaucoma agents after surgery: <20% reduction from the baseline IOP, or IOP>18 mm Hg.

Patients underwent measurement of the corrected visual acuity using Landolt vision charts. IOP was estimated by Goldmann applanation tonometry. Inflammation in the anterior chamber was evaluated by using the anterior chamber flare (ACF; FC-2000[®] laser flare meter, Kowa, Japan). Corneal endothelial cell density (ECD) was measured by noncontact specular

microscopy (Noncon Robo SP-8000; Konan Medical, Japan). Gonioscopy was carried out before operation and at every postoperative visit to estimate the angle and stent positioning. Data were analyzed using IBM SPSS Statistics 21 (IBM Corporation, Poughkeepsie, NY, USA). Parameters were analyzed using 2-tailed Student's *t*-tests and Chi-squared tests, and $P<0.05$ were considered statistically significant.

Participants The trial enrolled subjects with mild-to-moderate (the Hodapp-Parrish-Anderson visual field criteria: MD \geq -6.0 dB, mild; -6.0>MD \geq -12.0 dB, moderate)^[12] open angle glaucoma [containing primary open angle glaucoma (POAG), pseudo-exfoliative glaucoma (PXG), combined-mechanism glaucoma (CMG)] with visually significant cataract who were treated with two or more ophthalmic antiglaucoma agents. The diagnosis of open angle glaucoma was determined by a glaucoma specialist (Tokuda N) conforming to the Japan Glaucoma Society Guidelines for Glaucoma (4th edition)^[13] criteria. Preoperative visual fields were measured using the Swedish interactive threshold algorithm standard 30-2 program of the Humphrey field analyzer (Carl Zeiss-Meditec, Jena, Germany). Eyes were required to have anterior chamber angle grades II-IV (Shaffer classification), where at least the trabecular meshwork was observable by a gonioscope. Additionally, patients had to be aged between 60 and 90y for inclusion in the study. Exclusion criteria included recent (within 12mo) intraocular incisional glaucoma surgery or laser trabeculoplasty and active ocular inflammation, neovascular, traumatic, or angle-closure glaucoma.

Surgical Device and Implantation Technique In both the μ LOT-phaco and iStent-phaco groups, the glaucoma surgery was carried out before the cataract surgery.

The μ LOT was performed as previously reported^[7]. Viscoelastic material (Healon[®] Ophthalmic Viscoelastic Substance 1% AMO Japan K.K. Tokyo, Japan) was administered into the anterior chamber approaching corneal ports at the 3 and 10 o'clock locations. Using a gonioscope lens (Swan-Jacob lens, Ocular Instruments, Bellevue, WA, USA), a straight-type Tanito *ab interno* trabeculotomy hook (M-2215, Inami, Tokyo, Japan) was put into the anterior chamber approaching the corneal port, and the internal wall of the trabecular meshwork was cut open at the temporal and nasal quadrants (Figure 1).

A first-generation iStent was used, which is a single-piece titanium stent. Using the gonioscope lens to observe the nasal angle, the iStent was put into the anterior chamber approaching the corneal port. For iStent implantation, the iStent was passed through the trabecular meshwork to stay within Schlemm's canal, at which point it was delivered from its inserter, which was then used to gently press on the implant to seat its heel firmly in the canal (Figure 2).

Table 1 Preoperative patient (n=20) demographics

Parameters	iStent-phaco	μLOT-phaco	<i>P</i>	<i>n</i> (%)
Mean age (y)		73.6±7.3	-	
Right eye	15 (75.0)	5 (25.0)	0.004 ^b	
Men	5 (25.0)	15 (75.0)	0.004 ^b	
Systemic disorders				
Diabetes mellitus	4 (20.0)		-	
Hypertension	3 (15.0)		-	
Smoking	3 (15.0)		-	
Preop. logMAR visual acuity	0.04±0.11	0.12±0.18	0.087 ^a	
Preop. HFA MD (dB)	-3.9±2.4	-8.1±3.9	0.002 ^a	
Preop. IOP (mm Hg)	16.2±2.1	16.7±2.7	0.33 ^a	
Preop. number of medications	2.8±0.8	3.1±0.9	0.11 ^a	
Preop. the anterior chamber flare (pc/ms)	9.6±2.2	9.5±3.1	0.76 ^a	
Preop. corneal endothelial cell density (cells/mm ²)	2773±226	2751±159	0.62 ^a	
Preop. central corneal thickness (μm)	513±26	509±31	0.42 ^a	
Glaucoma type				
Primary open angle glaucoma	12 (60.0)		-	
Pseudoexfoliative glaucoma	1 (5.0)		-	
Combined-mechanism glaucoma	7 (35.0)		-	

^aStudent's *t*-test; ^bChi-squared test. iStent: iStent® trabecular micro-bypass stent; phaco: Phacoemulsification and aspiration; μLOT: Microhook *ab interno* trabeculotomy; HFA: Humphrey field analyzer; MD: Mean deviation; IOP: Intraocular pressure; logMAR: Logarithm of minimal angle. Combined-mechanism glaucoma have occludable angle, with a few peripheral anterior synechiae.




Figure 1 Intraoperative gonioscopic view of microhook *ab interno* trabeculotomy (μLOT) Straight type Tanito *ab interno* trabeculotomy hook was inserted through the corneal port, and the inner wall of the trabecular meshwork was incised at the temporal and nasal quadrants.

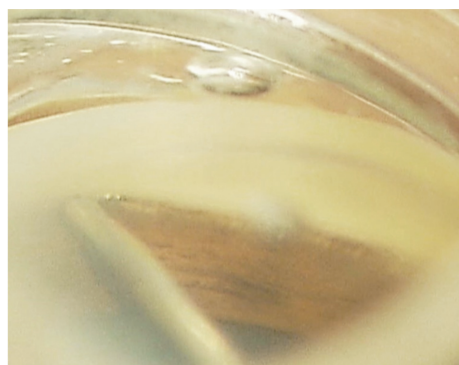


Figure 2 Intraoperative gonioscopic view of single iStent For iStent was inserted through the trabecular meshwork to rest within Schlemm's canal.

RESULTS

Total, 40 eyes of 20 subjects who underwent μLOT-phaco and iStent-phaco and achieved a minimum of 12mo of follow-up were comprised in the present analysis. Demographic and preoperative parameters are shown in Table 1.

The parameters acquired from the subjects comprised patients' age, sex, eye, preoperative BCVA, MD according to the Humphrey field analyzer, IOP, number of ophthalmic antiglaucoma agents used, ACF, ECD, and glaucoma type. There were no significant differences between the two groups regarding preoperative BCVA, preoperative IOP, number of ophthalmic antiglaucoma agents used, ACF, or ECD. There were more left eyes and men in the μLOT-phaco group than in the iStent-phaco group. The preoperative MD was worse in the μLOT-phaco group (-8.1±3.9) than in the iStent-phaco group (-3.9±2.4; *P*<0.01, 2-tailed Student's *t*-tests). Figure 3 shows the change in the mean IOP in both groups, from preoperatively to 12mo postoperatively. The mean IOP in both groups decreased significantly from 16.7±2.7 to 13.6±3.0 mm Hg (μLOT-phaco group), and from 16.2±2.2 to 13.6±2.3 mm Hg (iStent-phaco group) by 1mo postoperatively. The IOP reduction was maintained in both groups at 12mo. The mean percentage IOP reduction was not significantly different between the μLOT-phaco group (17.8%±14.7%) and the iStent-phaco group (17.2%±11.3%). The success rate of IOP reduction according to the criteria defined in the study design at 12mo were 80.0% in the μLOT-phaco group and 80.0% in the iStent-phaco group, respectively.

Figure 4 shows the alteration in the mean number of ophthalmic antiglaucoma agents used in both groups from preoperatively to 12mo after operation. The mean number of ophthalmic antiglaucoma agents used in both groups was significantly decreased from 3.1 ± 0.9 to 0.4 ± 0.5 (μ LOT-phaco group), and from 2.8 ± 0.8 to 0.6 ± 0.8 (iStent-phaco group) by 12mo after operation. The decrement in the mean number of ophthalmic antiglaucoma agents in both groups was maintained at 12mo.

Figure 5 shows the change in the ACF in both groups from preoperatively to 1mo postoperatively. The preoperative ACF value in the μ LOT-phaco group was 9.5 ± 3.0 pc/ms and returned to normal by 30d postoperative, with a value of 11.4 ± 3.9 pc/ms. In the iStent-phaco group, the ACF value was 9.6 ± 2.2 pc/ms preoperatively, and it returned to normal by 7d postoperatively (11.2 ± 3.7 pc/ms), and by day 30 it was 9.8 ± 3.5 pc/ms.

Corneal ECD was not significantly different before and after operation in both groups (μ LOT-phaco group: 2751.5 ± 159 to 2579.5 ± 419.6 , $P=0.06$, paired t -test, iStent-phaco group: 2773.1 ± 225.6 to 2625.5 ± 226.3 , $P=0.07$, paired t -test). Consistent with cataract surgery, the BCVA had improved in both groups, as compared to baseline by 12mo postoperatively. Table 2 lists the surgery-related complications in the two groups. In the μ LOT-phaco group, hyphema with niveau occurred in two patients (10.0%) and resolved within 1wk. A transient increase in IOP (defined as $IOP > 50\%$ above baseline^[14]) was seen in three patients (15.0%) in the iStent-phaco group and in two patients (10.0%) in the μ LOT-phaco group. Floaters were noted in 15.0% of the iStent-phaco group and in 10.0% of the μ LOT-phaco group. In the iStent-phaco group, one patient had focal peripheral anterior synechiae occlusion of the iStent due to the iris of the iStent, and transient increase in IOP (32 mm Hg) at 1mo postoperatively. In this case, the iStent was found to be tilted toward the iris when observed with a gonioscope after surgery. In addition, three other patients had iStent occlusion, but none of them had increased IOP.

DISCUSSION

In this study, we performed μ LOT or iStent implantation procedures in alternate eyes of the same patient, to evaluate the effectuality and safety of these two MIGS, as this intra-patient comparison may reduce the bias caused by individual differences. We found that the iStent and μ LOT were both effective through 12mo of follow-up, but the iStent showed to be safer, based on early anterior chamber inflammation.

The Japanese Guidelines for Use of iStent Trabecular Micro Bypass in Combination with Cataract Surgery^[15] clearly states that the indication of the iStent treatment is: “adult patients with mild to moderate open angle glaucoma (POAG, PEX)

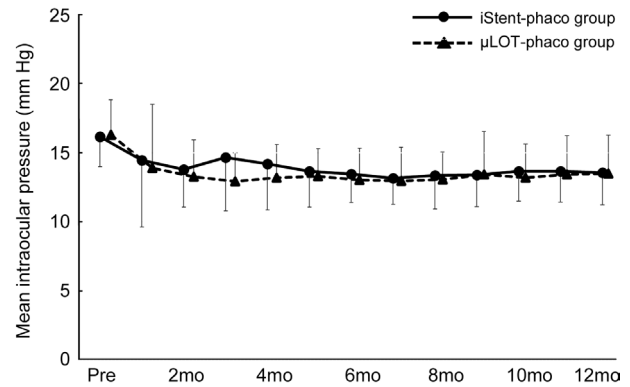


Figure 3 The change in the mean IOP in both groups through 12mo Significant IOP reduction was obtained at 12mo after surgery in both groups.

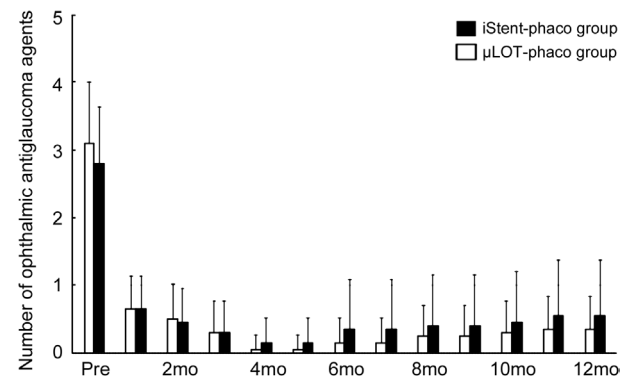


Figure 4 The change in the mean number of ophthalmic anti glaucoma agents through 12mo The number of ophthalmic antiglaucoma agents had been reduced to one or less at 12mo after surgery.

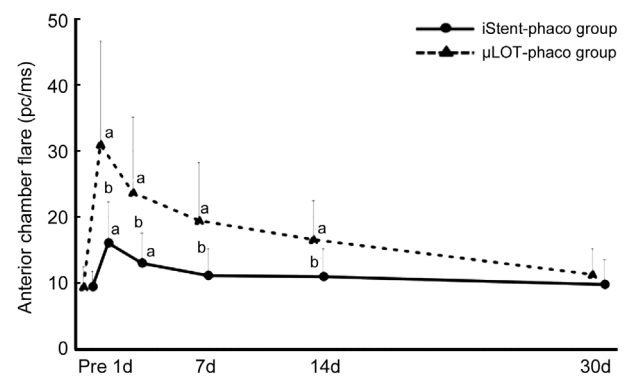


Figure 5 The change in the anterior chamber flare in both groups through 1mo iStent group, there was no inflammation in the anterior chamber 7d after surgery. ^a $P < 0.01$ Student’s t -test; preoperation vs postoperation; ^b $P < 0.01$ Student’s t -test; iStent-phaco group vs μ LOT-phaco group.

with cataracts being treated with antiglaucoma agents”. When surgical procedures were considered based on these guidelines, we decided to perform μ LOT-phaco on the eye with the lower MD and iStent-phaco on the contralateral eye. Therefore, preoperative MD was significantly lower in the μ LOT-phaco group than in the iStent-phaco group; this may have affected our postoperative results, as discussed below.

Table 2 The surgery-related complications of the two groups

Parameters	iStent-phaco (n=20)	μLOT-phaco (n=20)	n (%)
Hyphema with niveau	0	2 (10.0)	0.15
Transient increase in IOP	3 (15.0)	2 (10.0)	0.63
Floaters	3 (15.0)	2 (10.0)	0.63
Peripheral anterior synechiae	1 (5.0)	0	1
Occlusion of the iStent due to the iris	4 (20.0)	-	-
Fibrin membrane	0	1 (5.0)	0.31

^aChi-squared test.

IOP and drug scores were significantly lower postoperatively than preoperatively, for both surgical procedures, indicating the effectiveness of both surgical procedures for open angle glaucoma. Tanito *et al*^[7] reported that a pre-surgery IOP of 25.9±14.3 mm Hg decreased significantly to 14.5±2.9 mm Hg 6mo after the procedure in 17 eyes of 24 patients who underwent μLOT. Although, the preoperative IOP was higher than that in our study, there was a good reduction in IOP^[7]. In this report, the patients remained to use their preoperative antiglaucoma agents postoperatively. Mori *et al*^[11] reported that a preoperative IOP of 28.4±7.8 mm Hg decreased to 17.8±6.3 mm Hg after μLOT, and the number of antiglaucoma drugs also fell from 3.1±1.6 to 1.5±2.3 after the procedure. Based on our results and these reports, μLOT-phaco may be indicated for patients with high preoperative IOP. As these previous reports^[7,11] also included μLOT surgery as a single procedure, we consider that μLOT alone can reduce IOP. In our study, there were no patients in the μLOT-phaco group who developed postoperative peripheral anterior synechiae and performing simultaneous cataract surgery with μLOT opened the gonio angle, which may have reduced the likelihood of postoperative peripheral anterior synechiae.

With iStent-phaco, we achieved good reduction in IOP and it was possible to reduce the number of antiglaucoma agents postoperatively, as seen in previous reports^[9-10]. In this study, iStent implantation and cataract surgery were performed simultaneously for all subjects. Therefore, it is necessary to consider that the IOP-reducing effect of the iStent-phaco also includes the IOP-reducing effect of cataract surgery^[16]. In terms of the IOP-lowering effect of iStent implantation alone, Huang *et al*^[17] found that the flow of aqueous humor improved after iStent insertion using an enucleated human eye. Shiba *et al*^[18] reported that a preoperative IOP of 22.0±3.0 mm Hg decreased significantly to 16.9±3.6 mm Hg by 6mo after surgery in 10 patients who each had two iStents inserted. In terms of the number of iStent insertions, Katz *et al*^[19] reported that the rate of control of IOP≤15 mm Hg by 12mo after iStent implantation was 64.9% with only one iStent inserted, 85.4% with two iStents inserted, and 92.1% with three iStents inserted. This finding suggests that the IOP-reducing effect of

iStent insertion may depend on the number of iStents inserted into the eye. The present study achieved a significant decline in IOP, as compared to before operation, with only lens extraction and implant of a single iStent. Therefore, this surgery may be a useful option for patients with early or middle stage glaucoma with cataracts. Adverse effects of antiglaucoma eye drops on the ocular surface have also been reported^[20-21]; hence, reducing the number of antiglaucoma agents used after iStent-phaco or μLOT-phaco surgery may lead to improved patient adherence^[22]. In terms of the rate of reduction in IOP, μLOT has an extensive effect on the trabecular meshwork and Schlemm’s canal; it was therefore expected to accomplish a better reduction in IOP than iStent implantation. However, there was no significant difference between the two procedures. The reason for this may be that the iStent-phaco group had less advanced glaucoma than the μLOT-phaco group, so that there was less obstruction of the trabecular meshwork and passage after Schlemm’s canal, thereby allowing a greater IOP-lowering effect. However, this would need to be proved by investigating both procedures in cases with matched stages of progression.

The most remarkable finding in this study was the rapid recovery of the ACF value after iStent-phaco surgery. It took ≥14d for the difference with the preoperative value to disappear in the μLOT-phaco group. In contrast, by day 3 after surgery, there was no significant difference from the preoperative value in the iStent-phaco group. This may be related to the minimal surgical invasiveness of iStent-phaco. Tanito *et al*^[23] reported that μLOT improves ACF earlier than the EX-PRESS Shunt and trabeculectomy. This result suggests that MIGS causes less inflammation in the anterior chamber than filtration surgery. In the present study, the ACF improved earlier in the iStent-phaco group than in the μLOT-phaco group, implying that iStent-phaco is a MIGS that is less likely to result in postoperative inflammation. iStent-phaco may be a particularly helpful option for patients with open angle glaucoma who also have cataracts and want to return to society early after surgery.

Although, the corneal ECD decreased postoperatively in both groups, as compared with the preoperative level, there was a similar degree of reduction to that seen in the divide and

conquer technique^[24], a generally implemented cataract surgery method; therefore, it is unlikely that the μ LOT and iStent implantation procedures affected the decrease in corneal ECD. BCVA was significantly improved at the final examination in both groups, and the only influence of μ LOT and iStent implantation surgery on postoperative visual acuity loss was due to anterior chamber hemorrhage.

Regarding postoperative complications, hyphema with niveau occurred in 2 patients (10.0%) in the μ LOT-phaco group, but no patients developed this condition in the iStent-phaco group. Anterior chamber hemorrhage occurs with μ LOT due to the incision made in the trabecular meshwork and Schlemm's canal. Therefore, hyphema forming niveau in the μ LOT-phaco group was not considered an adverse event. The hyphema forming niveau was assumed to have resulted in the transient increase in IOP in one patient, but this resolved within 1wk. On the other hand, three patients in the iStent-phaco group developed transient elevation of IOP (15.0%). Iwasaki *et al*^[25] compared the results of a group using Kahook Dual Blade excisional goniotomy and cataract surgery with those of an iStent-phaco group and reported that a transient increase in IOP occurred in 6.8% of the iStent-phaco group. In the present report, there was one case of transient increase in IOP because of incarcerated iris in the iStent-phaco group, and the IOP was reduced by releasing the incarceration with YAG laser irradiation. Shiba *et al*^[18] also described transient increase of IOP due to iris incarceration after iStent implantation. Postoperative follow-up and management are important, even with MIGS, where postoperative management is generally easier than with filtration surgery. Salimi *et al*^[14] reported the effect of steroid eye drops on the increase of IOP in the early postoperative period after iStent-phaco. We also used dexamethasone instillation for 1mo after all surgeries. There may be a causal relationship between the transient elevation of IOP and the instillation of steroids in the two cases with transient elevation of IOP after iStent-phaco, because the IOP decreased rapidly once dexamethasone was discontinued. The number of floaters was found to be similar in both groups, and this is assumed to be due to inflammatory cells or hemorrhage in the anterior chamber after surgery. Given that all patients underwent lens reconstruction in this study, it is possible that subjective symptoms occurred.

There were some biases in this study, including differences in disease stages between the eyes treated with the two surgical procedures. Additionally, performing cataract surgery concurrently with both surgical procedures meant that the effect of μ LOT alone and iStent implantation alone is unknown. It will be necessary to examine disease stages in future studies.

This study compared the early postoperative results of iStent-phaco and μ LOT-phaco in the same patient. Both methods are considered effective and safe for open angle glaucoma with early to mid-stage concomitant with cataracts. iStent-phaco causes little postoperative inflammation, and is therefore, considered a good option for patients aiming for an early return to work.

ACKNOWLEDGEMENTS

Authors' contributions: Study concept and design: Tokuda N, Tsukamoto A, Toyoda Y, Yamada Y; Acquisition of data: All authors; Analysis and interpretation of data: All authors; Drafting of the manuscript: Tokuda N, Kitaoka Y; Critical revision of the manuscript for important intellectual content: All authors.

Conflicts of Interest: Tokuda N, None; Kitaoka Y, None; Tsukamoto A, None; Toyoda Y, None; Yamada Y, None; Sase K, None; Takagi H, None.

REFERENCES

- 1 Saheb H, Ahmed II. Micro-invasive glaucoma surgery: current perspectives and future directions. *Curr Opin Ophthalmol* 2012;23(2): 96-104.
- 2 Sagara H, Yamamoto T, Imaizumi K, Sekiryu T. Impact of topically administered steroids, antibiotics, and sodium hyaluronate on bleb-related infection onset: the Japan glaucoma society survey of bleb-related infection report 4. *J Ophthalmol* 2017;2017:7062565.
- 3 Azuma K, Saito H, Takao M, Araie M. Frequency of hypotonic maculopathy observed by spectral domain optical coherence tomography in post glaucoma filtration surgery eyes. *Am J Ophthalmol Case Rep* 2020;19:100786.
- 4 Francis BA, See RF, Rao NA, Minckler DS, Baerveldt G. *Ab interno* trabeculectomy: development of a novel device (Trabectome) and surgery for open-angle glaucoma. *J Glaucoma* 2006;15(1):68-73.
- 5 Chin S, Nitta T, Shinmei Y, Aoyagi M, Nitta A, Ohno S, Ishida S, Yoshida K. Reduction of intraocular pressure using a modified 360-degree suture trabeculectomy technique in primary and secondary open-angle glaucoma. *J Glaucoma* 2012;21(6):401-407.
- 6 Seibold LK, Soohoo JR, Ammar DA, Kahook MY. Preclinical investigation of *ab interno* trabeculectomy using a novel dual-blade device. *Am J Ophthalmol* 2013;155(3):524-529.e2.
- 7 Tanito M, Sano I, Ikeda Y, Fujihara E. Short-term results of microhook *ab interno* trabeculectomy, a novel minimally invasive glaucoma surgery in Japanese eyes: initial case series. *Acta Ophthalmol* 2017;95(5):e354-e360.
- 8 Bahler CK, Smedley GT, Zhou JB, Johnson DH. Trabecular bypass stents decrease intraocular pressure in cultured human anterior segments. *Am J Ophthalmol* 2004;138(6):988-994.
- 9 Spiegel D, García-Feijó J, García-Sánchez J, Lamielle H. Coexistent primary open-angle glaucoma and cataract: preliminary analysis of treatment by cataract surgery and the iStent trabecular micro-bypass stent. *Adv Ther* 2008;25(5):453-464.

- 10 Samuelson TW, Katz LJ, Wells JM, Duh YJ, Giamporcaro JE, Group USIS. Randomized evaluation of the trabecular micro-bypass stent with phacoemulsification in patients with glaucoma and cataract. *Ophthalmology* 2011;118(3):459-467.
- 11 Mori S, Murai Y, Ueda K, Sakamoto M, Kurimoto T, Yamada-Nakanishi Y, Nakamura M. A comparison of the 1-year surgical outcomes of *ab externo* trabeculotomy and microhook *ab interno* trabeculotomy using propensity score analysis. *BMJ Open Ophthalmol* 2020;5(1):e000446.
- 12 Hodapp E, Parrish R, Anderson DR. Clinical decisions in glaucoma. 1993 https://www.researchgate.net/figure/Hoddap-Parrish-Anderson-criteria_fig1_38015805.
- 13 The Japan Glaucoma Society Guidelines for Glaucoma (4th Edition). *J Jpn Ophthalmol Soc* 2018;122(1):5-53.
- 14 Salimi A, Winter A, Li C, Harasymowycz P, Saheb H. Effect of topical corticosteroids on early postoperative intraocular pressure following combined cataract and trabecular microbypass surgery. *J Ocul Pharmacol Ther* 2019;35(7):413-420.
- 15 iStent Trabecular Micro Bypass in Combination with Cataract Surgery congress. "Japanese Guidelines for Use of iStent Trabecular Micro Bypass in Combination with Cataract Surgery". *J Jpn Ophthalmol Soc* 2016;120:494-497.
- 16 Jahn CE. Reduced intraocular pressure after phacoemulsification and posterior chamber intraocular lens implantation. *J Cataract Refract Surg* 1997;23(8):1260-1264.
- 17 Huang AS, Saraswathy S, Dastiridou A, Begian A, Mohindroo C, Tan JC, Francis BA, Hinton DR, Weinreb RN. Aqueous angiography-mediated guidance of trabecular bypass improves angiographic outflow in human enucleated eyes. *Invest Ophthalmol Vis Sci* 2016;57(11):4558-4565.
- 18 Shiba D, Hosoda S, Yaguchi S, Ozeki N, Yuki K, Tsubota K. Safety and efficacy of two trabecular micro-bypass stents as the sole procedure in Japanese patients with medically uncontrolled primary open-angle glaucoma: a pilot case series. *J Ophthalmol* 2017;2017:9605461.
- 19 Katz LJ, Erb C, Carceller GA, Fea AM, Voskanyan L, Wells JM, Giamporcaro JE. Prospective, randomized study of one, two, or three trabecular bypass stents in open-angle glaucoma subjects on topical hypotensive medication. *Clin Ophthalmol* 2015;9:2313-2320.
- 20 Leung EW, Medeiros FA, Weinreb RN. Prevalence of ocular surface disease in glaucoma patients. *J Glaucoma* 2008;17(5):350-355.
- 21 Tokuda N, Inoue J, Yamazaki I, Ueno S, Fujisawa S. Effects of a long-acting ophthalmic formulation of carteolol containing alginate on the corneal epithelial barrier function and water retentive effect. *J Ocul Pharmacol Ther* 2012;28(2):123-128.
- 22 Nordstrom BL, Friedman DS, Mozaffari E, Quigley HA, Walker AM. Persistence and adherence with topical glaucoma therapy. *Am J Ophthalmol* 2005;140(4):598-606.
- 23 Tanito M, Manabe K, Mochiji M, Takai Y, Matsuoka Y. Comparison of anterior chamber flare among different glaucoma surgeries. *Clin Ophthalmol* 2019;13:1609-1612.
- 24 Storr-Paulsen A, Norregaard JC, Ahmed S, Storr-Paulsen T, Pedersen TH. Endothelial cell damage after cataract surgery: divide-and-conquer versus phaco-chop technique. *J Cataract Refract Surg* 2008;34(6):996-1000.
- 25 Iwasaki K, Takamura Y, Orii Y, Arimura S, Inatani M. Performances of glaucoma operations with Kahook Dual Blade or iStent combined with phacoemulsification in Japanese open angle glaucoma patients. *Int J Ophthalmol* 2020;13(6):941-945.