

# Severe unilateral congenital ptosis with poor levator function: tarsoconjunctival mullerectomy plus levator resection vs frontalis sling procedure

Abolfazl Kasae<sup>1</sup>, Mostafa Aliabadi<sup>1</sup>, Laily Najafi<sup>2</sup>, Mansooreh Jamshidian–Tehrani<sup>3</sup>

<sup>1</sup>Farabi Eye Hospital, Tehran University of Medical Sciences (TUMS), Tehran 1336616351, Iran

<sup>2</sup>Endocrine Research Center, Institute of Endocrinology and Metabolism, Iran University of Medical Sciences (IUMS), Tehran 1593716615, Iran

<sup>3</sup>Ophthalmic Plastic Surgery, Farabi Eye Hospital, Tehran University of Medical Sciences (TUMS), Tehran 1336616351, Iran

**Co-first authors:** Abolfazl Kasae and Mostafa Aliabadi

**Correspondence to:** Mansooreh Jamshidian-Tehrani. Farabi Eye Hospital, Kargar Street, Ghazvin Square, Tehran 1336616351, Iran. mansooreh\_2468@yahoo.com

Received: 2021-11-03 Accepted: 2022-04-13

## Abstract

• **AIM:** To compare frontalis sling and tarsoconjunctival mullerectomy plus levator resection (TCMLR) in subjects with severe unilateral congenital ptosis with poor levator function (LF).

• **METHODS:** A prospective non-randomized non-blinded single center clinical trial. Fifty patients with severe unilateral congenital ptosis with poor LF were recruited. The frontalis sling and TCMLR were performed and the functional, cosmetic outcomes, complications, and success rate were evaluated at 1, 3, and 6mo postoperatively. The t-test, Chi-square, Fishers exact, and nonparametric Mann-Whitney tests were used by SPSS software.

• **RESULTS:** Frontalis sling and TCMLR procedures were performed on 26 and 24 patients respectively. The mean age was 10.97±10.67y. LF was significantly better in the TCMLR group at months 1, 3, and 6 ( $P=0.002$ ). Lagophthalmos was more common in the TCMLR group (no significant difference). At month 3, mild punctate epithelial erosions were observed more in the frontalis sling group ( $P=0.002$ ). Significant complete success rate of 1<sup>st</sup> and 6<sup>th</sup> month for the frontalis sling vs TCMLR groups were 50% vs 20.8% ( $P=0.02$ ), and 38.4% vs 50% ( $P=0.03$ ) respectively.

• **CONCLUSION:** Complete success rate of TCMLR is higher in long-term follow-up in contrast with the frontalis

sling in the short-term. Transient complications are more detected in mid-term follow-ups in both groups.

• **KEYWORDS:** tarsoconjunctival mullerectomy; levator resection; frontalis sling; congenital ptosis

**DOI:10.18240/ijo.2022.08.05**

**Citation:** Kasae A, Aliabadi M, Najafi L, Jamshidian-Tehrani M. Severe unilateral congenital ptosis with poor levator function: tarsoconjunctival mullerectomy plus levator resection vs frontalis sling procedure. *Int J Ophthalmol* 2022;15(8):1254-1260

## INTRODUCTION

Severe unilateral congenital ptosis with poor levator function (LF) is the most challenging category of congenital ptosis varieties<sup>[1-2]</sup>.

Frontalis sling is the choice procedure for congenital ptosis with poor LF, which could be performed by different materials such as silicone rod, sutures, frontalis muscle flap, temporalis fascia, fascia lata and *etc*<sup>[1,3-15]</sup>. Although unilateral ptosis frontalis sling surgery does not achieve perfect eyelid function and cosmetic appearance as well as bilateral ones<sup>[3]</sup>. Furthermore, frontalis suspension surgery has serious and common problems such as surgical failure, eyelid and brow asymmetry and lagophthalmos much more in unilateral cases<sup>[16-18]</sup>.

Tarsoconjunctival mullerectomy plus levator resection (TCMLR) is considered as an alternative method to frontalis sling surgery, which is not discussed in the literature, attentionally its success rate, complications and comparison to frontalis sling procedure in the aforementioned ptosis category<sup>[19]</sup>.

Modified maximal levator palpebrae superioris shortening was another effective and endurable route of treatment for sever congenital ptosis with poor LF especially in patients whose LF was less than 2 mm<sup>[20]</sup>.

The aim of the present study is to compare the functional and cosmetic outcomes, complications, and success rate of frontalis sling and TCMLR in subjects with severe unilateral congenital ptosis with poor LF.

## SUBJECTS AND METHODS

**Ethical Approval** The Ethics Committee of Tehran University of medical sciences approved the study protocol (IR.TUM.FARABIH.REC.1397.044). All procedures performed in studies involving human participants were in accordance with the ethical standards of the Institutional and/or National Research Committee and with the 1964 Helsinki Declaration and its later amendments or comparable ethical standards. All eligible subjects' or their parents agreed and signed the written informed consent after full explanation of the purpose and nature of all procedures used. The consent is obtained to publish identifiable photographs and is archived with the authors, although the authors cropped the clinical photographs that identifications is not possible. The RCT code of this study is IRCT20200613047753N1.

The study was performed at Ophthalmic Plastic Unit, Farabi Eye Hospital, Tehran University of Medical Sciences (TUMS), Tehran, Iran. In this prospective non-randomized non-blinded clinical trial study, fifty patients (50 eyelids) with severe unilateral congenital ptosis with poor LF were enrolled, during 2018-2020.

The sample size was calculated by G power software (version 3.1), power=80%,  $\alpha=5\%$ . Totally, 50 participants with complete and full record of demographic, surgical, and post-operative parameters were recruited and comprised of two groups; the frontalis sling and TCMLR procedures (26 vs 24 participants respectively).

All frontalis sling procedures were performed by single plastic surgeon (Jamshidian-Tehrani M) and all TCMLR procedures were accomplished by one another plastic surgeon (Kasaei A), each group was assigned according to the patient's age, in which TCMLR was done for age range of 2-42y, and the frontalis sling procedure was performed for the age range 1-17y, and the criteria for selection of each group was the surgeon's expertise, preference and his/her trends.

According to ethical considerations, the TCMLR procedure should be done in elderly participants because of tarsal growth in younger age and chance of cicatricial entropion in excessive removal of tarsus.

The inclusion criterion included patients with poor LF (4 mm and less) and severe unilateral congenital myogenic ptosis. Subjects who had poor bell's phenomenon, cerebral palsy, previous surgical history and other causes of ptosis (blepharophimosis, Marcus Gunn Jaw Winking reflex, etc.) were excluded.

A single trained ophthalmologist (Aliabadi M) performed detailed history and physical examination, and extracted clinical parameters and anthropometric variables, through hospital charts and face-to-face interviews in the first and the following preoperative and postoperative visits.

A complete eye examination was performed with special

attention given to the history, a detailed slit lamp examination, ocular surface test, fundus examination, detailed ptosis analysis (amount, type, severity), LF, bell's phenomenon, visual acuity and refractive error assessment, extraocular movements, pupillary light reflex, marginal reflex distance1 (MRD1), MRD2, absence or presence of lid crease, palpebral fissure (PF) heights, eyelid excursion, and the head position (the variables in children younger than 5 years old, were approximately measured according to lack of cooperation).

**Variables & Complications** The aforementioned variables LF, cosmetic outcomes (MRD1, MRD2, PF height) were evaluated preoperatively. The variables such as LF, cosmetic outcomes (MRD1, MRD2, PF height), complications [lagophthalmos, ocular surface changes (tear film profile), exposure keratopathy, punctate epithelial erosions (PEE), allergic reactions, overcorrection and under correction] and success rate were fully evaluated for these participants at 1, 3, and 6mo postoperatively by Aliabadi M and was double-checked by the assigned surgeon.

### Surgical Techniques Description

#### Tarsoconjunctival mullerectomy plus levator resection

First by anterior approach, the levator muscle was resected according to MRD1 and LF, afterward; the tarsus, conjunctiva and muller muscle were resected according to correction requirements of each patient adaptively (no Putterman clamp usage), adjustment suture of levator to the tarsus was performed with Vicryl 6-0, and then repair of tarsus to the conjunctiva was done with Vicryl 7-0.

**Frontalis sling procedure** Suspension of frontalis muscle was performed with the pentagon technique<sup>[21]</sup> (5 incision, 2 incision on eyelid crease<sup>[22]</sup> and 3 incision above the eyebrows)<sup>[15,23]</sup> by Crawford silicon rods (ECI, Louis Armand Co., Paris) and securing the knot with Vicryl 5-0<sup>[1,9,24-25]</sup>.

### Definition of Terms

**Ptosis** Graded as mild ( $\leq 2$  mm), moderate (3 mm), or severe ( $\geq 4$  mm) from the normal position of rest in primary gaze<sup>[4]</sup>.

**Success rate** MRD1 $\geq 3$  mm, bilateral asymmetry  $< 1$  mm is defined as complete success rate,  $2 \leq$ MRD1 $< 3$ ,  $1 <$  bilateral asymmetry  $< 2$  is defined as incomplete success rate and MRD1 $< 2$  mm, bilateral asymmetry  $> 2$  mm is defined as failure rate. Total success rate is summation of complete and incomplete success rate.

**Overcorrection** Overcorrection is defined as MRD1 $\geq 3$  mm and bilateral asymmetry  $\geq 2$  mm.

**Lid lag** PF width measurement in downgaze.

**Lagophthalmos** PF width measurement in closed eye.

**Punctate Epithelial Erosion** Mild $\leq 1/3$  of corneal surface involvement,  $1/3 <$  moderate $\leq 2/3$  of corneal involvement, severe $> 2/3$  of corneal surface involvement.

Ptosis, success rate, overcorrection, lid lag, lagophthalmos

were measured and graded by measurement ruler, and PEE was evaluated by slit lamp examination and fluorescein staining.

**Statistical Analysis** To compare continuous variables between two groups of different surgical procedures, *t*-test was utilized, and for comparing discrete variables between two groups, Chi-squared and Fishers' exact tests were the tools. Moreover, the nonparametric Mann-Whitney test was used to compare the distribution of non-normal variables, between two groups. The Kolmogorov-Smirnov Calculator (test of normality) was used to evaluate the distribution of data. The SPSS software (ver. 25) was used to analyze the data. The significance level was chosen to be 0.05.

## RESULTS

Fifty patients with severe unilateral congenital ptosis with poor LF were enrolled in frontalis sling and TCMLR operations (26 and 24 patients respectively). The mean (SD) age was 10.97±10.67y (male/female ratio=35:15). The baseline characteristics and outcomes compared between frontalis sling and TCMLR groups in Table 1.

LF, PF, MRD1, and MRD2 were measured at months 1, 3, and 6 for both procedures and described in Table 2. The LF was significantly more in the TCMLR group at months 1, 3, and 6, but no significant difference was observed for the other aforementioned outcomes.

The postoperative surgical complications such as ocular surface condition (tear film profile) and PEEs were measured between frontalis sling and TCMLR procedures at months 1, 3, and 6. Mild PEE was more observed in the 3<sup>rd</sup> month evaluation on the frontalis sling group (16 frontalis sling vs 4 TCMLR; *P*-values of month 1, 3 and 6 were as follows: 0.56, 0.002, 0.05). Severe and moderate PEEs were not found in any patient.

Lagophthalmos ≥ 1 mm was more common in the TCMLR group in all three follow-ups, but the difference was not statistically significant [12, 12, 13 cases in TCMLR group and 11, 12, 11 cases in frontalis sling group in 1, 3, 6mo follow-ups respectively (*P*=1)]. Furthermore, the lid lag > 3 mm was statistically similar in both groups [19, 19, 19 cases in TCMLR group and 21, 22, 22 cases in frontalis sling group in 1, 3, 6mo follow-ups respectively (*P*=1)].

The success rate of two surgical procedures was compared at 1, 3, and 6mo (Table 3). Statistically significant difference of complete success rate was detected for the 1<sup>st</sup> and 6<sup>th</sup> month evaluation between two groups, indicating that the success rate of frontalis sling was higher in the 1<sup>st</sup> month, and vice versa at the last follow-up.

Total success rate of frontalis sling and TCMLR procedures were 65.3% and 79.1% respectively which is not statistically different (*P*=0.27). The success rates related were demonstrated in Figures 1-3. Incomplete success, failure

rate and overcorrection were more detected in frontalis sling method without statistically significant difference. Asymmetric crease was observed in 15.5% of the frontalis sling and 12.5% of the TCMLR procedures (*P*=0.76). Allergic reaction and signs of extrusion were not happened in any patients of both groups.

In the Figures 2 and 3, the preoperative photographs of two unilateral congenital ptosis cases were presented, and the postoperative six months follow-up of two procedures (frontalis sling and TCMLR) were mentioned. In the section, the six months postoperative, lagophthalmos of two procedures were presented.

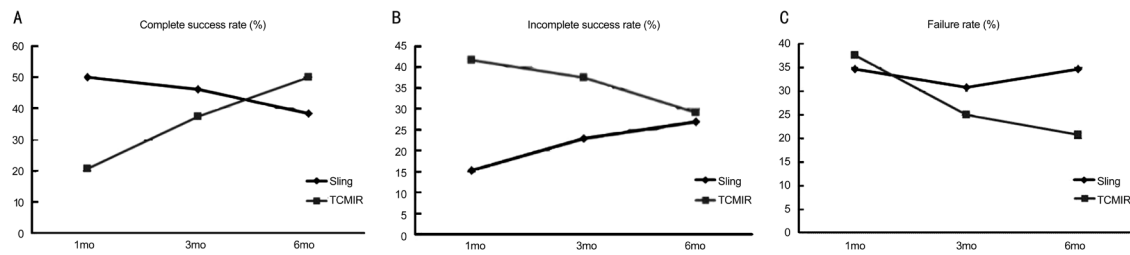
## DISCUSSION

The aim of the present study is to compare the functional and cosmetic outcomes, complications, and success rate of frontalis sling and TCMLR in subjects with severe unilateral congenital ptosis with poor LF.

Preoperatively there was no significant difference in eyelid indicators such as LF, PF, MRD1, and MRD2. The mean age was lower in the frontalis sling group than in the TCMLR similar to Whitehouse *et al*<sup>[26]</sup> mean age. The mean age of Kabra and Khatri's study<sup>[27]</sup> was 15.85y. The etiology of late age diagnosis in the present study and the other studies is the lack of awareness about the possible visual and fascial cosmetic abnormalities associated with ptosis and the disability to describe the complications in children and incomplete growth of the tarsus make the surgeons to prefer frontalis sling instead of TCMLR in children group. Subsequently, the assigned surgeons elected to have TCMLR in older children to find more defined eyelid structures.

The results show that TCMLR, in terms of eyelid position indicators and postoperative complications, is well comparable to the standard frontalis sling method.

Prior to the operation, neither group had lagophthalmos, but in all three follow-ups, more patients of the TCMLR group had lagophthalmos, although the difference between two groups was not statistically significant, it might be according to tarsal plate shortening in the TCMLR procedure. A significant point of the present study was the increment of levator muscle function in all three follow-ups of TCMLR. This finding can be justified by the association of levator resection or its strengthening in this group. None of the three variables (MRD1, MRD2, and PF) were significantly different in three follow-ups between two studied groups. As a result, the appearance of the eyelids is comparable to any of the frontalis sling and TCMLR. Nearly 80% of both groups had lid lag during the study, there was no significant difference between two groups regarding lid lag. It is important that the lack of difference in the above parameters does not necessarily mean that there is no difference in appearance and cosmetic results. The frontalis



**Figure 1** The comparison of complete success rate (A), incomplete success rate (B), failure rate (C) between frontalis sling and TCMLR procedures during 1-, 3-, and 6-month follow-up TCMLR: Tarsconjunctival mullerectomy plus levator resection.

**Table 1** Comparison of baseline characteristics and outcomes between frontalis sling and TCMLR groups

Variable	Frontalis sling	TCMLR	Total	P
Age (y)	4.75±4.06	17.71±11.55	10.97±10.67	0.000
Sex (M:F)	19:7	16:8	35:15	0.000
Laterality (OD:OS)	15:11	12:12	27:23	0.79
LF preop. (mm)	1.38±1.09	2.5±1.17	1.92±1.25	0.58
PF preop. (mm)	4.69±2.52	4.75±2.3	4.72±2.42	0.93
MRD1 preop. (mm)	-0.57±1.62	-0.87±1.43	-0.72±1.52	0.39
MRD2 preop. (mm)	5.26±0.90	5.62±0.87	5.44±0.90	0.11

Data are analyzed by independent *t*-test and Mann-Whitney *U* test. TCMLR: Tarsconjunctival mullerectomy plus levator resection; LF: Levator function; PF: Palpebral fissure; MRD: Marginal reflex distance; OD: Oculus dexter; OS: Oculus sinister.

**Table 2** Comparison of LF, PF, MRD1, and MRD2 between frontalis sling and TCMLR groups at 1, 3, and 6mo

Outcomes	Frontalis sling	TCMLR	P
<b>LF</b>			
Month 1	1.42±1.10	2.58±1.34	0.002
Month 3	1.42±1.10	2.58±1.34	0.002
Month 6	1.42±1.10	2.58±1.34	0.002
<b>PF</b>			
Month 1	7.74±2.31	7.61±2.20	0.83
Month 3	7.74±2.05	7.86±2.23	0.84
Month 6	7.63±2.31	8.13±2.28	0.44
<b>MRD1</b>			
Month 1	2.32±1.56	1.97±1.31	0.32
Month 3	2.28±1.58	2.22±1.34	0.70
Month 6	2.13±1.55	2.41±1.41	0.52
<b>MRD2</b>			
Month 1	5.42±0.75	5.64±0.89	0.23
Month 3	5.46±0.47	5.64±0.89	0.41
Month 6	5.50±0.76	5.72±0.87	0.28

Data are analyzed by Mann-Whitney *U* test. TCMLR: Tarsconjunctival mullerectomy plus levator resection; LF: Levator function; PF: Palpebral fissure; MRD: Marginal reflex distance.

sling surgery's complications could be mentioned as; skin scars may remain at the incision sites just above the eyebrows or unequal eyebrow elevation, and asymmetric crease. Corneal erosion or dry eye was significantly different in 3mo follow-up between two groups which mentioned by higher

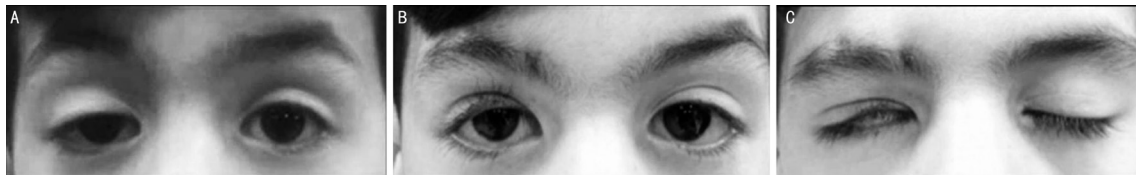rates of corneal erosion in frontalis sling group. No significant differences were detected for the mentioned complications in the first and 6mo follow-up. Our interpretation for the mentioned significant complication in the frontalis sling group at the 3<sup>rd</sup> month could be multifactorial which is dependent to maternal care, drug compliance and surgical technique.

In the first month, the complete success rate of frontalis sling group was significantly higher than the TCMLR group which was inverted in the 6<sup>th</sup> month.

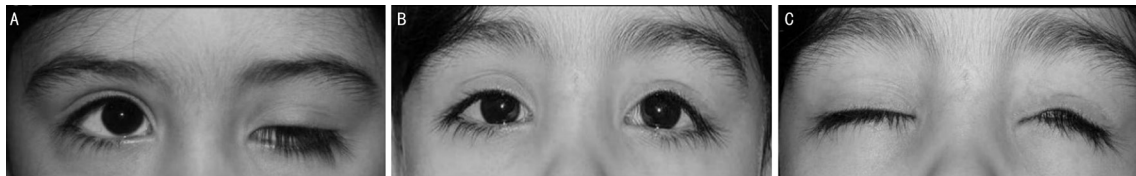Kabra and Khatri's<sup>[27]</sup> reported the results of various surgeries on 52 eyelids with congenital ptosis with a follow-up period of 1, 3, and 6mo. They performed TCMLR for the patients with good LF and mild ptosis and considered frontalis sling surgery for the patients with weak LF and severe ptosis. At the end of study, no significant difference was reported between two surgeries in terms of cosmetic and functional outcomes, although complications were greater in the frontalis sling group. Good LF selection for TCMLR procedure in Kabra and Khatri's<sup>[27]</sup> study may explain the difference with the present study.

In the present study, no significant visual complications were observed in any of the studied groups.

Whitehouse *et al*'<sup>[26]</sup> demonstrated retrospectively 80 eyelids with unilateral and bilateral congenital ptosis that underwent levator resection and frontalis sling surgery with fascia lata; 21% and 4% of them required second and third surgery, respectively. They concluded that in patients with good LF, the levator muscle resection is recommended and in poor LF the frontalis sling is suggested. In comparison with the



**Figure 2 Unilateral congenital ptosis** A: Preop. photograph of the 7 years old boy with congenital ptosis of right eye underwent sling procedure with application of silicon rod; B: Postop. 6mo; C: Postop. 6mo, lagophthalmos.



**Figure 3 Unilateral congenital ptosis** A: Preop. photograph of the 3 years old girl with congenital ptosis of left eye underwent TCMLR procedure; B: Postop. 6mo; C: Postop. 6mo, lagophthalmos. TCMLR: Tarsosconjunctival mullerectomy plus levator resection.

**Table 3 Comparison of success rate between frontalis sling and TCMLR groups at 1, 3, and 6mo**

Success rate (%)	Month 1			Month 3			Month 6		
	Sling <sup>a</sup>	TCMLR	<i>P</i>	Sling <sup>a</sup>	TCMLR	<i>P</i>	Sling <sup>a</sup>	TCMLR	<i>P</i>
Complete success rate	50	20.8	0.02 <sup>a</sup>	46.1	37.5	0.59	38.4	50	0.03 <sup>a</sup>
Incomplete success rate	15.3	41.6	0.02 <sup>a</sup>	23	37.5	0.04 <sup>a</sup>	26.9	29.1	0.51 <sup>a</sup>
Failure rate	34.6	37.5	0.43 <sup>a</sup>	30.7	25	0.66 <sup>a</sup>	34.6	20.8	0.05 <sup>a</sup>

Chi-squared test. <sup>a</sup>Frontalis Sling; TCMLR: Tarsosconjunctival mullerectomy plus levator resection.

present study; we used a distensible material for the sling, and Whitehouse *et al*<sup>[26]</sup> used fascia lata, which is much more restrictive. One of the etiologies for the difference of success rate and complications in various materials of frontalis sling procedure is related to the mentioned etiology<sup>[4-7,9,11,15,23-25]</sup>. However, in the present study, no secondary corrective surgery was required for any of the patients, and we concluded that TCMLR results are similar with frontalis sling in severe unilateral congenital ptosis with poor LF.

Pang *et al*<sup>[28]</sup> retrospectively examined the indications, efficacy, and postoperative complications of Fasanella-Servat surgery to treat mild to moderate ptosis with a variety of underlying causes, in contrast of our prospective study for the severe congenital cases. The best results were achieved in patients with Horner syndrome (100% success) and in patients with previous levator resection (100% success) although the unsatisfactory results were demonstrated in congenital ptosis (76.4%). The lowest success rate of Pang *et al*'s<sup>[28]</sup> study was achieved in congenital ptosis which is comparable with the present study (65.3%), although the population selection (first operation vs re-operation) and the procedures are differed between two studies. Levator muscle was resected in TCMLR method that is less compromised in Fasanella-Servat surgery.

However, in the present study, the surgical results for severe ptosis with poor LF were also desirable and recommended.

Nucci *et al*<sup>[4]</sup> with 5y follow-up after silicone rod frontalis sling

surgery, in 20 children with severe unilateral congenital ptosis with poor LF reported the increment of MRD1 postop., but no change of this indicator in 12mo and 5y follow-up (90% success rate), which is 65.3% in our frontalis sling group with six months follow-up.

The success rate of silicone frontalis sling method in congenital ptosis with poor LF was 90.9% in 6mo follow-up of Tabatabaie *et al*'s<sup>[5]</sup> study, that the differences with the present study was the ptosis severity and population selection.

The results of unilateral frontalis sling surgery were satisfactory in patients with conscious active unilateral brow elevation which is challenging in children<sup>[16]</sup>. These results could be so unsatisfactory according to children's disability to elevate one eyebrow. Furthermore, severe congenital unilateral ptosis subjects with amblyopia usually require conscious effort to activate the frontalis muscle to achieve satisfactory eyelid height, so they are the most challenging cases<sup>[16]</sup>.

Unilateral frontalis sling provides good to excellent functional and cosmetic results in unilateral poor LF ptosis however, their study group was compromised of congenital, posttraumatic and jaw-winking ptosis<sup>[16]</sup>. In comparison with the present study, the merely difference was direct suturing of frontalis sling to the tarsus.

Conclusively, some studies recommended bilateral levator muscle cutting and bilateral frontalis sling procedure for the unilateral congenital ptosis with poor LF<sup>[29-30]</sup>, whereas;

these controversies is not present in bilateral congenital ptosis with poor LF. The positive point of the present study is to recommend another alternate procedure for severe unilateral congenital ptosis with poor LF. So according to ethical considerations, the authors performed TCMLR in elderly group. TCMLR could be suggested as an alternate procedure instead of frontalis sling method to correct severe unilateral congenital ptosis with poor LF. The TCMLR is more aggressive than frontalis sling method, so more edema was detected in short-term follow-up, which was removed in mid-term and improved the success rate in contrast of frontalis sling method. We have a lower upper lid in the earlier postoperative measurements probably due to increased edema in that child case of TCMLR group. Incomplete success and a failure at the beginning of the observations probably can be also explained by the edema. Proper growth of the tarsus had morally limited us to TCMLR surgery at a higher average age because their tarsus had grown enough. TCMLR could be suggested to correct the aforementioned condition in elderly patients while frontalis sling is suggested for the young.

Hence, future studies might compare the aforementioned procedures in children group.

The different results and controversies may accord to different studies that we should determine the population selection, differences of population characteristics, sample sizes, study design, different age ranges, and evaluation period and follow-ups, inclusion/exclusion criteria, different health care strategies, different study protocols and highly selected and methodological shortcomings.

The strengths of the present study were that all measurements were performed in a referral ophthalmologic center. Furthermore, the study design was a prospective non-randomized clinical trial. The limitations of the present study were as follows; low prevalence of severe unilateral congenital ptosis with poor LF, small sample size, short follow-up duration, two surgeons by especial preferences and non-randomization method. Furthermore, due to ethical considerations, the TCMLR procedure should be done in elderly participants because of tarsal growth in younger age and chance of cicatricial entropion in excessive removal of tarsus; so, one of the limitations could be the high mean age of the TCMLR procedure in comparison of the frontalis sling group. Additionally, in TCMLR group, the amount of tarsus and levator resection was not measured and also a limitation for TCMLR is the possibility to develop dryness because of the partial resection of the accessory lacrimal glands and Meibomian glands as well.

In conclusion, complete success rate of TCMLR is higher in long-term follow-up in contrast with the higher success of frontalis sling in the short-term. Transient complications were more detected in mid-term follow-ups in both groups.

TCMLR could be suggested as an alternate procedure instead of frontalis sling method to correct severe unilateral congenital ptosis with poor LF.

#### ACKNOWLEDGEMENTS

The authors wish to thank the staff and personnel, who greatly helped us to complete the project.

**Foundation:** Supported by Tehran University of Medical Sciences (No.9511257008).

**Conflicts of Interest:** Kasaei A, None; Aliabadi M, None; Najafi L, None; Jamshidian-Tehrani M, None.

#### REFERENCES

- 1 Lee JH, Kim YD. Surgical treatment of unilateral severe simple congenital ptosis. *Taiwan J Ophthalmol* 2018;8(1):3-8.
- 2 SooHoo JR, Davies BW, Allard FD, Durairaj VD. Congenital ptosis. *Surv Ophthalmol* 2014;59(5):483-492.
- 3 Medel R, Vasquez L, Wolley Dod C. Early frontalis flap surgery as first option to correct congenital ptosis with poor levator function. *Orbit* 2014;33(3):164-168.
- 4 Nucci P, Lembo A, Santangelo E, Fogagnolo P, Serafino M. Five-year follow-up of a 30-month trial of stability of silicone band frontalis suspension for the treatment of severe unilateral upper eyelid ptosis in infants. *Semin Ophthalmol* 2016;31(3):215-218.
- 5 Tabatabaie S, Momeni A, Rajabi M, Zarei M. Frontalis sling operation using silicone rods in comparison to pose-up for congenital ptosis with poor levator function. *Iranian J Ophthalmol* 2012.
- 6 Yoon JS, Lee SY. Long-term functional and cosmetic outcomes after frontalis suspension using autogenous fascia lata for pediatric congenital ptosis. *Ophthalmology* 2009;116(7):1405-1414.
- 7 Petroni S, Capozzi P, Parrilla R, Zinzanella G, Buzzonetti L. Surgical treatment of severe congenital ptosis using deep temporal fascia. *Orbit* 2019;38(4):313-317.
- 8 Zhang L, Zhai WJ, Yang LH, Sun CH, Pan Y, Zhao H. Comparative evaluation of conventional and modified frontalis muscle flap advancement techniques in the treatment of severe congenital ptosis: a retrospective cohort study. *PLoS One* 2021;16(2):e0246183.
- 9 Morris CL, Buckley EG, Enyedi LB, Stinnett S, Freedman SE. Safety and efficacy of silicone rod frontalis suspension surgery for childhood ptosis repair. *J Pediatr Ophthalmol Strabismus* 2008;45(5):280-288; quiz 289-290.
- 10 Ural Ö, Mocan MC, Erdener U. The value of the frontalis suspension procedure as a repeat intervention in congenital blepharoptosis. *J Pediatr Ophthalmol Strabismus* 2017;54(5):320-323.
- 11 Salour H, Aletaha M, Bagheri A. Comparison of mersilene mesh and autogenous fascia lata in correction of congenital blepharoptosis: a randomized clinical trial. *Eur J Ophthalmol* 2008;18(6):853-857.
- 12 Dallalzadeh LO, Park KS, Korn BS, Kikkawa DO, Liu CY. Minimal dissection direct frontalis muscle advancement flap for congenital ptosis repair. *J Craniofac Surg* 2021;32(7):2358-2361.
- 13 Zhu XY, Ma YJ, Woo DM, Lin YY, Chen B, Liu J, Chen X. Improved eyelid muscle tension balance with refined frontalis muscle flap

- suspension in the treatment of severe ptosis. *Ophthalmic Plast Reconstr Surg* 2021;37(6):534-540.
- 14 Zhang L, Ren MY, Yan YQ, Zhai WJ, Yang LH, Sun CH, Pan Y, Zhao H. Surgical correction of severe congenital ptosis using a modified frontalis muscle advancement technique: a single-arm trial. *Eur J Ophthalmol* 2022;32(1):115-121.
- 15 Zaky AG, Mandour SS, Zaky MA, Ebrahim AM. Two different techniques for frontalis suspension using Gore-Tex to treat severe congenital ptosis. *Graefes Arch Clin Exp Ophthalmol* 2017;255(4):831-835.
- 16 Kersten RC, Bernardini FP, Khouri L, Moin M, Roumeliotis AA, Kulwin DR. Unilateral frontalis sling for the surgical correction of unilateral poor-function ptosis. *Ophthalmic Plast Reconstr Surg* 2005;21(6):412-416; discussion 416-417.
- 17 Bernardini FP, Cetinkaya A, Zambelli A. Treatment of unilateral congenital ptosis: putting the debate to rest. *Curr Opin Ophthalmol* 2013;24(5):484-487.
- 18 Philandrianos C, Galinier P, Salazard B, Bardot J, Magalon G. Congenital ptosis: long-term outcome of frontalis suspension using autogenous temporal fascia or fascia lata in children. *J Plast Reconstr Aesthetic Surg* 2010;63(5):782-786.
- 19 Gazzola R, Piozzi E, Vaienti L, Wilhelm Baruffaldi Preis F. Therapeutic algorithm for congenital ptosis repair with levator resection and frontalis suspension: results and literature review. *Semin Ophthalmol* 2018;33(4):454-460.
- 20 Liu NH, He AJ, Wu D, Zhang J, Song N. Modified maximal levator palpebrae superioris shortening in correcting congenital severe ptosis in children. *Ann Plast Surg* 2021;87(5):523-527.
- 21 Mohammed NM, Kamal MA, Abdelhafez MA, Diab MM. Single-triangle versus Fox pentagon frontalis suspension for unilateral severe congenital ptosis correction. *J Am Assoc Pediatr Ophthalmol Strabismus* 2020;24(5):295.e1-295.e6.
- 22 Yagci A, Egrilmez S. Comparison of cosmetic results in frontalis sling operations: the eyelid crease incision versus the supralash stab incision. *J Pediatr Ophthalmol Strabismus* 2003;40(4):213-216.
- 23 Shimizu Y, Nagasao T, Shido H, Fujii T, Kato T, Aoki M, Takada K, Kishi K. Intra-eyebrow frontalis suspension using inverted Y-shaped short autogenous fascia lata for blepharoptosis with poor levator function. *J Plast Reconstr Aesthetic Surg* 2015;68(1):49-55.
- 24 Rosenberg JB, Andersen J, Barmettler A. Types of materials for frontalis sling surgery for congenital ptosis. *Cochrane Database Syst Rev* 2019;4:CD012725.
- 25 Lee MJ, Oh JY, Choung HK, Kim NJ, Sung MS, Khwarg SI. Frontalis sling operation using silicone rod compared with preserved fascia lata for congenital ptosis. *Ophthalmology* 2009;116(1):123-129.
- 26 Whitehouse GM, Grigg JR, Martin FJ. Congenital ptosis: results of surgical management. *Aust N Z J Ophthalmol* 1995;23(4):309-314.
- 27 Kabra R, Khatri P. Study of the outcome of various surgical procedures for simple congenital blepharoptosis. *Jemds* 2015;4(42):7396-7401.
- 28 Pang NK, Newsom RW, Oestreicher JH, Chung HT, Harvey JT. Fasanella-servat procedure: indications, efficacy, and complications. *Can J Ophthalmol* 2008;43(1):84-88.
- 29 Callahan A. Correction of unilateral blepharoptosis with bilateral eyelid suspension. *Am J Ophthalmol* 1972;74(2):321-326.
- 30 Beard C. A new treatment for server unilateral congenital ptosis and for ptosis with jaw winking. *Plast Reconstr Surg* 1965;36(6):637.