

Ocular syphilis resurgence in an urban underserved community in the United States

Emily K. Tam, Alexander Port, Diana Martin, Gabrielle Fridman, Steven Ness, Nicole H. Siegel

Department of Ophthalmology, Boston Medical Center, Boston, MA 02118, USA

Correspondence to: Emily K. Tam. Department of Ophthalmology, Boston Medical Center, 85 East Concord St, 8th Floor, Boston, MA 02118, USA. Kayi.Tam@bmc.org

Received: 2021-05-08 Accepted: 2022-05-27

Abstract

• **AIM:** To evaluate the clinical characteristics, demographics, and visual outcomes of patients with ocular syphilis at an urban hospital to increase awareness and assist in earlier diagnosis and treatment of the resurgent disease.

• **METHODS:** A retrospective chart review was performed on patients with ICD-9 and ICD-10 diagnosis codes correlating with syphilis or syphilis-related ocular diseases between 2010 and 2019. Variables evaluated included age, gender, race, vision, ocular findings, human immunodeficiency virus (HIV) status and men who have sex with men status, recreational drug and alcohol use.

• **RESULTS:** Ocular syphilis was diagnosed in 40 patients (53 eyes) of a total of 229 patients who tested positive for syphilis *via* serum and/or cerebrospinal fluid treponemal testing from 2010-2019. Among patients with ocular syphilis, most patients were males, aged 45 or above and Black, and had no diagnosed HIV infection. Approximately 50% patients had 20/40 vision or better. Nearly 50% had non-granulomatous anterior uveitis as their initial presentation, and 49% of patients had involvement of the posterior segment. Neovascular glaucoma (5.7%), papillitis (7.5%), vasculitis (5.7%), and retinal detachment (5.7%) were rarer presentations of the disease and were associated with a poorer visual prognosis.

• **CONCLUSION:** Given the increased prevalence and protean manifestations of syphilis, early diagnosis and treatment are paramount. More studies on ocular syphilis are warranted to understand this resurging disease.

• **KEYWORDS:** ocular syphilis; neurosyphilis; uveitis; surveillance; treponema pallidum

DOI:10.18240/ijo.2022.08.20

Citation: Tam EK, Port A, Martin D, Fridman G, Ness S, Siegel NH. Ocular syphilis resurgence in an urban underserved community in the United States. *Int J Ophthalmol* 2022;15(8):1357-1362

INTRODUCTION

According to the Centers for Disease Control and Prevention (CDC), there has been a surge of newly diagnosed cases of syphilis over the last 10y in the United States, and the numbers continue to rise^[1-2]. During 2013-2017, primary and secondary syphilis rates rose by 72.7% nationally (from 5.5 to 9.5 cases per 100 000 population) and increased by 155.6% among women (from 0.9 to 2.3 cases per 100 000)^[3-4]. Ocular syphilis, a rare but potentially blinding disease, would be expected to increase in prevalence in parallel to the rising rates of systemic syphilis^[4-5]. A clinical advisory was issued in 2016 by the CDC to reflect the resurgence of ocular syphilis after a small cluster of outbreak in San Francisco and Seattle^[1]. Syphilis risk factors identified in previous studies included being men who have sex with men (MSM), human immunodeficiency virus (HIV) positivity, unprotected sexual activity, and reported drug use^[5].

Though syphilis is a reportable disease, the CDC has not systematically collected surveillance data on its ocular manifestations. In this study, we investigate patients who were diagnosed with syphilis at Boston Medical Center (BMC), an urban, academic safety net hospital, which serves a vulnerable, at-risk patient population^[6-7]. A majority of patients come from underserved communities at greater risk of syphilis infection, including HIV/acquired immunodeficiency syndrome (AIDS) infection^[6,8]. This study investigates the patient characteristics and exam patterns of ocular syphilis patients in our institution.

SUBJECTS AND METHODS

Ethical Approval The study was approved by Boston University Medical Center's (BUMC) Institutional Review Board/Ethics Committee. This study was conducted in accordance with the Declaration of Helsinki. The collection and evaluation of all protected patient health information was performed in a Health Insurance Portability and Accountability Act (HIPAA)-compliant manner. In this retrospective chart review study, written informed consent was not required according to protocol.

In this retrospective study, we identified patients diagnosed with syphilis from 2010-2019 using the Boston University School of Medicine Clinical Data Warehouse (CDW), a searchable database of electronic medical records. The database was queried for ICD-9 and ICD-10 diagnosis codes to capture all syphilis-related ocular findings including 091.50 (syphilitic uveitis), 091.89 (other forms of secondary syphilis), 095.8 (other specified forms of late symptomatic syphilis), 363.13 (disseminated choroiditis and chorioretinitis, generalized), A51.43 (secondary syphilitic ophthalmopathy), A51.49 (other secondary syphilitic conditions), A52.71 (late syphilitic ophthalmopathy), H30.131 (disseminated chorioretinal inflammation, generalized, right eye), H30.132 (disseminated chorioretinal inflammation, generalized, left eye), H30.133 (disseminated chorioretinal inflammation, generalized, bilateral), 363.13 (disseminated choroiditis and chorioretinitis, generalized). The database was also searched for positive laboratory results consistent with a diagnosis of syphilis including rapid plasma reagin (RPR), Treponema pallidum particle agglutination assay (TPPA), fluorescent treponemal antibody absorption (FTA-ABS), and venereal disease research laboratory (VDRL). A list of likely ocular syphilis cases was generated using a “two-hit” method, in which subjects with both a relevant diagnosis code and a positive test result were included. Individual records were then reviewed in detail to verify diagnoses based on clinic notes and testing results. Patients with verified positive syphilis laboratory results and a diagnosis consistent with ocular syphilis were included in the cohort. The records were reviewed for patient characteristics and exam findings including demographics, medical history, syphilis diagnosis, ocular exam findings, HIV status, MSM status, and recreational drug and alcohol use. Subjects were excluded if the syphilis diagnosis could not be verified in the electronic medical record or if records were incomplete.

State level and national level data were collected from CDC National Center for HIV/AIDS, Viral Hepatitis, sexually transmitted disease (STD), and Tuberculosis (TB) Prevention (NCHHSTP) AtlasPlus^[9]. CDC data was compared to BUMC up to 2017 given availability of the data. Microsoft Excel and JMP[®] Pro 12.0.1 (SAS Institute, Cary, North Carolina, USA) were used to plot the progression of cases over time for comparison.

RESULTS

A total of 229 syphilis positive patients at BMC were included in the study. Table 1 reports demographics of patients who were diagnosed with syphilis versus the subset of patients with ocular syphilis. Among the cohort of patients, the majority were males (82.5% in non-ocular syphilis, and 72.5% in ocular syphilis patients) and a significant portion were Black

Table 1 Demographics of patients by ocular syphilis status n (%)

Parameters	With ocular syphilis (n=40)	Without ocular syphilis (n=189)
Gender		
Female	11 (27.50)	33 (17.46)
Male	29 (72.50)	156 (82.54)
Age range (y)		
<45	10 (25.00)	132 (69.84)
45-64	18 (45.00)	35 (18.52)
>65	12 (30.00)	20 (10.58)
Race		
Black	26 (65.00)	74 (39.15)
White	6 (15.00)	58 (30.69)
Latino	4 (10.00)	36 (19.05)
Asian	1 (2.50)	9 (4.76)
Other	3 (7.50)	12 (6.35)
Tobacco use		
Ever/current use	17 (42.50)	84 (44.44)
Never use	12 (30.00)	73 (38.62)
Recreational drug use		
Yes	6 (15.00)	65 (34.39)
No	20 (50.00)	95 (50.26)
Alcohol use		
Yes	7 (17.50)	101 (53.44)
No	18 (45.00)	51 (26.98)
Currently sexually active		
Yes	6 (15.00)	116 (61.38)
No	4 (10.00)	8 (4.23)
HIV status		
Yes	7 (17.50)	72 (38.10)
No	27 (67.50)	108 (57.14)
Men who have sex with men status		
Yes	2 (5.00)	90 (47.62)
No	13 (32.50)	45 (23.81)
Eye exam status		
Yes	40 (100.00)	47 (24.87)
No	0	140 (74.07)

HIV: Human immunodeficiency virus.

(39.2% in non-ocular syphilis, and 65.0% in ocular syphilis), and tobacco users (44.5% ever or current users in non-ocular syphilis, and 42.5% ever or current use in ocular syphilis). There is an upward trend syphilis cases from 2010 to 2017 at our institution, in Massachusetts and nationally (Figure 1).

Ocular syphilis was present in 40 (17.47%) patients with syphilis. When comparing patients with ocular syphilis and patients without ocular involvement, patients with ocular syphilis were above the age of 45 (30/40 or 75.0%), and a greater proportion were Black (26/40 or 65.0%) and less likely to have HIV (7/40 or 17.5%).

Thirty-eight of 53 eyes (71.70%) had visual acuity of 20/190 or better on presentation, with most visual acuities ranging from 20/20 to 20/40 (50.94%; Table 2). Fifteen eyes (28.30%)

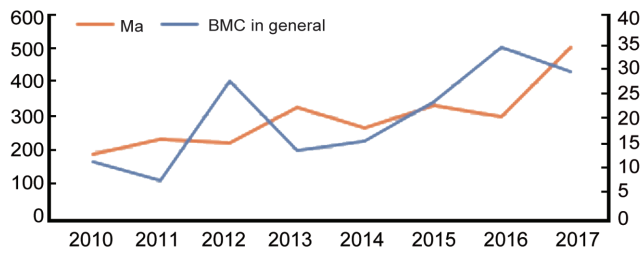


Figure 1 Boston Medical Center syphilis compared to Massachusetts state syphilis rates.

Table 2 Demographics among eyes with ocular syphilis (n=53)

Parameters	BCVA subcategories		
	>20/40 (n=27, 50.94%)	20/50-20/190 (n=11, 20.75%)	<20/200 (n=15, 28.30%)
Gender			
Female	8 (15.09)	4 (7.55)	3 (5.66)
Male	19 (35.85)	7 (13.21)	12 (22.64)
Age ranges (y)			
<45	7 (13.21)	1 (1.89)	5 (9.43)
45-64	14 (26.42)	3 (5.66)	6 (11.32)
>65	6 (11.32)	7 (13.21)	4 (7.55)
Race			
Black	13 (24.53)	8 (15.09)	11 (20.75)
White	7 (13.21)	1 (1.89)	1 (1.89)
Latino	4 (7.55)	0	1 (1.89)
Asian	2 (3.77)	0	0
Other	1 (1.89)	2 (3.77)	2 (3.77)
Tobacco use			
Ever/current use	11 (20.75)	1 (1.89)	9 (16.98)
Never	6 (11.32)	5 (9.43)	6 (11.32)
Recreational drug use			
Yes	6 (11.32)	0	2 (3.77)
No	11 (20.75)	4 (7.55)	12 (22.64)
Alcohol use			
Yes	4 (7.55)	2 (3.77)	1 (1.89)
No	11 (20.75)	3 (5.66)	11 (20.75)
Currently sexually active			
Yes	5 (9.43)	0	3 (5.66)
No	1 (1.89)	2 (3.77)	3 (5.66)
HIV status			
No	19 (35.85)	7 (13.21)	10 (18.87)
Yes	3 (5.66)	2 (3.77)	4 (7.55)
Men who have sex with men status			
Yes	1 (1.89)	0	0
No	9 (16.98)	4 (7.55)	5 (9.43)
History of penicillin use			
Yes	27 (50.94)	11 (20.75)	15 (28.30)

BCVA: Best-corrected visual acuity; HIV: Human immunodeficiency virus.

had vision of 20/400 or worse. Higher proportions of the subjects with poor vision were Black, had a history of or current tobacco use, and did not have a diagnosis of HIV.

Table 3 compares ocular data among patients with visual acuity of 20/40 or better, 20/50-20/190, or 20/400 or worse.

Table 3 Ocular findings among eyes with visual acuity of 20/40 or better, 20/50-20/190, and 20/400 or worse vision (n=53)

Parameters	BCVA subcategories		
	>20/40 (n=27, 50.94%)	20/50-20/190 (n=11, 20.75%)	<20/200 (n=15, 28.30%)
Intraocular pressure (mm Hg)			
<21	23 (43.40)	6 (11.32)	12 (22.64)
>21	3 (5.66)	4 (7.55)	2 (3.77)
Conjunctival injection			
Yes	14 (26.42)	6 (11.32)	3 (5.66)
No	13 (24.53)	5 (9.43)	12 (22.64)
Anterior uveitis			
Yes	17 (32.08)	6 (11.32)	4 (7.55)
No	10 (18.87)	5 (9.43)	11 (20.75)
Keratic precipitates			
Yes	4 (7.55)	3 (5.66)	4 (7.55)
No	23 (43.40)	8 (15.09)	11 (20.75)
Posterior synechiae			
Yes	5 (9.43)	2 (3.77)	3 (5.66)
No	22 (41.51)	9 (16.98)	12 (22.64)
Posterior involvement			
Yes	12 (22.64)	3 (5.66)	11 (20.75)
No	15 (28.30)	8 (15.09)	4 (7.55)
Vitritis			
Yes	7 (13.21)	1 (1.89)	7 (13.21)
No	20 (37.74)	10 (18.87)	8 (15.09)
Retinitis			
Yes	7 (13.21)	1 (1.89)	4 (7.55)
No	20 (37.74)	10 (18.87)	11 (20.75)
Papillitis			
Yes	2 (3.77)	0	2 (3.77)
No	25 (47.17)	11 (20.75)	13 (24.53)
Neovascular glaucoma			
Yes	1 (1.89)	0	2 (3.77)
No	26 (49.06)	11 (20.75)	13 (24.53)
Retinal detachment			
Yes	0	0	3 (5.66)
No	27 (50.94)	11 (20.75)	12 (22.64)

BCVA: Best-corrected visual acuity.

Most patients had intraocular pressure (IOP) of <21 mm Hg on presentation. Among patients with visual acuity of 20/40 or better, non-granulomatous anterior uveitis tended to be a common sign (17/27 patients). However, patients with visual acuity of 20/400 or worse were more likely to have posterior involvement (11/15). Less common presentations across all visual acuity groups included papillitis (7.6%), neovascularization glaucoma (5.7%), and retinal detachment (5.7%).

DISCUSSION

Literature regarding syphilis patient demographics has been overall mixed. While syphilis has been diagnosed in a variety of age distributions in our study cohort starting at age 20, our ocular syphilis data corresponds to CDC national data of syphilis being diagnosed at age 45 and above^[3-4]. In our cohort, ocular syphilis was more prevalent among Black

patients, which corresponds with CDC data that reported the prevalence of general syphilis in Black patients to be 4.5 times the rate among Caucasians^[3-4]. In our study, 65% of Blacks had ocular syphilis versus 15% of Whites. BMC serves an ethnically, financially, and geographically diverse patient population, with known syphilis risk factors, and has the largest HIV/AIDS programs in New England^[6-9]. According to Boston Public Health Commission's analysis of syphilis rates by neighborhood in Boston, MA, the communities with the highest density of syphilis cases are in the neighborhoods surrounding our medical center^[10]. Our cohort of ocular syphilis patients had low rates of HIV co-infection, which brings to light the CDC advisory noting an increase in syphilis cases across all demographics, even among groups not traditionally considered to be high risk^[3-4].

The general trend of syphilis in our data correlates to the CDC data (Figure 1). The aforementioned study in North Carolina also demonstrated a similar trend, especially with a 100% increase from 2014 to 2015^[11]. Our syphilis trends overall aligned with the greater national data. This may correspond to the hospital transitioning to electronic medical record system, Epic (Epic Systems Corporation, Verona, Wisconsin), in mid-2015, leading to a more streamlined tracking system for patients^[12]. It is possible that the surge in diagnosis was driven by the prevalence of risk factors and likely a confluence of factors leading to the rise in syphilis. Decreased fear of HIV and the rise of dating or "hookup" apps are thought to have led to more unsafe sex practices^[13]. In the United States, the nadir in syphilis cases occurred in 2000-2001, a time when HIV positive individuals were living significantly longer, as compared to the 1990s, but fear around HIV and STDs was still high, dating websites were still stigmatized and adherence to safe sex practices were likely greater^[13]. For instance, similar to our study, co-infections such as HIV was present even among patients without ocular syphilis. Since HIV patients are now living longer, they are being diagnosed with such co-infections as clinicians now understand the disease more^[14-15]. The CDC advisories included an increase in syphilis cases among groups that had not seen significant syphilis numbers earlier in the early 2000s, such as women, men who have sex with women (MSW), and HIV negative patients^[16-18]. It has also been speculated that the rise of syphilis corresponds to popularity of online dating, as online dating may increase opportunities for sexual contact^[13].

Our cohort had a higher prevalence of ocular syphilis (17.62%) compared to prior published studies, which reported a rate of 1.5% among 4232 syphilis patients in North Carolina^[11]. Similarly, the CDC found that within eight jurisdictions in 2016, ocular symptoms were present in 0.65% of those previously reported^[19-20]. Given the retrospective nature of

these studies, detection of ocular syphilis was limited to symptomatic cases. This likely underestimates the true number of ocular syphilis cases because the majority of patients retain good visual acuity and few patients have severe ocular inflammation. It is possible that an increase in the recognition of ocular manifestation may lead to more diagnoses of ocular syphilis^[21]. Furthermore, our search methods may have undercounted overall syphilis cases, given our two hit system, using the CDW data in addition to positive serology testing within our institution. This may explain why although we have a higher proportion of patients with ocular syphilis, our hospital only represents about 2% of the syphilis cases in Boston. For example, in 2018, according to the CDC, there were 973 cases of syphilis in Boston, whilst there were only 25 cases at BMC^[22].

While most patients with ocular syphilis maintain good visual acuity, our patients with posterior segment involvement tended to have poorer visual outcomes. A British study reported that average vision was 20/60 among ocular syphilis patients with final vision 20/40 or better^[23]. In our study, 11/53 (20.75%) had poor visual outcomes with vision less than 20/400, with 7/11 (63.64%) of those with posterior involvement. However, a study by Furtado *et al*^[24] found most patients to have visual acuity of 20/50 or worse, and had posterior involvement.

Research regarding the association between ocular syphilis and IOP is overall mixed. Our study showed that most ocular syphilis patients did not have high IOP on initial presentation. Syphilitic uveitis may be associated with elevated IOP, as syphilis can cause uveitic glaucoma^[25]. Similar to our study, a British 3-year national surveillance study of 59 patients found the mean intraocular pressure to be 13.9 mm Hg, with only one patient with elevated IOP^[23]. Also, a Meta-analysis by Zhang *et al*^[26] found IOP increase to arise in about 10% of presentation. Thus, our data supports that IOP can be low in ocular syphilis patients during initial presentation in the time of resurgence.

There are differences in our study compared to others that may give insight to presenting signs for syphilis resurgence. Similar to other studies, uveitis appears to be a common presentation among patients with ocular syphilis in our study. In a study reporting ophthalmic outcomes of ocular syphilis during the time of re-emergence, ocular involvement in 214 eyes included anterior uveitis (6.1%), intermediate uveitis (8.4%), posterior uveitis (76.2%), and panuveitis (8.4%). Ocular inflammation was bilateral in 87 patients (68.5%), giving a total of 214 involved eyes^[25-27]. Hong *et al*^[28] also found uveitis as a first sign of syphilis.

The forms of uveitis were overall mixed in literature. In our study, the most common form of uveitis among patients with ocular syphilis was non-granulomatous anterior uveitis followed by posterior involvement. However, among the 129

patients in the previously mentioned study by Furtado *et al*^[24] found that posterior uveitis accounts for the majority of cases of ocular syphilis most commonly posterior placoid chorioretinitis and syphilitic punctate inner retinitis. Another study from France also found most patients to be mostly posterior placoid chorioretinitis^[29]. Also, in a study showing the resurgence of ocular syphilis in British Columbia from 2013-2016, uveitis (93.5%) was most prevalent as retinal vasculitis in 54.3% of patients^[30]. Vasculitis, retinitis, and choroiditis were less common presenting signs in our cohort. We may be diagnosing more mild cases of uveitis before it becomes more vision threatening, which further explains the larger portion of our ocular syphilis case.

According to a study of 190 patients of 318 eyes, optic nerve involvement was also prevalent in 87.5% (papillitis, optic nerve swelling, or pallor)^[5]. Another study of 670 patients in a meta-analysis found that the most common type of syphilitic uveitis was papillitis^[26]. However, in our study optic nerve involvement was an uncommon presentation. This corresponds to the favorable visual acuity and higher prevalence anterior inflammation seen in our cohort.

A strength of the study includes it is the higher proportion of patients with ocular syphilis compared to other published studies. However, there were limitations to this study. One limitation is its retrospective nature and our data was limited to ophthalmologic data when the patient first presented with ocular syphilis, which provides information on the initial patient presentation but does not trend over time. Due to the retrospective nature of the study, some data was incomplete or limited by clinical practice patterns, for example, there was not enough information on MSM status as this is a voluntary question on clinical intake forms and many of the patients did not choose to answer the question.

In conclusion, ocular syphilis is a potentially vision threatening manifestation of systemic syphilis infection. Syphilis continues to be on the rise, and clinicians should be aware of this potentially sight and life-threatening condition. This study evaluates the prevalence and presentation of ocular syphilis during the time of resurgence. In our series, half of the patients with ocular syphilis presented a non-granulomatous anterior uveitis with a milder course, and the other half of our patients with posterior segment involvement tended to have poor visual outcomes. Our cohort of ocular syphilis patients had a 17% of HIV co-infection. Our experience regarding the ocular manifestations of this resurgent disease will help facilitate earlier diagnosis and treatment and to minimize the ocular morbidities associated with ocular syphilis, even among patients not traditionally considered as high risk. More studies on ocular syphilis are warranted to understand the broader scope of this resurging disease.

ACKNOWLEDGEMENTS

Conflicts of Interest: Tam EK, None; Port A, None; Martin D, None; Fridman G, None; Ness S, None; Siegel NH, None.

REFERENCES

- 1 Centers for Disease Control and Prevention. Clinical Advisory: Ocular Syphilis in the United States. Updated March 24, 2016. Accessed on June 6, 2020. <https://www.cdc.gov/std/syphilis/clinicaladvisoryos2015.htm>
- 2 Centers for Disease Control and Prevention. NCHHSTP Newsroom: New CDC Report: STDs Continue to Rise in the US. Updated October 8, 2019. Accessed on April 6, 2021. <https://www.cdc.gov/nchhstp/newsroom/2019/2018-STD-surveillance-report-press-release.html>
- 3 Centers for Disease Control and Prevention. Sexually Transmitted Diseases: Syphilis. Accessed on April 12, 2021. <https://www.cdc.gov/std/syphilis/>
- 4 Centers for Disease Control and Prevention. Sexually Transmitted Disease Surveillance 2017: National experiences Steep and Sustained Increases in Sexually Transmitted diseases. Updated October 15, 2018. Accessed on April 16, 2021. https://www.cdc.gov/std/stats17/2017-STD-Surveillance-Report_CDC-clearance-9.10.18.pdf
- 5 Pirani V, Pelliccioni P, De Turre S, Rosati A, Franceschi A, Cesari C, Nicolai M, Mariotti C. The eye as a window to systemic infectious diseases: old enemies, new imaging. *J Clin Med* 2019;8(9):1392.
- 6 Carraggi M. Four hospitals in MA are among nation's greatest. Boston, MA patch. Updated May 6, 2018. Accessed on May 28, 2020. <https://patch.com/massachusetts/boston/4-hospitals-ma-are-among-nations-greatest>
- 7 Boston Medical Center. Commitment to Our Community. Updated 2019. Accessed on June 10, 2020. <https://www.bmc.org/about-us/commitment-our-community>
- 8 Boston Medical Center. Infectious Diseases. Accessed on June 10, 2020. <https://www.bmc.org/infectious-diseases>
- 9 Boston Medical Center. Health City: HIV. Accessed on June 16, 2020. <https://www.bmc.org/healthcity/hiv>
- 10 Boston Public Health Commission. Syphilis rates by neighborhood: Boston—2013. Accessed on June 10, 2020. <https://www.bphc.org/healthdata/other-reports/Documents/SYP%202013.jpg>
- 11 Oliver SE, Cope AB, Rinsky JL, *et al*. Increases in ocular syphilis—north Carolina, 2014-2015. *Clin Infect Dis* 2017;65(10):1676-1682.
- 12 Becker's HealthCare. Boston Medical Center CIO Arthur Harvey talks Epic go-live, HER costs and at the of MU. Updated January 19, 2016. Accessed on June 16, 2020. <https://www.beckershospitalreview.com/healthcare-information-technology/boston-medical-center-cio-arthur-harvey-talks-epic-go-live-ehr-costs-and-the-end-of-mu.html>
- 13 Rocheleau, M. R.I. officials say dating apps contributing to rise in STDs. Published July 1, 2015. Accessed on June 16, 2020.
- 14 Wandeler G, Johnson LF, Egger M. Trends in life expectancy of HIV-positive adults on antiretroviral therapy across the globe. *Curr Opin HIV AIDS* 2016;11(5):492-500.

- 15 HIV.gov. Aging with HIV. Accessed on June 16, 2020. <https://www.hiv.gov/hiv-basics/living-well-with-hiv/taking-care-of-yourself/aging-with-hiv>.
- 16 Hazra A, Menza TW, Levine K, Grasso C, Mayer KH. Increasing syphilis detection among patients assigned male at birth screened at a Boston community health center specializing in sexual and gender minority health, 2005-2015. *Sex Transm Dis* 2019;46(6):375-382.
- 17 Golden MR, Dombrowski JC. Syphilis control in the postelimination era: implications of a new syphilis control initiative for sexually transmitted disease/human immunodeficiency virus programs. *Sex Transm Dis* 2018;45(9S Suppl 1):S86-S92.
- 18 Centers for Disease Control. Sexually Transmitted Disease Surveillance 2018. Updated 2018. Accessed on April 10, 2021. <https://www.cdc.gov/std/stats18/STDSurveillance2018-FULL-report.pdf>
- 19 Centers for Disease Control and Prevention. NCHHSTP Atlas Plus. Accessed on April 10, 2021. <https://www.cdc.gov/nchhstp/atlas/>
- 20 Centers for Disease Control and Prevention. Morbidity and Mortality Weekly Report. Ocular Syphilis – Eight Jurisdiction, United States, 2014-2015. Updated November 4, 2016. Accessed on April 6, 2021. <https://www.cdc.gov/mmwr/volumes/65/wr/mm6543a2.htm>
- 21 Centers for Disease Control and Prevention. Sexually Transmitted Disease. Clinical Advisory: Ocular Syphilis in the United States. Updated March 24, 2016. Accessed on April 6, 2021. <https://www.cdc.gov/std/syphilis/clinicaladvisoryos2015.htm>
- 22 Centers for Disease Control. 2018 Sexually Transmitted Disease Surveillance Report. Updated 2018. Accessed on April 10, 2021. <https://www.cdc.gov/nchhstp/newsroom/2019/2018-std-surveillance-report.html>
- 23 Mathew RG, Goh BT, Westcott MC. British Ocular Syphilis Study (BOSS): 2-year national surveillance study of intraocular inflammation secondary to ocular syphilis. *Investig Ophthalmol Vis Sci* 2014;55(8):5394-5400.
- 24 Furtado JM, Arantes TE, Nascimento H, *et al*. Author correction: clinical manifestations and ophthalmic outcomes of ocular syphilis at a time of re-emergence of the systemic infection. *Sci Rep* 2018;8(1):15902.
- 25 Reddy S, Cubillan LD, Hovakimyan A, Cunningham ET Jr. Inflammatory ocular hypertension syndrome (IOHS) in patients with syphilitic uveitis. *Br J Ophthalmol* 2007;91(12):1610-1612.
- 26 Zhang T, Zhu Y, Xu GZ. Clinical features and treatments of syphilitic uveitis: a systematic review and meta-analysis. *J Ophthalmol* 2017;2017:6594849.
- 27 Roy M, Roy AK, Farrell JJ. Ocular syphilis in an immunocompetent host. *IDCases* 2020;19:e00684.
- 28 Hong MC, Sheu SJ, Wu TT, Chuang CT. Ocular uveitis as the initial presentation of syphilis. *J Chin Med Assoc* 2007;70(7):274-280.
- 29 Pratas AC, Goldschmidt P, Lebeaux D, *et al*. Increase in ocular syphilis cases at ophthalmologic reference center, France, 2012-2015. *Emerg Infect Dis* 2018;24(2):193-200.
- 30 Eslami M, Nouredin G, Pakzad-Vaezi K, Warner S, Grennan T. Resurgence of ocular syphilis in British Columbia between 2013-2016: a retrospective chart review. *Can J Ophthalmol* 2020;55(2):179-184.