

Therapeutic potential of pupilloplasty combined with phacomulsification and intraocular lens implantation against uveitis-induced cataract

Hui Lu¹, Dou-Dou Chen², Si-Quan Zhu^{1,3}

¹Department of Ophthalmology, Beijing Tongren Hospital, Capital Medical University, Beijing 100730, China

²Department of Ophthalmology, Ineye Hospital of Chengdu University of Traditional Chinese Medicine, Chengdu 610072, Sichuan Province, China

³Department of Ophthalmology, Beijing Anzhen Hospital, Capital Medical University, Beijing 100029, China

Correspondence to: Si-Quan Zhu. Department of Ophthalmology, Beijing Anzhen Hospital, Capital Medical University, No.2, Anzhen Road, Chaoyang District, Beijing 100029, China. dr_siquan@163.com

Received: 2022-03-18 Accepted: 2022-05-11

Abstract

• **AIM:** To evaluate the therapeutic effect of pupilloplasty combined with phacomulsification and intraocular lens implantation (PPI) in uveitis-induced cataract.

• **METHODS:** Total 28 patients with uveitis-induced cataract were enrolled. Within 3mo before the PPI, 7 cases accompanied with glaucoma maintained carteolol hydrochloride for lowering intraocular pressure, and 1 case maintained glucocorticoid for anti-inflammation. The baseline characteristics, treatment processes, and outcomes of enrolled cases were retrospectively analyzed. Hematoxylin and eosin (HE) staining was performed to reveal the histopathological changes of iris tissues.

• **RESULTS:** Iris hemorrhage was the only intraoperative complication observed in 2 cases. After the surgery, normal intraocular pressure, right position of intraocular lens, and improved visual gain [best corrected visual acuity (BCVA)>0.5] were achieved. Postoperative keratic precipitates was observed in 2 cases, which was recovered within 1wk. During the follow-up of 5-10y, no recurrence of uveitis was found in 27 cases (96.43%). Uveitis only recurred in one case with the onset of ankylosing spondylitis. HE staining showed iris stroma (all samples), pigment cell hyperplasia in pigment epithelium ($n=9$) and stroma ($n=19$), inflammatory cell infiltration in iris ($n=7$), and neovascularization in iris surface ($n=2$).

• **CONCLUSION:** PPI improves the visual gain and prevents the long-term recurrence of uveitis in patients with uveitis-induced cataract, including those with preoperative intraocular pressure abnormality (glaucoma) and inflammation (active uveitis). Uveitis presents stroma atrophy, pigment cell hyperplasia, and inflammatory cell infiltration, even in a quiet state.

• **KEYWORDS:** uveitis; cataract; glaucoma; histopathology; recurrence

DOI:10.18240/ijo.2022.10.06

Citation: Lu H, Chen DD, Zhu SQ. Therapeutic potential of pupilloplasty combined with phacomulsification and intraocular lens implantation against uveitis-induced cataract. *Int J Ophthalmol* 2022;15(10):1598-1603

INTRODUCTION

Uveitis is a severe inflammatory ocular disease, which can lead to visual impairment and even irreversible blindness^[1]. The prevalence of uveitis depends upon multiple factors, including the age, sex, race, geographic distribution, environment, genetics, and social habits^[2]. The estimated annual incidence of uveitis is about 17-52 persons per 100 000 people, and a prevalence of approximately 38-284 cases per 100 000 people in some developed countries^[3-5]. Uveitis is usually classified based on anatomical location, duration and course of inflammation, and nature of inflammation. Anterior uveitis is the most prevalent form of uveitis, accounting for approximately >50% cases^[6]. In clinical, the uveitis is idiopathic in most cases (48%-70%), and the traumatic, inflammatory, and infectious immunologic disorders can also induce the occurrence of uveitis^[7]. Until now, the main treatment strategy for uveitis is to protect the ocular tissues from damage through inhibiting inflammation, and activating immunosuppression to stop fueling T cell reactivity^[8]. Topical corticosteroid is usually applied as the first-line therapy for uveitis. Conventional immunomodulatory agents are added as second-line therapy utilized for their durable control of ocular inflammation and as a steroid-sparing agent^[9]. However,

uveitis is easy to relapse even after effective treatment due to the reappearance of infectious organisms and the localization of immune complexes in the uveal tract^[10-11].

Uveitis can lead to a variety of complications, such as cataract, retinal neovascularization, chorioretinal scars, cystoid macular edema, glaucoma/hypertension, epiretinal membranes, and retinal detachment^[12]. Cataract is one of the most frequent complications of uveitis, and also a major cause of visual loss^[13]. Both the intraocular inflammation and the long-term local or systemic use of corticosteroid contribute to the onset of cataract^[14-15]. Phacomulsification combined with intraocular lens implantation (PI) is a commonly used cataract surgery in outpatients, but its application is still a great challenge for patients with uveitis. The outcomes of PI in cases with uveitis is not predictable due to diverse factors, including surgical techniques, uncertain inflammatory sequelae, and the variable and unpredictable reversibility of complications^[13]. Patients with a history of uveitis are at higher risk for post-operative and recurrent inflammation following PI^[15-17]. Before PI, the quiescent uveitis for at least 3mo is generally accepted as the minimum amount of time prior to surgical intervention^[15]. Scrupulous case selection and aggressive control of pre- and postoperative intraocular inflammation are also important for the postoperative success^[18]. Recently, some encouraging outcomes on visual acuity were revealed in patients with uveitic cataract following PI. For example, Singh *et al*^[19] have shown that the best corrected visual acuity (BCVA) is improved in 92.58% ($n=50$) eyes with uveitis and cystoid macular edema was only found in 5% ($n=3$) eyes after PI. Yangzes *et al*^[18] have revealed that all children with uveitic cataract had significant improvement in BCVA post PI, and 55.17% ($n=32$) eyes achieved a visual acuity of 20/40 or more. Balta *et al*^[20] have found that the BCVA of 20/40 or better was achieved in 81.8% eyes ($n=18$) in idiopathic anterior uveitis, 80.0% eyes ($n=8$) in herpes simplex virus-associated anterior uveitis, 90.0% eyes ($n=9$) in Fuchs' heterochromic iridocyclitis, and 100% ($n=13$) in anterior uveitis associated with collagen vascular diseases over 4y follow-up of PI. However, it is worth noting that uveitis is usually not quiescent after cataract surgery, and the recurrence of uveitis can be observed at an uncertain time^[20-21].

Pupilloplasty is a technique for pupil reconstitution, which can enlarge any inadequately dilated pupil to ensure the safety and feasibility of PI. Pupilloplasty combined with PI (PPI) has been applied in the treatment of cataract accompanied with abnormal iris and pupil. However, the therapeutic effect of PPI on uveitis-induced cataract is rarely reported. In this study, PPI was performed in 28 patients with uveitis-induced cataract. The baseline characteristics, treatment processes, and outcomes were retrospectively analyzed. Furthermore,

the histopathological changes of iris tissues were evaluated. Our findings may provide guidance for the clinical treatment of uveitis-induced cataract and reveal the underlying histopathological mechanism of uveitis.

SUBJECTS AND METHODS

Ethical Approval This study was approved by the Ethics Committee of Beijing Tongren Hospital in accordance with the Declaration of Helsinki (TRECKY2012-02). Written informed consents were obtained from all cases.

Subjects Totally 28 patients with uveitis-induced cataract were screened from Beijing Tongren Hospital (Beijing, China) between July, 2009 and March, 2013. The uveitis-induced cataract was diagnosed as any lens opacity with visual acuity of 20/40 or less in the absence of other causes of visual loss according to Lens Opacities Classification System.

Surgery PPI was performed in all patients by an experienced surgeon. Simply, the target eyes were anesthetized by eye dropping of obukaine, the conjunctival sac was washed with povidone iodine, and a transparent corneal incision was made. Viscoelastic agent was then injected into the anterior chamber, and the adhesive iris tissues were pull open. The pathological tissues in the pupil area were cut off for patients with severe proliferation and even pupillary atresia. A round pupil with a diameter of about 4 mm was formed. After continuous curvilinear capsulorhexis, and water separation and stratification, turbid lens were removed by phacoemulsification, residual cortex was perfused and suctioned, and intraocular lens was implanted in the capsule bag. Followed by watertight incision, the operated eyes received eye ointments of tobramycin and dexamethasone and covered by clean dressing. All patients were followed up for 5-10y. The baseline characteristics, treatment processes, and outcomes of enrolled cases were reordere.

Histopathological Examination The iris tissues were collected from patients during surgery. The isolated tissues were immediately fixed in 10% formaldehyde, dehydrated in graded ethanol (70% to 100%), cleared in xylene, paraffin-embedded, and sliced at 5 μ m. After dewaxed in xylene and rehydrated in graded ethanol, the tissue sections were stained with hematoxylin and eosin (HE). The histopathological changes of iris tissues were observed under a microscope (IX71, Olympus, Japan).

RESULTS

Baseline Characteristics of Patients with Uveitis-induced Cataract A total of 28 patients with an age range of 14-82 years old were enrolled in this study, among which 10 (35.71%) were males and 18 (64.29%) were females. All the enrolled patients had suffered from anterior uveitis. Except that in 2 cases with ankylosing spondylitis and 1 case with Sjogren's syndrome, the uveitis in the left 25 cases were all

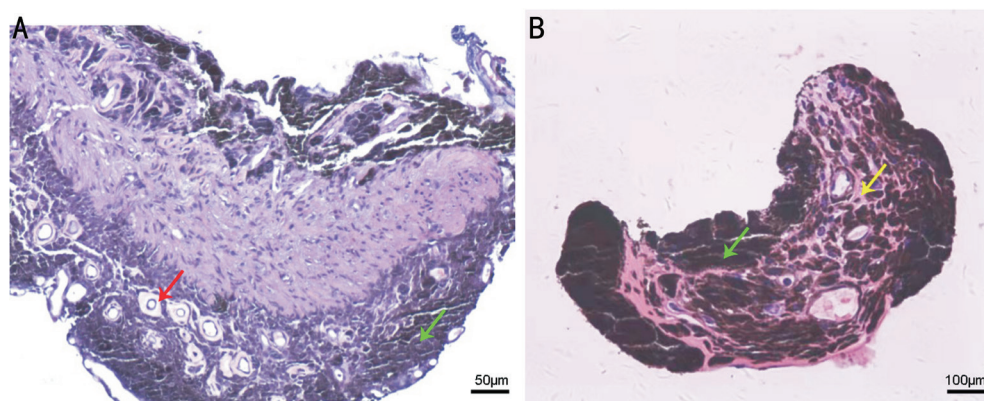


Figure 1 HE staining observation of the histopathological changes of iris tissues in two representative patients Green arrow: Hyperplasia of pigment cells; Yellow arrow: Obvious atrophy of iris stroma; Red arrow: Neovascularization in iris surface. HE: Hematoxylin and eosin.

idiopathic. The uveitis-induced cataract was subsequently determined in all enrolled cases, including 7 cases accompanied with glaucoma. The preoperative BCVA was 0.6 in 1 case, <0.5 in 21 cases, and <0.1 in 6 cases (Table 1).

Perioperative Intervention and Surgery Within 3mo before the surgery, 20 cases with well-controlled inflammation had no topical medication, 7 cases with uveitis-induced glaucoma maintained topical eye drops of carteolol hydrochloride for lowering intraocular pressure, and 1 case with uncontrolled inflammation also received eye drops of glucocorticoid for anti-inflammation. In the perioperative period (3d before the surgery), all cases received eye drops of levofloxacin four times a day. Two cases with uncontrolled intraocular pressure received intravenous injection of 20% mannitol, and the intraocular pressure was immediately decreased to <26 mm Hg in 1 case after the injection for 30min. However, the intraocular pressure was not reduced to a normal level for another case (>26 mm Hg), and preoperative anterior chamber puncture was performed. Subsequently, PPI was successfully performed in all case. Iris hemorrhage was the only intraoperative complication observed in 2 cases (Table 1).

Postoperative Care and Follow-up After surgery, all patients received 3wk of topical eye drops of tobramycin and dexamethasone for anti-inflammation, as well as topical eye drops of recombinant bovine basic fibroblast growth factor for nutrition. One case with aqueous flare continued to use the above topical eye drops until the inflammation was disappeared (at the 6th week after the surgery). There was an obvious improvement in visual gain of all cases, with a preoperative BCVA of >0.5. These patients also exhibited normal intraocular pressure, right position of intraocular lens, and no occurrence of the complications of posterior cataract, corneal edema, and corneal decompensation. In addition, postoperative keratic precipitates was found in 2 cases, which was recovered within 1wk. During the follow-up of 5-10y, no recurrence of uveitis was found in 27 cases (96.43%). Notably, uveitis recurred in one case with

Table 1 The baseline characteristics, treatments, and outcomes of patients with uveitis-induced cataract

Parameters	Baseline characteristics
Age	14-82y
Gender	Males (<i>n</i> =10) Females (<i>n</i> =18)
Inducement	Ankylosing spondylitis (<i>n</i> =2) Sjogren's syndrome (<i>n</i> =1) Idiopathic (<i>n</i> =25)
Complications	Glaucoma (<i>n</i> =7)
Preoperative BCVA	0.6 (<i>n</i> =1) <0.5 (<i>n</i> =21) <0.1 (<i>n</i> =6)

BCVA: Best corrected visual acuity.

the onset of ankylosing spondylitis at the 6th week after the surgery.

Histopathological Manifestations of Iris Tissues HE staining was performed to reveal the histopathological changes of iris tissues from patients. All samples exhibited atrophy of iris stroma (Figure 1). The hyperplasia of pigment cells was observed in the pigment epithelium (*n*=9, 32.14%) and even invaded into stroma (*n*=19, 67.86%; Figure 1). In addition, the infiltration of inflammatory cells in iris tissues was found in 7 cases (25.00%), and neovascularization in the surface of the iris was found in 2 cases (7.14%; Figure 1A).

DISCUSSION

Cataract is one of the most frequent complications of uveitis, which can be induced by chronic inflammatory response and use of corticosteroids^[22]. Surgery is generally considered as the only effective therapeutic strategy for uveitis-induced cataract, and the commonly used surgical strategies include extracapsular extraction, intracapsular extraction, lensectomy, and phacoemulsification^[23]. At present, the surgical program for uveitic cataract mainly depends on the experience of doctors. There is still no clear standard for the selection of scrupulous cases, indications and contraindications, surgical techniques, and operation time^[13,18]. Rojas *et al*^[24] have

described four indications for cataract surgery in patients with a history of uveitis, including phacoantigenic uveitis (active inflammation as a result of leak-age of lens proteins), visually significant cataract, cataract that impairs fundus assessment in cases with suspected fundus pathology, and cataract that precludes adequate visualization of the posterior segment in cases undergoing posterior segment surgical procedure. In this study, all the enrolled patients with uveitis-induced cataract belong to the indication of visually significant cataract, and the surgery of PPI was performed. Encouragingly, obvious visual gain improvement (BCVA>0.5), normal intraocular pressure, and right position of intraocular lens were revealed in call cases after the surgery. These findings indicate that the surgery proposed in this study can effectively treat uveitis-induced cataract.

Except the need of immediate mandatory cataract extraction for phacoantigenic uveitis, preoperatively control of inflammation for at least 3mo has become the guarantee of successful surgery. A Meta-analysis based on 89 articles has shown that among uveitic eyes with quiet uveitis before cataract surgery, visual acuity of 20/40 or better was achieved in 68% following phacoemulsification, 72% following extracapsular cataract extraction, and 40% following pars plana lensectomy^[25]. Similar with this consensus, 27 cases (96.93%) had no anti-inflammatory medication against uveitis within 3mo. Notably, one case with uncontrolled preoperative inflammation also achieved good outcome. This phenomenon indicates that the PPI may also be suitable for patients with activate uveitis. On the other hand, glaucoma is another potentially blinding complication of uveitis, which can be induced by inflammation, secondary corticosteroid response, and angle abnormalities^[26]. The surgery is thought to be necessary for glaucoma patients who cannot control the inflammation by drugs. In this study, 7 cases with uveitis-induced cataract were accompanied with glaucoma. Under actively control of intraocular pressure in perioperative period, obvious improvement in visual gain and normal intraocular pressure were achieved following the surgery. The surgery may contribute to the excretion of immune complexes, prostaglandins, and toxic substances in aqueous humor, thereby controlling intraocular pressure and inflammatory reaction.

Although the cataract surgery achieves relatively good outcome on visual gain in patients with uveitic cataract, postoperative complications and recurrence are still difficult problem to solve. For example, Rahman and Jones^[27] have shown that during a minimum follow-up of 5y, 24% macular oedema or scarring, 96% posterior capsule opacification, 15% glaucoma drainage were found in 61 patients underwent cataract extraction with intraocular lens implantation. Yangzes *et al*^[18] have revealed that the complications of visual axis

opacification (39.66%), cystoid macular edema (31.03%), and glaucoma (8.62%) were common in total 58 eyes underwent cataract surgery. Here, only the occurrence of keratic precipitates was found in 2 cases after the surgery. This complication may be attributed to the prolonged inflammatory response induced by local dysimmunity. There is nothing to worry that the keratic precipitates was recovered within 1wk. On the other hand, the recurrence risk of uveitis remains. Zhang *et al*^[21] have found that uveitis recurred in 14 eyes (18.9%) within 3mo and inflammation recurred in 34 eyes (45.9%) in the whole follow-up period. Balta *et al*^[20] have determined that the incidence of postoperative recurrence of uveitis was 52.7% in 48 patients underwent cataract surgery during 4y of follow-up. Therefore, avoiding postoperative recurrence has become a great challenge in clinical practice. In this study, in addition to the phacoemulsification with clear-cornea incision and intraocular lens implantation, pupilloplasty was also performed in patients with uveitic cataract. Encouragingly, no recurrence of uveitis was found in 96.43% cases ($n=27$) during the follow-up of 5-10y. Evidence on the underlying pathological mechanism of chronic uveitis showed that the lymphocytes in patients with uveitis exhibit great resistance to apoptosis, resulting in long-term existence of autoreactive lymphocytes, and subsequently leading to the chronicity and recurrence of uveitis. In addition, the destruction of blood aqueous barrier induced by inflammation leads to severe damage of iris microcirculation through enhancing the permeability of blood vessels and weakening the barrier function. Then freely released immune cells and inflammatory mediators directly contribute to the expansion of inflammatory injury. Therefore, we speculated that the low recurrence of uveitis revealed in this study may be attributed to the removal of pathological tissues to some degrees. Furthermore, the only patient with recurrent uveitis attributed to immunosuppression induced by the onset of ankylosing spondylitis. Our results indicated that pupilloplasty may reduce the recurrent risk of uveitis due to iris inflammation. However, the inflammation induced by other immunologic disorders is still inevitable for the recurrence of uveitis.

A previous study based on equine experimental uveitis has observed the histopathological characteristics of engorgement of blood vessels, neovascularization, focal or diffuse mononuclear proliferation, exudative retinal detachment, and disorganization of retinal layers^[28]. In order to discover the underlying pathological mechanism of uveitis in human, HE staining was performed to reveal the histopathological changes of uveitis-suffered iris tissues in this study. An obvious atrophy of iris stroma was observed in all cases, which is considered as a prominent feature of uveitis. The inflammation-induced immune abnormality may contribute directly to the iris

atrophy in uveitis. Since iris cells have an ability to bind and accumulate drugs^[29], the atrophy of iris tissues may contribute to the recurrent of uveitis *via* inhibiting the combination and reactivity of drugs. In addition, uveitis is known to be initiated by the recognition of T cells to retinal or cross-reactive antigens, and the recruited inflammatory cells result in the damage of specific tissues. The inhibition of inflammation and immunosuppression has become the preferred therapeutic strategy for uveitis^[8]. Here, we observed the infiltration of inflammatory cells in iris tissues in 25% cases. Since the uveitis in most cases (27/28) enrolled in this study was at a quiet period, our finding indicated that the inflammation is not really quiet in some patients. This phenomenon explained the possible reasons for poor postoperative outcome and easy recurrence in patients with uveitis, and challenged the existing standards for uveitis staging. Notably, whether there was inflammatory cell infiltration or not, the hyperplasia of pigment cells was observed in the pigment epithelium (32.14%) and stroma (67.86%). This phenomenon may be explained that the local immune injury greatly influences the normal structure of iris tissue, leading to the abnormal proliferation of pigment cells. This finding also indicated that pigment cells may play a positive role in inflammation by acting in situ antigen presenting cells, providing a potential target for the treatment of uveitis. Furthermore, the removal of lesion tissues during PPI did not cause the recurrence of uveitis, but prevented recurrence in most cases (27/28). However, the surgical boundary, timing, and outcomes of pathological tissue resection during PPI still need to be studied.

In conclusion, PPI was effective in improving the visual gain and preventing the long-term recurrence of uveitis in patients with uveitis-induced cataract, including those with preoperative intraocular pressure abnormality (glaucoma) and inflammation (active uveitis). The atrophy of iris stroma was the prominent feature of uveitis. The hyperplasia of pigment cells and infiltration of inflammatory cells in iris could also be observed in some cases, even in a quiet state.

ACKNOWLEDGEMENTS

Authors' contributions: Lu H, Chen DD, and Zhu SQ were involved in the conception and design of the study; Lu H and Zhu SQ were involved in the data collection; Lu H and Chen DD were involved in the analysis and the interpretation of data; Lu H and Chen DD were involved in writing the drafts of the manuscript. All authors critically revised the manuscript and gave final approval of the submitted manuscript.

Conflicts of Interest: Lu H, None; Chen DD, None; Zhu SQ, None.

REFERENCES

1 Yuan ZH, Chen XY, Yang WM, Lou BS, Ye N, Liu YZ. The anti-inflammatory effect of minocycline on endotoxin-induced uveitis and

retinal inflammation in rats. *Mol Vis* 2019;25:359-372.

- 2 Tsirouki T, Dastiridou A, Symeonidis C, Tounakaki O, Brazitikou I, Kalogeropoulos C, Androudi S. A focus on the epidemiology of uveitis. *Ocular Immunol Inflamm* 2018;26(1):2-16.
- 3 Prete M, Dammacco R, Fatone MC, Racanelli V. Autoimmune uveitis: clinical, pathogenetic, and therapeutic features. *Clin Exp Med* 2016;16(2):125-136.
- 4 Gritz DC, Wong IG. Incidence and prevalence of uveitis in northern California. *Ophthalmology* 2004;111(3):491-500.
- 5 Rim TH, Kim SS, Ham DI, Yu SY, Chung EJ, Lee SC, Society KU. Incidence and prevalence of uveitis in South Korea: a nationwide cohort study. *Br J Ophthalmol* 2018;102(1):79-83.
- 6 Duplechain A, Conrady CD, Patel BC, Baker S. Uveitis. *StatPearls* 2022
- 7 Harthan JS, Opitz DL, Fromstein SR, Morettin CE. Diagnosis and treatment of anterior uveitis: optometric management. *Clin Optom (Auckl)* 2016;8:23-35.
- 8 Wildner G, Diedrichs-Möhrling M. Resolution of uveitis. *Semin Immunopathol* 2019;41(6):727-736.
- 9 Trivedi A, Katelaris C. The use of biologic agents in the management of uveitis. *Intern Med J* 2019;49(11):1352-1363.
- 10 O'Connor GR. Factors related to the initiation and recurrence of uveitis. *Am J Ophthalmol* 1983;96(5):577-599.
- 11 Cai JF, Qi L, Chen Y, Zou J, Shen Y, Luo D, Bao HF, Ye JF, Ma HF, Guan JL. Evaluation of factors for predicting risk of uveitis recurrence in Behcet's disease patients. *Revista Brasileira De Pesquisas Med E Biol* 2020;53(6):e9118.
- 12 Prete M, Guerriero S, Dammacco R, Fatone MC, Vacca A, Dammacco F, Racanelli V. Autoimmune uveitis: a retrospective analysis of 104 patients from a tertiary reference center. *J Ophthalmic Inflamm Infect* 2014;4:17.
- 13 Chu CJ, Dick AD, Johnston RL, Yang YC, Denniston AK, Group UKPMES. Cataract surgery in uveitis: a multicentre database study. *Br J Ophthalmol* 2017;101(8):1132-1137.
- 14 Dick AD, Tundia N, Sorg R, Zhao C, Chao JD, Joshi A, Skup M. Risk of ocular complications in patients with noninfectious intermediate uveitis, posterior uveitis, or panuveitis. *Ophthalmology* 2016;123(3):655-662.
- 15 Llop SM, Papaliadis GN. Cataract surgery complications in uveitis patients: a review article. *Semin Ophthalmol* 2018;33(1):64-69.
- 16 Elgohary MA, McCluskey PJ, Towler HM, Okhravi N, Singh RP, Obikpo R, Lightman SS. Outcome of phacoemulsification in patients with uveitis. *Br J Ophthalmol* 2007;91(7):916-921.
- 17 Chiu H, Dang H, Cheung C, Khosla D, Arjmand P, Rabinovitch T, Derzko-Dzulynsky L. Ten-year retrospective review of outcomes following phacoemulsification with intraocular lens implantation in patients with pre-existing uveitis. *Can J Ophthalmol* 2017;52(2):175-180.
- 18 Yangzes S, Seth NG, Singh R, Gupta PC, Jinagal J, Pandav SS, Gupta V, Gupta A, Ram J. Long-term outcomes of cataract surgery in children with uveitis. *Indian J Ophthalmol* 2019;67(4):490-495.

- 19 Singh K, Shrestha S, Manandhar A. Outcome of cataract surgery in eyes with uveitis. *Nepal J Ophthalmol* 2019;11(22):152-157.
- 20 Balta O, Sungur G, Acar MA, Kosker M, Yakin M, Ornek F. Long-term results of cataract surgery in patients with anterior uveitis. *Int Ophthalmol* 2018;38(4):1399-1407.
- 21 Zhang YL, Zhu XJ, He WW, Jiang YX, Lu Y. Efficacy of cataract surgery in patients with uveitis. *Medicine (Baltimore)* 2017;96(30):e7353.
- 22 Sheppard JD Jr, Nguyen QD, Usner DW, Comstock TL. Post-cataract outcomes in patients with noninfectious posterior uveitis treated with the fluocinolone acetonide intravitreal implant. *Clin Ophthalmol* 2012;6:79-85.
- 23 Heiligenhaus A, Walscheid K, Pleyer U. Cataracts in uveitis. *Klin Monbl Augenheilkd* 2018;235(5):568-575.
- 24 Rojas B, Zafirakis P, Foster CS. Cataract surgery in patients with uveitis. *Curr Opin Ophthalmol* 1997;8(1):6-12.
- 25 Mehta S, Linton MM, Kempen JH. Outcomes of cataract surgery in patients with uveitis: a systematic review and meta-analysis. *Am J Ophthalmol* 2014;158(4):676-692.e7.
- 26 Sng CCA, Ang M, Barton K. Uveitis and glaucoma. *Prog Brain Res* 2015;221:243-269.
- 27 Rahman I, Jones NP. Long-term results of cataract extraction with intraocular lens implantation in patients with uveitis. *Eye (Lond)* 2005;19(2):191-197.
- 28 Simeonova GP, Krastev SZ, Simeonov RS. Immunological and pathological investigations in equine experimental uveitis. *Vet Res Commun* 2016;40(3):107-115.
- 29 Barza M, Kane A, Baum J. Marked differences between pigmented and albino rabbits in the concentration of clindamycin in iris and choroid-retina. *J Infect Dis* 1979;139(2):203-208.