

Spontaneous dislocation of a toric implantable collamer lens resulting in corneal endothelial decompensation: a case report and review of the literature

Li Zhang, Yan-Xi Li, Chun-Yan Lei, Lin Wang, Mei-Xia Zhang

Sichuan University West China Hospital, Chengdu 610041, Sichuan Province, China

Correspondence to: Lin Wang and Mei-Xia Zhang. Sichuan University West China Hospital, Chengdu 610041, Sichuan Province, China. 18980601745@163.com; zhangmeixia@scu.edu.cn

Received: 2022-01-13 Accepted: 2022-09-22

DOI:10.18240/ijo.2023.01.20

Citation: Zhang L, Li YX, Lei CY, Wang L, Zhang MX. Spontaneous dislocation of a toric implantable collamer lens resulting in corneal endothelial decompensation: a case report and review of the literature. *Int J Ophthalmol* 2023;16(1):135-138

Dear Editor

We present a case of spontaneous dislocation of a toric implantable collamer lens (TICL) resulting in corneal endothelial decompensation 8y after implantation. Since 2006, by helping people take off their glasses, the Visian TICL (Staar Surgical Co, Monrovia, CA, USA) have gained popularity in China. Though complications of intraocular pressure (IOP) elevation, cataract formation and endothelial damage exist as relevant problems, implantable collamer lens (ICL) implantation has been generally accepted as a viable option to correct moderate to high ametropia^[1-2].

Dislocation of ICLs and corneal decompensation are both rare complications as described in previous literature. To our best knowledge, this is the first report of spontaneous dislocation of a TICL resulting in corneal endothelial decompensation with the TICL behind the iris. By reviewing the literature, we summarized the clinical characters and potential factors leading to postoperative ICL dislocation in previously reported cases of ICL dislocation.

Ethical Approval The study was conducted in accordance with the Declaration of Helsinki. Informed consent was obtained from the patients.

Case Report A 47-year-old gentleman presented to us in May 2021 with complaints of foggy vision with foreign body

sensation and photophobia in his right eye of 1y duration. He received bilateral ICL implantations for correction of high ametropia in 2013. No medical history of systemic or ocular diseases was presented by the patient. His preoperative best-corrected visual acuity (BCVA) was 20/20 in the right eye (refraction, $-18.00/-2.00 \times 5^\circ$) and 20/30 in the left eye (refraction, $-20.5/-3.00 \times 170^\circ$). In the right and left eye, respectively, the anterior chamber depths (the distance between the corneal endothelium and the anterior lens capsule) were 2.80 and 2.71 mm, the white-to-white (WTW) diameters were 10.9 and 11.1 mm, and the corneal thickness were both 533 μm . Laser iridotomy was performed in both eyes two months before the TICL implantation surgery. Data was calculated basing on the TICL software (STAAR Surgical Company, Monrovia, CA, USA). According to the results, we chose the TICMV4 model, with a power of $-23.00/+2.5 \times 95^\circ$ for the right eye and -23.00 sphere for the left eye. Ametropia of the left eye wasn't fully corrected because no matched ICL was manufactured at the time. The diameter of ICLs were 11.5 mm for both eyes. Surgery in both eyes was uneventful. Postoperatively, the TICL in the right eye slightly rotated and prolapsed. With consent, another TICL with a diameter of 12.0 mm and a power of $-23.00/+2.5 \times 100^\circ$ was later implanted in the right eye after the former one was explanted. However, the TICL again prolapsed with slight rotation postoperatively. Since the optical zone of the TICL still remained in the central front of the pupil, the patient regained a satisfactory distance uncorrected visual acuity (UCVA) of 20/20. Clinical decision for explantation of the TICL in the right eye was made. However, the man refused to take further surgery and was lost to follow up in the following 8y.

On presentation, UCVA was hand motion for the right eye and 20/200 (refraction, -4.00) for the left eye. IOP was 20 mm Hg for the right eye and 18 mm Hg for the left eye. Slit-lamp examination after pupillary dilatation showed rotation of approximately 45° and prolapse of the TICL in the right eye with corneal edema (Figures 1 and 2). The corneal endothelial cell density was 2281 cells/ mm^2 for the left eye, while unobtainable for the right eye. Examination of ultrasound

biomicroscopy (UBM) showed that the TICL was still behind the iris, but the edges of the TICL arched forward into the anterior chamber (Figure 3). The patient denied history of trauma or strenuous activity. And it had been nearly one year since he started experiencing blurred vision with foreign body sensation and photophobia in his right eye.

With consent, phacoemulsification and intraocular lens implantation after explantation of the TICL was performed on his right eye, and a capsular tension ring was also implanted due to detected unstable zonules. Three months later, descemet's stripping endothelial keratoplasty was performed for restoring visual acuity.

Dislocation of an ICL has been described several times in previous reports^[3-10] (Table 1) and most of the cases were related with ocular trauma^[3,6-7,9-10]. Occiput injury had been reported once as the reason for ICL dislocation^[5]. And the author hypothesized the phakic ICL was pushed forward by the tremendous shock wave from backside in condition of a relatively dilated pupil in dark environment.

Spontaneous dislocation of an ICL was a relatively rarer situation which had also been described twice in the literature^[4,8]. The first case was reported in 2005^[4], which was relevant with rupture of the zonules. The recent one had reported a case of spontaneous dislocation of the ICL into the anterior chamber due to mydriasis induced by oral antidepressants^[8]. Corneal endothelial decompensation was not presented in any of these cases except for one, in which the ICL was dislodged into the anterior chamber with corneal touch because of ocular blunt trauma^[3].

Ciliary body morphology is now accessible using UBM, which is helpful for us to observe the intraocular position of ICLs^[11]. In a recent case report by Chen *et al*^[12], spontaneous rotation of approximately 90° of a TICL reoccurred at one day and a month after implantation. A posteriorly positioned ciliary body, a short and small ciliary process and a shallow ciliary sulcus were found in UBM images from this patient. Part quadrant of the ciliary sulcus lost its normal length and exhibited a nearly obtuse angle. A replacement of the TICL with a larger size non-toric ICL was performed, and the post-operative outcome in follow-up was excellent. The varied structure of ciliary sulcus in this case is quite similar to that of our case (Figure 4). With the change of accommodation states, the footplates may slide down to the ciliary body or even get a chance to cross over the small ciliary body and finally rest on the zonules. Besides, hypermyopia is typically accompanied by weak zonules which may easily be ruptured by the misplaced footplates of a TICL with the assistance of gravity, causing the TICL to sublunate inferiorly.

Endothelial damage was widely concerned for the safety after ICL implantation. Endothelial damage caused by ICL-

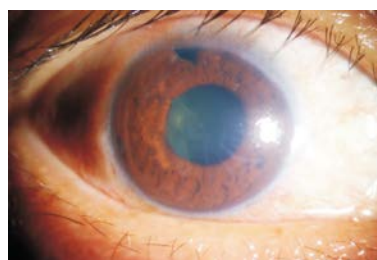

Figure 1 Anterior segment photograph showing prolapse of the toric implantable collamer lens in the right eye with corneal edema.

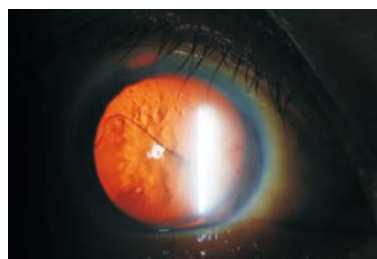

Figure 2 Largely rotated and inferiorly sublaxated toric implantable collamer lens.

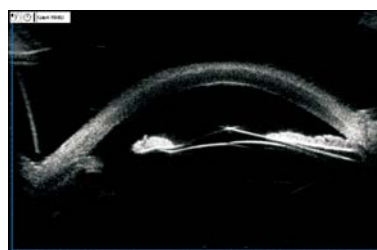


Figure 3 Ultrasound biomicroscopy showing that the TICL was still behind the iris, but the edges of the TICL arched forward into the anterior chamber TICL: Toric implantable collamer lens.

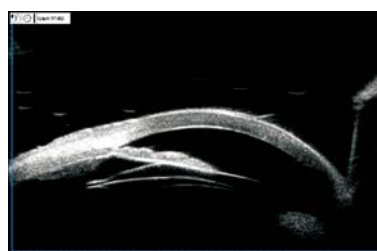


Figure 4 Ultrasound biomicroscopy showing a posteriorly positioned ciliary body, a short and small ciliary process and a shallow ciliary sulcus.

endothelium touch is easy to understand, but for the present case, it's strange and rare because the TICL remained behind the iris without visual endothelium touch. The patient presented with a shallow anterior chamber (2.80 mm for the right eye), and in UBM images, we found the edge of the TICL arched forward into the anterior chamber. Hence, we assume that in dark environment, when the pupil dilated, the TICL may get a chance to touch the corneal endothelium and cause damage, especially when the patient rubbed the eye or sleep with a prone position. The symptoms might be slight and was ignored by the patient, but the damage accumulated, and finally resulted in corneal endothelial decompensation.

Table 1 Review of cases of ICL dislocation

Case	Age/gender/eye	Mechanism	Time after implantation	Description of dislocation	Associated findings	Initial VA	Treatment	Post VA	Endothelial failure
Kaufer <i>et al</i> ^[4] 2005	30y/M right eye	Spontaneous	5y	2 inferior footplates subluxed through ruptured zonules, ICL still in the posterior chamber	Ruptured zonules in the inferior area	CF	Explantation	Not reported	Not mentioned
Song <i>et al</i> ^[10] 2005	33y/F/left eye	Blunt ocular trauma	10mo	1 footplate of the ICL entered the AC with pupillary capture	cells in AC and fracture of medial orbital wall	Not reported	Reposition	20/32	No endothelial touch
Kong <i>et al</i> ^[5] 2010	31y/M/right eye	Severe occipital injury in dark room	4mo	1 footplate of the ICL entered the AC with pupillary capture	None	20/200	Reposition	20/20	No endothelial touch
Schmitz <i>et al</i> ^[6] 2012	26y/M/left eye	Fist	6mo	2 temporal footplates of the ICL entered the AC with pupillary capture	Cells in AC and notching in pupillary	20/30	Reposition	20/20	No endothelial touch
Espinosa-Mattar <i>et al</i> ^[3] 2012	39y/F/right eye	Unspecified blunt ocular trauma	6y	1 footplate of the ICL entered the AC with pupillary capture	Elevated IOP to 30 mm Hg	20/60	Reposition	20/40	Significant endothelial touch. Eventually required DSAEK
Moshirfar <i>et al</i> ^[9] 2014	44y/M/left eye	Struck by a pipe	4y	Dislocation of superotemporal haptic into the AC which caused peaking of the pupil	Red blood cells in the AC with a blood clot	HM	Reposition	20/20	No endothelial touch
Wang <i>et al</i> ^[8] 2019	26y/M/left eye	Pupil dilation and cycloplegia induced after oral antidepressants	10mo	Partial dislocation of the ICL into the AC with pupillary capture	None	16/20	Reposition	16/20	Not mentioned
Takagi <i>et al</i> ^[7] 2019	39y/M/twice in the right eye	Struck by hand during a futsal match	11mo	The superotemporal and inferotemporal haptics had prolapsed into the AC	Mild inflammation	20/13	Reposition	20/13	No endothelial touch
		Struck by foot during a futsal match	2y and 2mo	The inferonasal haptic had prolapsed into the AC	Mild inflammation	20/17		20/10	No endothelial touch

VA: Visual acuity; CF: Counting fingers; AC: Anterior chamber; IOP: Intraocular pressure; DSAEK: Descemet's stripping endothelial keratoplasty; HM: Hand motion; ICL: Implantable collamer lens; F: Female; M: Male.

This unique case demonstrates the potential association of dislocation of ICLs with the ciliary body morphology and zonular weakness. And corneal decompensation may develop under rare conditions even though the ICL still remains behind the iris. Early reposition or explantation of dislocated ICLs is necessary to avoid further complications. UBM images should be carefully examined in the preoperative assessment of ICL implantation to detect morphological abnormalities. Surgeons should pay special attention to hypermyopia patients with zonular weakness and those with unstable ICL position intraoperatively and postoperatively. Patient education and routine follow-up examination are also of vital importance, because ignorance of the ocular symptoms may result in severe consequences.

ACKNOWLEDGEMENTS

Authors' contributions: Zhang L, Wang L conceived the idea for the case study and followed the patient. Zhang L, Li YX, Lei CY wrote the article and Wang L and Zhang MX revised it critically for important intellectual content. All authors read and approved the final manuscript.

Foundation: Supported by 1.3.5 project for disciplines of excellence, West China Hospital, Sichuan University (No. ZYJC21025).

Conflicts of Interest: Zhang L, None; Li YX, None; Lei CY, None; Wang L, None; Zhang MX, None.

REFERENCES

- 1 Packer M. The implantable collamer lens with a central port: review of the literature. *Clin Ophthalmol* 2018;12:2427-2438.
- 2 United States Food and Drug Administration clinical trial of the implantable collamer lens (ICL) for moderate to high myopia. *Ophthalmology* 2004;111(9):1683-1692.
- 3 Espinosa-Mattar Z, Gomez-Bastar A, Graue-Hernández EO, Navas A. DSAEK for implantable collamer lens dislocation and corneal decompensation 6 years after implantation. *Ophthalmic Surg Lasers Imaging* 2012;43 Online: e68-e72.
- 4 Kaufer RA, Kaufer GJ. Late subluxation of an ICL. *J Cataract Refract Surg* 2005;31(6):1254-1255.
- 5 Kong J, Qin XJ, Li XY, Zhang JS, Qu B. Implantable collamer lens dislocation. *Ophthalmology* 2010;117(2):399.e1.
- 6 Schmitz JW, McEwan GC, Hofmeister EM. Delayed presentation of traumatic dislocation of a Visian Implantable Collamer Lens. *J Refract Surg* 2012;28(5):365-367.
- 7 Takagi Y, Nakamura T, Ichikawa K, Kojima T. Recurrent prolapse of toric implantable collamer lens after blunt ocular trauma under mesopic conditions. *Clin Case Rep* 2019;7(4):626-629.
- 8 Wang R, Fu MJ, Savini G, Zhao JJ, Zhang HR. Pupillary capture of

- implantable collamer lens after oral antidepressants. *Digit J Ophthalmol* 2019;25(4):65-67.
- 9 Moshirfar M, Stagg BC, Muthappan V, Vasavada SA. Traumatic dislocation of implanted collamer phakic lens: a case report and review of the literature. *Open Ophthalmol J* 2014;8:24-26.
- 10 Song JS, Moon HS, Shyn KH. Pupillary capture of implantable contact lens after blunt trauma. *J Cataract Refract Surg* 2005;31(9):1831-1833.
- 11 Shi M, Kong J, Li X, Yan Q, Zhang J. Observing implantable collamer lens dislocation by panoramic ultrasound biomicroscopy. *Eye (Lond)* 2015;29(4):499-504.
- 12 Chen Q, Zeng QY, Wang Z, Pan C, Lei XH, Tan WN. Spontaneous rotation of a toric implantable collamer lens related to abnormal ciliary body morphology: a case report. *BMC Ophthalmol* 2020; 20(1):350.