

Volumetric fluid analysis of fixed monthly anti-VEGF treatment in patients with neovascular age-related macular degeneration

Bo Hee Kim¹, In Boem Chang², Hyeong Gon Yu^{3,4}, In Hwan Hong⁵

¹Department of Ophthalmology, Kangbuk Samsung Hospital, Sungkyunkwan University School of Medicine, Seoul 03181, Republic of Korea

²Seoul On Eye Clinic, Seoul 03355, Republic of Korea

³Department of Ophthalmology, Seoul National University College of Medicine, Seoul National University Hospital, Seoul 03080, Republic of Korea

⁴Retina Center, Sky Eye Institute, Seoul 06536, Republic of Korea

⁵Department of Ophthalmology, Dongtan Sacred Heart Hospital, Hallym University Medical Center, Hwaseong-si, Gyeonggi-do 18450, Republic of Korea

Correspondence to: In Hwan Hong, Department of Ophthalmology, Dongtan Sacred Heart Hospital, Hallym University Medical Center, Hwaseong-si, Gyeonggi-do 18450, Republic of Korea. loperter@hanmail.net

Received: 2022-11-07 Accepted: 2023-04-17

Abstract

• **AIM:** To evaluate visual outcomes and changes in fluid after administering monthly anti-vascular endothelial growth factor (VEGF) injections to treat neovascular age-related macular degeneration (nAMD) with subretinal fluid (SRF) and pigment epithelial detachment (PED).

• **METHODS:** This prospective study included eyes with nAMD previously treated with as-needed anti-VEGF injections. The patients were treated with six monthly intravitreal injections of ranibizumab. Quantitative volumetric segmentation analyses of the SRF and PED were performed. The main outcome measures included best-corrected visual acuity (BCVA), and SRF and PED volumes.

• **RESULTS:** Twenty eyes of 20 patients were included in this study. At the 6-month follow-up, BCVA and PED volume did not change significantly ($P=0.110$ and 0.999 , respectively) but the mean SRF volume decreased from 0.53 ± 0.82 mm³ at baseline to 0.08 ± 0.23 mm³ ($P=0.002$). The absorption rate of the SRF volume was negatively correlated with the duration of previous anti-VEGF treatment ($P=0.029$). Seven of the 20 eyes (35%)

showed a fluid-free macula and significant improvement in BCVA ($P=0.036$) by month 6.

• **CONCLUSION:** Quantifying the SRF can precisely determine the patient's responsiveness to anti-VEGF treatment of nAMD.

• **KEYWORDS:** neovascular age-related macular degeneration; anti-vascular endothelial growth factor treatment; drug tolerance; persistent subretinal fluid; volumetric fluid analysis

DOI:10.18240/ijo.2023.06.12

Citation: Kim BH, Chang IB, Yu HG, Hong IH. Volumetric fluid analysis of fixed monthly anti-VEGF treatment in patients with neovascular age-related macular degeneration. *Int J Ophthalmol* 2023;16(6):909-914

INTRODUCTION

Neovascular age-related macular degeneration (nAMD) is a degenerative retinal disorder that severely deteriorates visual function and can result in legal blindness if left untreated^[1]. The standard-of-care treatment for managing nAMD is the intravitreal injection of antibodies against vascular endothelial growth factor (VEGF)^[2]. Although the prognosis of nAMD has dramatically improved with the advent of anti-VEGF treatments, the long-term, repeated use of anti-VEGF agents has been associated with diminished effectiveness^[1,3].

The exudative activity of nAMD results in alterations in the retinal morphology and compromises the vision of the patients. The retinal fluid has served as an index of nAMD activity and has been used as a criterion for retreatment in patients receiving as-needed anti-VEGF regimens^[4-9]. Persistent or residual fluid after anti-VEGF therapy is generally regarded as a critical biomarker of insufficient treatment response. When an anti-VEGF agent is determined to be ineffective in treating an eye with nAMD, several strategies are considered. These include switching the patient to another anti-VEGF agent, increasing the dose and/or frequency of the anti-VEGF injections^[10-12], or combining anti-VEGF agents with

other treatment strategies such as corticosteroid injections or photodynamic therapy^[7,13-14].

Therefore, determining the anti-VEGF treatment response is pivotal in managing patients with nAMD. The conventional assessment of the response to anti-VEGF therapy is based on whether a fluid-free macula is achieved or not. Although this is easy to perform in a clinical situation, it does not reflect the precise change in fluid amount. We hypothesized that determining a patient's response using a quantitative estimation of the exact subretinal fluid (SRF) volume change may be more useful, especially in patients with nAMD who are experiencing diminished treatment effectiveness owing to the long-term, repeated use of anti-VEGF agents. Therefore, we conducted a prospective study using quantitative volumetric analyses based on spectral domain optical coherence tomography (SD-OCT) images to investigate visual and anatomical outcomes in patients after administering monthly intravitreal ranibizumab injections as a treatment for nAMD with SRF and pigment epithelial detachment (PED) despite previous anti-VEGF treatments.

SUBJECTS AND METHODS

Ethical Approval In this prospective interventional case series, patients were recruited from Seoul National University Hospital between March and August of 2016. The study protocol followed the tenets of the Declaration of Helsinki and was approved by the Institutional Review Board of Seoul National University Hospital (IRB No.1512-107-728). Fully informed written consent was obtained from all participants before enrollment.

Inclusion and Exclusion Criteria The inclusion criteria for the study were as follows: age >50y; known choroidal neovascularization (CNV) secondary to AMD, as demonstrated by fluorescein angiography and fibrovascular PED on SD-OCT images; Patients receiving anti-VEGF treatment according to the *pro re nata* (PRN) regimen; recurrence of CNV activity as evidenced by the reappearance of SRF on SD-OCT images; and a best-corrected visual acuity (BCVA) of 35 to 70 Early Treatment Diabetic Retinopathy Study (ETDRS) chart letters (equivalent to a Snellen acuity of 20/200–20/40).

The major exclusion criteria were as follows: history of vitrectomy; history of photodynamic treatment and/or photocoagulation in the macular region; presence of maculopathy other than typical nAMD (macular hole, vitreomacular traction, epiretinal membrane, retinal detachment, and pseudovitelliform macular dystrophy); history of systemic or ocular corticosteroid treatment; and presence of active intraocular inflammation or systemic infection.

Baseline Evaluations, Treatment, and Follow-up Evaluations At the time of enrollment, all patients underwent complete ophthalmic examinations, including BCVA measurements

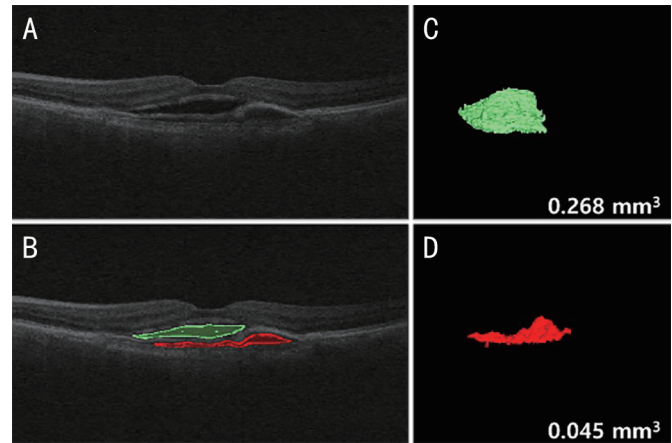


Figure 1 Manual segmentation of SRF and PED to determine the volume using the Iowa Reference Algorithm^[16] A: Raw scan image; B: Boundaries of SRF and PED are manually delineated, as shown in green and red lines, respectively; C, D: Three-dimensional visualization of SRF and PED, with the calculated SRF and PED volumes. SRF: Subretinal fluid; PED: Pigment epithelial detachment.

using the ETDRS chart, slit-lamp biomicroscopy, SD-OCT (Cirrus HD-OCT, Carl Zeiss Meditec, Dublin, CA, USA), fluorescein angiography, and indocyanine green angiography. The treatment for all patients was fixed-dose monthly intravitreal ranibizumab injections for 6mo. After the baseline intravitreal ranibizumab injection (month 0), the patients received five sequential injections at monthly follow-up visits. At each follow-up visit, each patient underwent funduscopy and SD-OCT examinations. The treatment efficacy was assessed at the final follow-up visit conducted 1mo after the sixth injection (month 6).

The protocol for imaging eyes using the SD-OCT includes a raster scan of 200×200 macular cube scans covering a 6×6-mm² area centered on the fovea^[15]. The operator assessed the quality of the scan during image acquisition. Using automated software contained within the OCT machine, the distance between the inner border of the retinal pigment epithelium and the inner surface of the retina at the central fovea were calculated as the central macular thickness (CMT).

Measurements of Volume of Subretinal Fluid and Pigment Epithelial Detachment After being exported from the Cirrus OCT device, image data were imported to the software. Two graders (Kim BH and Chang IB) drew the boundaries of the SRF and PED on the B-scan images. After the boundaries were drawn, the Iowa Reference Algorithm (version 4.0; available in the public domain from <https://www.iibi.uiowa.edu/content/iowa-reference-algorithms-human-and-murine-oct-retinal-layer-analysis-and-display>)^[16] was used to calculate the SRF and PED volumes (Figure 1). To achieve independent data, the graders were also blinded to the patient's identity and specific time of the visit.

Quantitative Determination of the Anti-VEGF Treatment Response

Responsiveness to the monthly anti-VEGF treatments was determined according to the overall trend in the SRF volume change for individual patients. Complete responders were patients who experienced complete absorption of the SRF by month 6. If a patient still exhibited SRF at month 6, the base ten logarithm of the SRF volume at each monthly visit was calculated and linear regression with logarithmic transformation of the SRF volume to the time point was performed. If the slope of the regression was significant and negative, the patient was designated as an incomplete responder. If the slope of the regression was not significant or was positive, the patient was designated as a non-responder.

Statistical Analysis The linear mixed model analyses and post-hoc tests, if needed, were conducted to assess the mean structural changes in SRF volume, PED volume, CMT, and BCVA. A univariate regression analysis was performed to identify the baseline factors that may affect the speed of SRF volume absorption. The level of statistical significance was set at $P < 0.05$. All statistical analyses were performed using R^[17] packages *nlme*^[18] and *multcomp*^[19].

RESULTS

At baseline, 22 patients were enrolled, but two patients were dropped out due to follow-up loss during the study period. Thus, 20 patients (20 eyes) completed the six monthly intravitreal injections of ranibizumab and the follow-up visit at month 6. The patients' baseline characteristics are presented in Table 1. The average duration of the previous anti-VEGF treatment course was 37.0 ± 11.9 mo. The mean number of anti-VEGF injections received before enrollment was 14.8 ± 6.1 . Before enrollment in the present study, the affected eyes had received a total of 297 anti-VEGF injections, which included 169 ranibizumab (57.0%), 38 aflibercept (12.8%), and 90 bevacizumab (30.3%) injections.

The BCVA and structural changes are summarized in Figure 2. At baseline (month 0), the mean BCVA was 52 ± 13 ETDRS letters, which improved to 56 ± 17 letters at month 6, although the change was not significant ($P = 0.110$). All patients showed SRF and PED on the OCT images at baseline (month 0). The mean SRF volume and mean CMT decreased significantly during the 6-month study period (from 0.53 ± 0.82 mm³ to 0.08 ± 0.23 mm³, $P = 0.002$ and from 332 ± 74 μm to 253 ± 51 μm, $P < 0.001$, respectively, linear mixed model). Post-hoc analyses revealed that the decreases in both the SRF volume and CMT were significant after month 3 compared to the baseline values. On the contrary, the mean PED volume did not change during the study period (from 0.14 ± 0.15 to 0.13 ± 0.22 , $P = 0.999$). No treatment-related adverse events were observed in this study.

The SRF was absorbed completely in seven (35%) eyes by month 6 (complete responders). In these patients, BCVA

Table 1 Baseline characteristics of patients with neovascular age-related macular degeneration with persistent subretinal fluid and pigment epithelial detachment

Parameters	n=20
Age, y	70.3±8.05
Female, n (%)	9 (45.0)
Left eye, n (%)	9 (45.0)
BCVA, ETDRS letters	51.9±12.8
Central macular thickness, μm	332±74
Total number of previous anti-VEGF injections, n	14.8±6.1
Duration of previous anti-VEGF treatment, mo	37.0±11.9

BCVA: Best-corrected visual acuity; ETDRS: Early Treatment Diabetic Retinopathy Study scale for visual acuity; VEGF: Vascular endothelial growth factor.

was significantly improved from 55 ± 11 to 62 ± 12 letters at month 6 ($P = 0.036$, Wilcoxon signed-rank test). In another six (30%) eyes, SRF remained but slowly decreased during the study period (incomplete responders). BCVA did not change significantly in this group (from 46 ± 19 to 48 ± 28 letters; $P = 0.916$, Wilcoxon signed-rank test). In the remaining seven (35%) eyes (non-responders), the SRF volume either did not change (six eyes) or increased (one eye) and BCVA remain unchanged (from 54 ± 9 to 58 ± 6 letters; $P = 0.419$, Wilcoxon signed-rank test)

Table 2 shows the results of the regression analysis for the speed of SRF volume absorption. Among the various baseline variables, the duration of previous anti-VEGF treatment was significantly related to the SRF volume change rate ($P = 0.029$).

DISCUSSION

The findings of the present study show that administering monthly injections of ranibizumab to patients with nAMD for 6-month results in improved anatomical outcomes in selected cases. The absorption rate of the SRF volume was faster in patients with shorter durations of previous anti-VEGF treatment. Moreover, our findings imply that quantitative SRF volume evaluations can affect the management strategy for patients with nAMD; for instance, here, we found that six eyes with residual SRF showed slow, but steady, decreases in SRF volume, which meant these patients may benefit from extended continuous anti-VEGF injections.

The development of drug tolerance owing to repetitive treatment with anti-VEGF agents has previously been found to reduce treatment efficacy^[20]. Several mechanisms may underlie the decreased drug response in patients with nAMD, including pharmacokinetic tolerance, for instance *via* the development of neutralizing antibodies for anti-VEGF agents, and pharmacodynamic tolerance, such as through alterations in the neovascular membrane and vessel walls, the increased expression of VEGF or VEGF receptors, alterations in

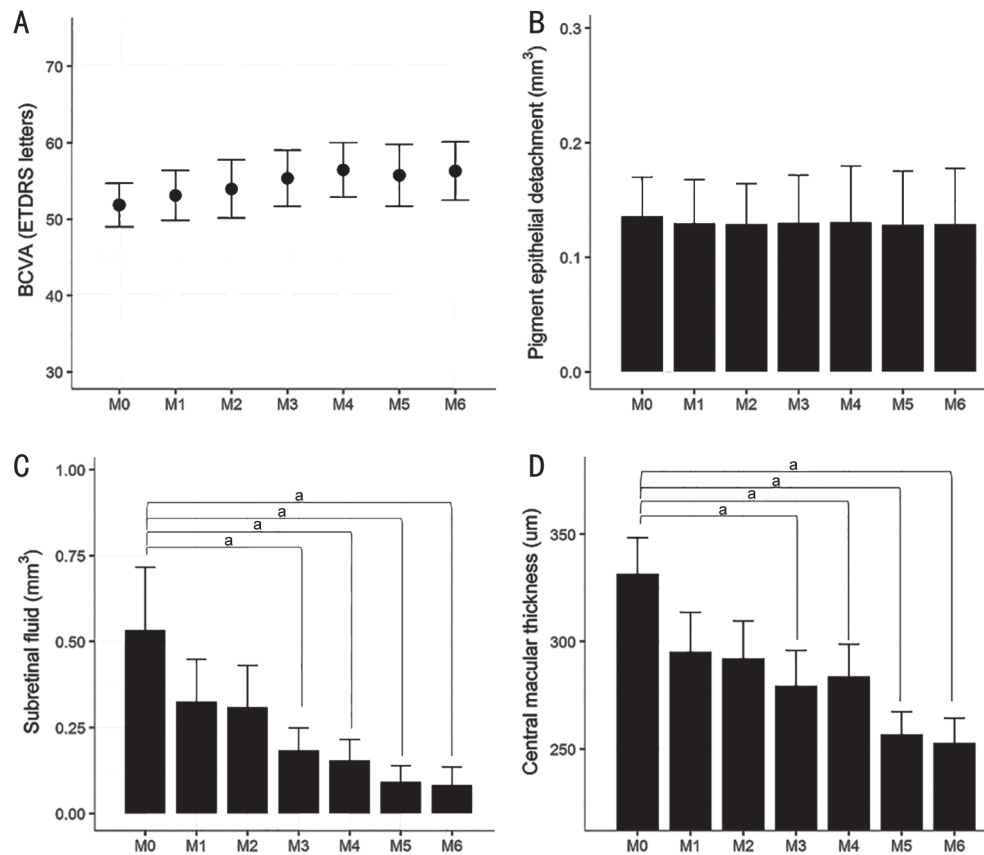


Figure 2 Mean changes in best-corrected visual acuity (BCVA, ETDRS letters; A), pigment epithelial detachment (PED) volume (B), subretinal fluid (SRF) volume (C) and central macular thickness (CMT; D) during the 6-month period of monthly ranibizumab injections in patients with neovascular age-related macular degeneration with persistent fluid. The changes in the SRF and CMT were significant (linear mixed model, $P=0.002$ and $P<0.001$, respectively). ETDRS: Early Treatment Diabetic Retinopathy Study scale for visual acuity; M0: Baseline; M1: Month 1; M2: Month 2; M3: Month 3; M4: Month 4; M5: Month 5; M6: Month 6. ^a $P<0.05$; error bars represent the standard error.

Table 2 Factors affecting the speed of subretinal fluid volume changes in patients with neovascular age-related macular degeneration

Factors	β	95%CI	P
Age, per 1 year older	0.009	(-0.004, 0.021)	0.198
Female sex	-0.125	(-0.327, 0.076)	0.239
Previous anti-VEGF injections, per 1 injection	-0.010	(-0.027, 0.007)	0.255
Duration of previous anti-VEGF therapy, per 1mo	-0.010	(-0.017, -0.002)	0.029 ^a
Baseline BCVA, per 1 ETDRS letter	0.001	(-0.007, 0.009)	0.804
Baseline central retinal thickness, per 1 μm thicker	0.000	(-0.002, 0.001)	0.760
Baseline subretinal fluid, per 1 mm^3 larger	0.092	(-0.032, 0.215)	0.164
Baseline pigment epithelial detachment, per 1 mm^3 larger	0.597	(-0.052, 1.246)	0.088

CI: Confidence interval; VEGF: Vascular endothelial growth factor; BCVA: Best-corrected visual acuity; ETDRS: Early Treatment Diabetic Retinopathy Study scale for visual acuity. ^a $P<0.05$.

signal transduction, and/or the involvement of other growth factors that stimulate CNV growth^[21]. In our study, patients likely exhibited drug tolerance-induced decreases in anti-VEGF efficacy, because all patients demonstrated the fluid-free macula after the first three monthly injections, but some exhibited persistent SRF after repetitive anti-VEGF treatments. There is no authoritative consensus on how to define the responsiveness to anti-VEGF agents in nAMD patients. Clinically, a patient's responsiveness is estimated based on

whether the fluid-free macula is achieved after three to six anti-VEGF treatments and if there is less or no effect after this numbers of injections, it is generally considered as refractory nAMD^[4-5]. However, although easy to perform, this estimation method may not fully reflect the patient's actual anti-VEGF response. For instance, even if the macula is not completely fluid-free at the end of the treatment period, the patient's nAMD may be slowly improving (Figure 3). Our study showed that, among the 13 eyes with persistent fluid at month

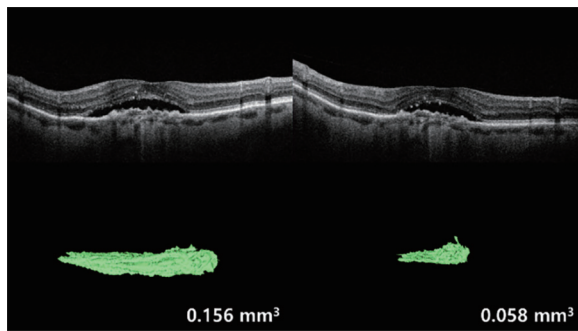


Figure 3 Representative example showing the usefulness of quantitative assessment of subretinal fluid (SRF) volume in evaluating the response to anti-VEGF treatment A 73-year-old man with neovascular age-related macular degeneration (nAMD) was treated with monthly intravitreal anti-VEGF injections. After three injections, the raster image of spectral domain-optical coherence tomography revealed persistent SRF. The change in SRF height after 3mo was not prominent. This patient may have been considered to have refractory nAMD if conventional qualitative methods, which are based on whether the macula is fluid-free after three anti-VEGF injections, were applied. However, evaluation of SRF volume by manual segmentation revealed a slow reduction in this measure. After three more anti-VEGF injections, the SRF was completely absorbed.

6, six eyes (46.2%) exhibited significant decreases in SRF volume during the 6-month study period. These patients would be considered to have refractory nAMD if the conventional qualitative method was applied since their SRF remained after six consecutive anti-VEGF injections. However, these patients likely still have an anti-VEGF response because their SRF volume significantly decreased over the 6-month period, and thus, the patients may still benefit from extended monthly fixed anti-VEGF injections. Hence, quantitative methods of determining a patient's anti-VEGF response, such as with the volumetric segmentation analyses employed herein, may be more useful than the current qualitative method.

Similar to the findings in previous studies^[22-23], the PED did not show any significant changes in the present study. However, it should be noted that our sample size was relatively small, and thus we cannot fully determine the changes in PED volume that occurred after six monthly anti-VEGF injections in patients with nAMD with SRF and PED.

Our regression analysis suggested that the SRF volume change rate was negatively related to the duration of previous anti-VEGF treatment. This finding can be interpreted as indicating that prolonged treatment with the anti-VEGF agent can yield drug tolerance as we mentioned above, leading to a decreased SRF absorption rate in patients with nAMD.

Several limitations of this study must be considered. First, our follow-up duration was short, and thus our results only reflect the short-term outcomes of the evaluated fixed-dose regimen.

Other limitations of this study include the small sample size and absence of a comparison group. Furthermore, we demonstrated successful outcomes with a single anti-VEGF agent, and as such, it remains unclear whether switching to another anti-VEGF agent may have yielded similar or better outcomes. Although our results are encouraging, a larger randomized controlled trial with a longer follow-up period is necessary to determine if this treatment regimen is indeed beneficial for this subset of patients.

Although our study was limited by the small number of patients and inconsistency in past injection history, retrospective analyses have shown that clinicians ordered diagnostic tests less frequently in real-world settings and underutilization of anti-VEGF agents was prevalent^[12,24-25]. In regular anti-VEGF therapy for long-standing nAMD, persistence or recurrence of neovascular activity is common, prompting clinicians to switch agents to potentially increase efficacy^[12]. However, the optimal timing of these transitions remains unclear. Thus, accurate classification and definition of therapeutic responses are crucial in clinical decision-making for switching between anti-VEGF regimens and evaluating treatment effects. Our study addresses this need by examining commonly encountered nAMD patients in the real-world clinic setting and demonstrating that volumetric quantitative measurements can provide valuable insight into the response of different retinal compartments, aiding in the classification and definition of therapeutic response to various anti-VEGF treatments.

In conclusion, the findings from our study support that monthly anti-VEGF injections decrease the SRF volume and maintain vision in patients with nAMD with SRF and PED. One-third of nAMD patients who previously received anti-VEGF treatment as PRN regimen achieved a fluid-free macula after 6 monthly anti-VEGF injections, which was also associated with visual improvement. In addition, half of the patients who still exhibited SRF at month 6 showed slow but steady decreases in the SRF volume over the 6-month study period, which suggests that some patients with nAMD who have a recurrence of CNV activity can still benefit from monthly intravitreal anti-VEGF treatments. Importantly, our study indicates that precisely quantifying the SRF volume may be a useful approach for determining a patient's responsiveness to anti-VEGF therapy.

ACKNOWLEDGEMENTS

Authors' contributions: Kim BH, Yu HG, and Hong IH designed and conducted the study. Kim BH and Chang IB collected the data. Hong IH managed, analyzed, and interpreted the data. Kim BH, Chang IB, Yu HG, and Hong IH prepared, reviewed, and approved the manuscript.

Conflicts of Interest: Kim BH, None; Chang IB, None; Yu HG, None; Hong IH, None.

REFERENCES

- 1 Patel P, Sheth V. New and innovative treatments for neovascular age-related macular degeneration (nAMD). *J Clin Med* 2021;10(11):2436.
- 2 Wykoff CC, Clark WL, Nielsen JS, Brill JV, Greene LS, Heggen CL. Optimizing anti-VEGF treatment outcomes for patients with neovascular age-related macular degeneration. *J Manag Care Spec Pharm* 2018;24(2-a Suppl):S3-S15.
- 3 Honda S, Yanagi Y, Koizumi H, Chen YR, Tanaka S, Arimoto M, Imai K. Impact of neovascular age-related macular degeneration: burden of patients receiving therapies in Japan. *Sci Rep* 2021;11(1):13152.
- 4 Brown DM, Chen E, Mariani A, Major JC Jr, Study Group Jr S. Super-dose anti-VEGF (SAVE) trial: 2.0 mg intravitreal ranibizumab for recalcitrant neovascular macular degeneration-primary end point. *Ophthalmology* 2013;120(2):349-354.
- 5 Stewart MW, Rosenfeld PJ, Penha FM, Wang FH, Yehoshua Z, Bueno-Lopez E, Lopez PF. Pharmacokinetic rationale for dosing every 2 weeks versus 4 weeks with intravitreal ranibizumab, bevacizumab, and aflibercept (vascular endothelial growth factor Trap-eye). *Retina* 2012;32(3):434-457.
- 6 Marquis LM, Mantel I. Beneficial switch from aflibercept to ranibizumab for the treatment of refractory neovascular age-related macular degeneration. *Graefes Arch Clin Exp Ophthalmol* 2020;258(8):1591-1596.
- 7 Yoshida M, Oishi A, Miyake M, Ooto S, Tamura H, Miyata M, Takahashi A, Hata M, Yamashiro K, Tsujikawa A. Rescue photodynamic therapy for age-related macular degeneration refractory to anti-vascular endothelial growth factor monotherapy. *Photodiagnosis Photodyn Ther* 2022;38:102745.
- 8 Glasser DB, Parikh R, Lum F, Williams GA. Intravitreal anti-vascular endothelial growth factor cost savings achievable with increased bevacizumab reimbursement and use. *Ophthalmology* 2020;127(12):1688-1692.
- 9 Razavi S, Kodjikian L, Giocanti-Aurégan A, Dufour I, Souied E. Efficacy and safety of intravitreal aflibercept in ranibizumab-refractory patients with neovascular age-related macular degeneration. *BMC Ophthalmol* 2021;21(1):90.
- 10 Mantel I, Gillies MC, Souied EH. Switching between ranibizumab and aflibercept for the treatment of neovascular age-related macular degeneration. *Surv Ophthalmol* 2018;63(5):638-645.
- 11 Mimouni M, Meshi A, Vainer I, Gershoni A, Koren T, Geffen N, Nemet AY, Segal O. Bevacizumab dosing every 2 weeks for neovascular age-related macular degeneration refractory to monthly dosing. *Jpn J Ophthalmol* 2018;62(6):652-658.
- 12 Queguiner F, Bezirganyan K, Courjaret JC, Curel L, Penaranda G, Righini Chossegros M. Impact of switching from ranibizumab to aflibercept on the number of intravitreal injection and follow up visit in wet AMD: results of real life ELU study. *Int J Ophthalmol* 2020;13(2):252-256.
- 13 Empelesidis T, Storey M, Giannopoulos T, Konidaris V, Tranos PG, Panagiotou ES, Voudouragkaki IC, Konstas AG. How successful is switching from bevacizumab or ranibizumab to aflibercept in age-related macular degeneration? A systematic overview. *Adv Ther* 2019;36(7):1532-1548.
- 14 Barthelmes D, Campain A, Nguyen P, Arnold JJ, McAllister IL, Simpson JM, Hunyor AP, Guymer R, Essex RW, Morlet N, Gillies MC. Effects of switching from ranibizumab to aflibercept in eyes with exudative age-related macular degeneration. *Br J Ophthalmol* 2016;100(12):1640-1645.
- 15 Ahlers C, Golbaz I, Stock G, Fous A, Kolar S, Prunte C, Schmidt-Erfurth U. Time course of morphologic effects on different retinal compartments after ranibizumab therapy in age-related macular degeneration. *Ophthalmology* 2008;115(8):e39-e46.
- 16 Chen XJ, Niemeijer M, Zhang L, Lee K, Abramoff MD, Sonka M. Three-dimensional segmentation of fluid-associated abnormalities in retinal OCT: probability constrained graph-search-graph-cut. *IEEE Trans Med Imaging* 2012;31(8):1521-1531.
- 17 R Core Team. R: a language and environment for statistical computing. 2018. <https://www.R-project.org/>
- 18 Pinheiro J, Bates D, R Core Team. nlme: linear and nonlinear mixed effects models. 2018. <https://CRAN.R-project.org/package=nlme>
- 19 Hothorn T, Bretz F, Westfall P. Simultaneous inference in general parametric models. *Biom J* 2008;50(3):346-363.
- 20 Keane PA, Liakopoulos S, Ongchin SC, Heussen FM, Msutta S, Chang KT, Walsh AC, Sadda SR. Quantitative subanalysis of optical coherence tomography after treatment with ranibizumab for neovascular age-related macular degeneration. *Invest Ophthalmol Vis Sci* 2008;49(7):3115-3120.
- 21 Schaal S, Kaplan HJ, Tezel TH. Is there tachyphylaxis to intravitreal anti-vascular endothelial growth factor pharmacotherapy in age-related macular degeneration? *Ophthalmology* 2008;115(12):2199-2205.
- 22 Binder S. Loss of reactivity in intravitreal anti-VEGF therapy: tachyphylaxis or tolerance? *Br J Ophthalmol* 2012;96(1):1-2.
- 23 Gasperini JL, Fawzi AA, Khondkaryan A, Lam L, Chong LP, Elliott D, Walsh AC, Hwang J, Sadda SR. Bevacizumab and ranibizumab tachyphylaxis in the treatment of choroidal neovascularisation. *Br J Ophthalmol* 2012;96(1):14-20.
- 24 Holekamp NM. Review of neovascular age-related macular degeneration treatment options. *Am J Manag Care* 2019;25(10 Suppl):S172-S181.
- 25 Baumal CR. Wet age-related macular degeneration: treatment advances to reduce the injection burden. *Am J Manag Care* 2020;26(5 Suppl):S103-S111.