

Technique of using Cionni-modified capsular tension ring in the management of severely traumatic lens subluxation

Hao Jiang, Wei Zhang, Yan-Hua Chu

Tianjin Eye Hospital, Tianjin Key Lab of Ophthalmology and Visual Science, Tianjin Eye Institute, Clinical College of Ophthalmology Tianjin Medical University, Tianjin 300020, China

Co-first authors: Hao Jiang and Wei Zhang

Correspondence to: Wei Zhang and Yan-Hua Chu. Tianjin Eye Hospital, Tianjin Key Lab of Ophthalmology and Visual Science, Tianjin Eye Institute, Clinical College of Ophthalmology Tianjin Medical University, Tianjin 300020, China. a285733453@sina.com; chuchutj@126.com

Received: 2023-01-09 Accepted: 2023-05-08

Abstract

• **AIM:** To investigate the effect of Cionni-modified capsular tension ring (CTR) implantation in patients with severely traumatic subluxated cataracts.

• **METHODS:** All patients who totally had traumatic cataracts and lost zonule support and underwent cataract surgery were retrospectively analyzed. Corrected distance visual acuity (CDVA), extent of zonulysis, intraocular lens (IOL) position, intraoperative presentation, and complications were assessed. The primary outcomes included IOL centration stability and other postoperative complications.

• **RESULTS:** Twenty patients (20 eyes) were included in this study. The mean age in this study was 58.0 ± 11.3 y, and the average follow-up time was 17.3 ± 12.8 mo. Capsule bags were saved by Cionni-modified CTR. Nine eyes (45%) underwent simultaneously anterior vitrectomy due to the presence of vitreous in the anterior chamber. The preoperative mean CDVA was 0.83 ± 0.24 logMAR, and the postoperative average CDVA was 0.23 ± 0.30 logMAR ($P < 0.05$). The horizontal and vertical IOL decentration after surgery was 0.27 ± 0.12 mm and 0.41 ± 0.19 mm, respectively; the vertical and horizontal IOL tilt after surgery was $5.5^\circ \pm 2.5^\circ$ and $6.1^\circ \pm 2.2^\circ$, respectively. None of the eyes had obvious IOL decentration during the follow-up time. Eight eyes (40%) had posterior capsule opacification (PCO) that was severe enough to cause poor vision. Neodymium: YAG laser capsulotomy were performed on these eyes when the CTR was stabilized.

• **CONCLUSION:** With the help of Cionni-modified CTR, capsular bag preservation and better IOL concentration can be achieved without major complications in patients with severely traumatic subluxated cataracts.

• **KEYWORDS:** Cionni-modified capsular tension ring; subluxated traumatic cataracts; surgical technique; intraocular lens decentration; intraocular lens tilt

DOI:10.18240/ijo.2023.07.12

Citation: Jiang H, Zhang W, Chu YH. Technique of using Cionni-modified capsular tension ring in the management of severely traumatic lens subluxation. *Int J Ophthalmol* 2023;16(7):1078-1083

INTRODUCTION

Subluxated lenses are a major challenge for cataract surgeons. Subluxated lenses can be congenital (e.g., Marfan syndrome and microspherophakia) or acquired (e.g., ocular trauma)^[1]. Severe zonular instability increases the risks of cataract extraction during and after surgery. Cionni and Osher^[2] proposed the concept of the capsular tension ring (CTR). The CTR can be used to treat mild zonulopathy^[3]. However, implantation of the CTR in eyes with greater zonular damage could not achieve sufficient stabilization and concentration of the intraocular lens (IOL) and the capsular bag.

In the case of traumatic lens subluxation, the degree of zonular destruction may be very severe and accompanied by the presence of vitreous in the anterior chamber (AC)^[4]. In addition, there could also be other problems that require additional treatment, such as traumatic mydriasis, increased intraocular pressure (IOP), and iridodialysis. When these conditions are present, it is often difficult to maintain and stabilize the capsular bag. Cionni *et al*^[5] developed a modified CTR (another name is Cionni-CTR) for cataract surgeries with significant zonular dialysis or compromise in eyes. The modified CTR is based on the traditional open-loop CTR, which has a fixation eyelet forward, thus enabling suture fixation of the modified CTR and IOL and capsular bag complex to the sclera^[6]. In our research, we reported the clinical characteristics and postoperative effects of patients with traumatic cataract and zonulopathy who underwent phacoemulsification and received a modified CTR and a posterior IOL.

SUBJECTS AND METHODS

Ethical Approval All patients were given appropriate written informed consent. This research followed the purpose of the Helsinki Declaration. This study was approved by the Medical Ethics Committees of Tianjin Eye Hospital (KY-2023011).

We retrospectively reviewed 20 eyes of 20 patients who had traumatic subluxated cataracts with at least 6-clock hours of zonular loss or weakness who underwent cataract surgery by one surgeon (Jiang H) at the Tianjin Eye Hospital from January 1, 2017, to September 1, 2020.

We examined corrected distance visual acuity (CDVA) by a Snellen chart and converted it to logMAR value. We used the SRK II formula to evaluate the degree of the IOL implanted with Cionni-modified CTR. The degree of zonular loss or weakness was intraoperatively evaluated based on the amount of displacement and mobility of the lens. We used a single-point fixed capsular tension device to treat zonulysis at 6-8 clock hours. We used a double-point fixed capsular tension device to treat zonulysis of 8-12 clock hours. The complications included IOL decentration, retinal detachment and posterior capsule rupture (PCR).

Biomicroscopic examination was used to calculate the preoperative lens decentration and tilt^[7]. The grades of lens tilt are shown: D = severe (>45 degrees); C = marked (31-45 degrees); B = moderate (16-30 degrees); A = mild (<15 degrees); N = none. The grades of lens decentration are shown: D = severe (lens and lens equator not seen through dilated pupil); C = marked (lens equator seen through dilated pupil with aphakic optical axis); B = moderate (lens equator seen through dilated pupil with phakic optical axis); A = mild (lens equator not seen through dilated pupil with phakic optical axis); N = none.

Ultrasound Biomicroscopy We performed ultrasound biomicroscopy (UBM) examination on all patients. Scans were performed with the undilated eye in the central position. The scan clip for each eye was recorded and selected for analysis. A scleral spur (SS) shows a hyperechoic area resembling an olecranon (elbow shape) in UBM images. We considered the line between the two olecranons as the baseline for the position of the IOL. Two perpendicular lines were drawn from the two optical endpoints of the IOL to the baseline, and the distance between the SS and intersection points was measured for analysis of IOL decentration. IOL decentration is equal to half the difference between these two distances (Figure 1). IOL tilt is assessed by the angle (θ) formed by the line between the baseline and the two optical endpoints (Figure 1).

Surgical Technique The same surgeon (Jiang H) performed all the surgeries under retrobulbar anesthesia. A 3.2-mm transparent corneal tunnel incision was made. a 0.9-mm-wide puncture was made to insert a chopper. Then, we

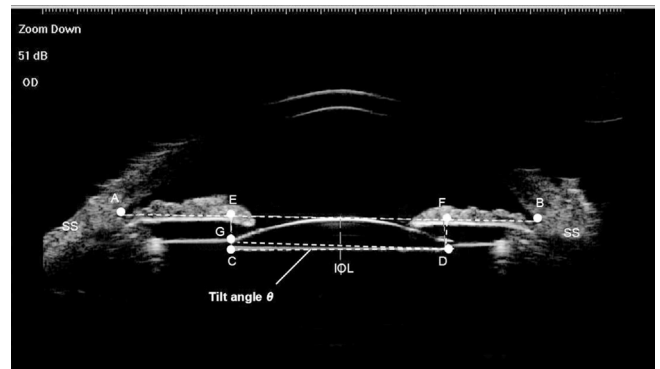


Figure 1 Measurement of intraocular lens (IOL) decentration and tilt on ultrasound biomicroscopy images of the anterior segment A line (line AB) was drawn between the two scleral spurs (SS) as the baseline for referencing the position of the IOL. Draw two vertical lines from the two optical end-points (C and D) of the IOL to the baseline with intersection points (E and F). The IOL decentration was equal to half of the difference between distances AE and FB. The IOL tilt was determined by the angle formed by the line between the two optical endpoints and the baseline. The tilt angle θ was calculated by the formula: $\theta = \arctan CG/DG = \arctan (CE-DF)$.

used Healon (Alcon Laboratory, USA) to maintain the AC. We used capsulorhexis forceps to make a 5.5-mm-wide central capsulorhexis. Then, we used a disposable pouch retractor to engage the capsulorhexis to center and stabilize the lens. Then, we performed hydrodissection. We used the phaco/chop technique and cortical aspiration by centurion phacoemulsification (Bausch & Lomb Inc. USA) to perform nuclear endocapsular phacoemulsification. We performed phacoemulsification at a low flow rate, and the infusion bottle height was 80 cm. The capsular bag and AC were filled with Healon. We implanted a foldable IOL into the capsular bag. Then, the Healon was removed behind the IOL by an I/A device.

According to the surgeon's assessment of zonal weakness during the operation, the type of modified CTR implantation was decided intraoperatively. When the loss or weakness of the zonules was less than 8 clock hours, a single-eyelet CTR was used. When it was 8 clock hours or more, a double-eyelet CTR was used. The 10-0 polypropylene suture was passed through the eyelets of Cionni-modified CTR. After that, the Cionni-modified CTR was passed into the capsular bag through the main incision by using a chopper and a tying forcep. The eyelet was located at the midpoint of the area of zonular dialysis anterior to the capsulorhexis. Then, we moved the suture needle under the scleral flap. We used central capsulorhexis to perfectly provide centration of the capsular bag by adjusting the suture and then sutured the Cionni-modified CTR to the sclera. After inflating the capsular bag with Healon, a foldable IOL was implanted into the capsular bag. Then, we used a biaxial I/A tip to remove the ophthalmic viscosurgical device.

Table 1 Preoperative and intraoperative characteristics

Case	Age/sex	Eye	Decentration	Phacodonesis	Vitreous in AC	Zonular weakness (clock hours)	Lens tilt	Surgery	CTR type
1	53/F	R	B	+	+	8	A	PE+CTR+AV	2-eyelet
2	75/F	R	A	-	-	3	N	PE+CTR	1-eyelet
3	63/M	R	A	+	+	7	A	PE+CTR+AV	1-eyelet
4	63/M	L	A	+	-	9	A	PE+CTR	2-eyelet
5	65/M	R	B	+	+	8	B	PE+CTR+AV	2-eyelet
6	64/F	R	C	+	+	9	B	PE+CTR+AV	2-eyelet
7	58/M	R	A	+	+	9	B	PE+CTR+AV	2-eyelet
8	71/M	L	B	+	+	7	A	PE+CTR+AV	1-eyelet
9	59/F	R	A	+	-	5	N	PE+CTR	2-eyelet
10	34/M	R	A	+	-	6	A	PE+CTR	1-eyelet
11	51/M	L	A	+	-	6	N	PE+CTR	1-eyelet
12	32/F	L	B	+	+	8	A	PE+CTR+AV	2-eyelet
13	52/F	R	A	-	-	6	N	PE+CTR	1-eyelet
14	63/M	R	A	+	-	6	N	PE+CTR	1-eyelet
15	53/M	R	B	+	-	7	A	PE+CTR	1-eyelet
16	70/M	R	A	+	-	7	A	PE+CTR	1-eyelet
17	69/M	R	A	+	+	7	N	PE+CTR+AV	1-eyelet
18	64/M	R	A	-	-	6	N	PE+CTR	1-eyelet
19	54/F	R	B	+	+	8	B	PE+CTR+AV	2-eyelet
20	47/F	L	B	+	-	7	A	PE+CTR	1-eyelet

AC: Anterior chamber; PE: Phacoemulsification; CTR: Modified-capsular tension ring; AV: Anterior vitrectomy.

Some ophthalmic viscosurgical devices remained above the zonular dehiscence area. All the incisions were hydrated to check the stability.

After the operation, patients were topically given 0.1% pranoprofen (Alcon Laboratory Inc. USA) and 0.1% tobradex (Alcon Laboratory Inc.) four times daily for 7d, and then the dose was gradually reduced every week.

Statistical Analysis The result is presented as the mean±standard deviation (SD). Snellen visual acuity was changed to the logarithm of the minimum angle of resolution (logMAR). The Shapiro-Wilk test was used to confirm the normality of data distribution. The Student's *t*-test and Mann-Whitney *U* test were used to analyze the parametric and non-parametric data, respectively. The differences were considered statistically significant at $P<0.05$.

RESULTS

The mean age of the patients was 58.0±11.3 (range 32 to 75) y in the study (Table 1). The mean duration of follow-up was 17.3±12.8 (range 6 to 48) mo. Eight patients received a double-eyelet CTR, and 12 patients received a single-eyelet CTR. The preoperative mean CDVA was 0.83±0.24 logMAR, and the postoperative average CDVA was 0.23±0.30 logMAR ($P<0.05$). Only 5 of the 20 eyes (25%) preoperatively had a CDVA of 20/80 or better compared with 18 eyes at the last visit (90%, $P<0.05$). The poor vision in the other 2 eyes at the last visit was due to posterior capsule opacification (PCO). At

the last visit, 16 eyes (80%) had a CDVA of 20/40 or higher. Ten patients were followed up for at least one year, and 7 eyes had a CDVA of 20/40 or higher (70%) during the year.

Preoperatively, 8 eyes (40%) developed symptomatic decentration (grades 2 and 3; Table 1). During the surgery, all 20 eyes had centered IOLs (Figure 2A, 2B). At the last visit, the postoperative horizontal and vertical IOL decentration was 0.27±0.12 mm and 0.41±0.19 mm, respectively. No symptomatic decentration occurred in the eyes during the entire follow-up ($P<0.05$; Table 2; Figure 2C, 2D). Preoperatively, 13 eyes (65%) had posterior lens tilt (Grade 1 or 2). At the last visit, the postoperative vertical and horizontal IOL tilts were 5.5°±2.5° and 6.1°±2.2°, respectively.

The preoperative examination revealed that 9 eyes (45%) of the AC had vitreous. Due to the presence of vitreous in the AC, 9 eyes (45%) required bimanual anterior vitrectomy. These nine eyes preoperatively had vitreous prolapse with at least 6 clock hours of zonulysis. There were no cases of vitreous in the AC after surgery. There was also no endophthalmitis or retinal detachment. Eight eyes (40%) had PCO that was severe enough to cause poor vision. We performed neodymium (Nd):YAG laser capsulotomy on these eyes when the CTR was stabilized.

DISCUSSION

Cataract surgery is difficult in traumatic eyes with zonular insufficiency or subluxation of the lens. Previously,

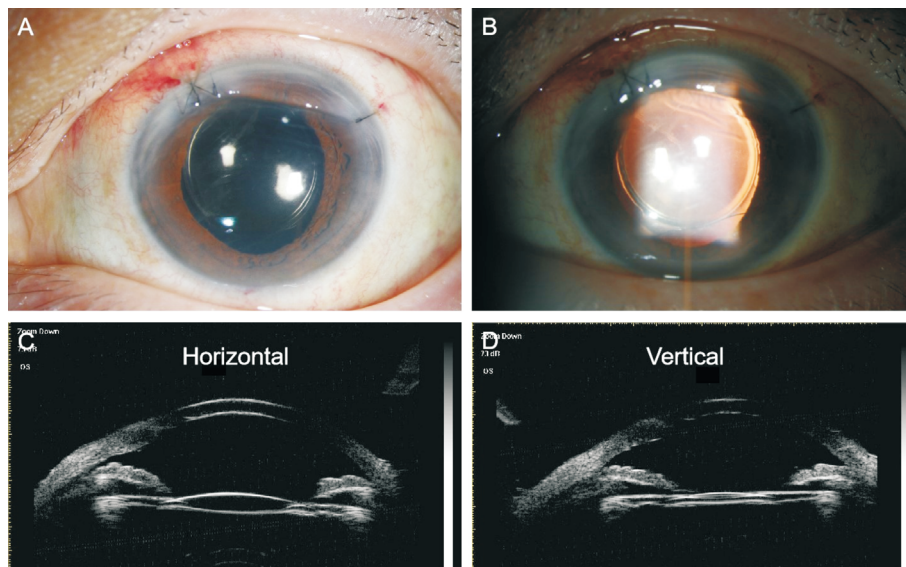


Figure 2 Representative anterior segment photography and ultrasound biomicroscopy photography A, B: Anterior segment photography illustrating the centered intraocular lens (IOL); C, D: Ultrasound biomicroscopy examination illustrating no symptomatic decentration of IOL.

Table 2 Postoperative characteristics

Case	Follow-up (mo)	Preop. CDVA	Postop. CDVA	IOL tilt (degree)		IOL decentration (mm)		Complication
				Vertical	Horizontal	Vertical	Horizontal	
1	7	20/200	20/25	5.4	5.9	0.23	0.35	PCO
2	6	20/200	20/60	7.1	6.5	0.48	0.39	PCO
3	6	20/100	20/20	6.1	5.8	0.29	0.18	-
4	6	20/80	20/20	4.5	3.1	0.33	0.21	-
5	15	20/100	20/20	2.5	2.3	0.41	0.28	-
6	10	20/60	20/20	3.8	2.3	0.25	0.22	PCO
7	11	20/200	20/40	8.1	9.3	0.77	0.43	PCO
8	24	20/400	20/200	11.3	10.3	0.87	0.49	PCO
9	7	20/100	20/20	3.1	2.5	0.27	0.15	-
10	24	20/80	20/20	2.2	2.8	0.19	0.13	-
11	11	20/100	20/30	8.4	6.7	0.43	0.26	PCO
12	24	20/80	20/30	7.7	6.2	0.54	0.41	-
13	24	20/200	20/40	6.8	5.9	0.72	0.38	PCO
14	12	20/100	20/30	5.5	5.2	0.23	0.12	-
15	7	20/200	20/20	5.1	8.8	0.32	0.41	-
16	8	20/100	20/25	7.9	3.5	0.46	0.11	-
17	24	20/80	20/200	6.4	2.6	0.45	0.14	PCO
18	24	20/200	20/20	7.5	5.7	0.38	0.22	-
19	48	20/400	20/50	4.6	8.9	0.25	0.28	-
20	48	20/200	20/40	7.2	5.1	0.37	0.33	-

CDVA: Corrected distance visual acuity; IOL: Intraocular lens; PCO: Posterior capsule opacification.

intracapsular cataract extraction (ICCE) was necessary for patients with zonular dialysis^[8]. The capsular bag could not be saved in most cases. Implantation of AC IOL or sutured IOL to the sclera can cause several complications, such as glaucoma or retinal detachment^[9-10]. Cionni *et al*^[5] reported an endocapsular ring with a fixed hook for use in eyes with zonular insufficiency. The CTR can be sutured to the sclera with the aid of this hook and without disrupting the capsular bag integrity.

Another study reported that it is a relatively effective and safe option to use this Cionni-modified CTR with IOL implantation for the treatment of lens pediatric and adult eyes with zonular deficiency and subluxation of different etiologies^[11]. However, the effects of Cionni-modified CTR implantation on patients with traumatic subluxated cataract are relatively few. CTR provided adequate stability and lens centration in the eye with less than 6 clock hours of zonular loss^[12]. It was found

that the modified CTR was effective in maintaining capsular expansion in eyes with extensive zonular deficiency^[13]. When used together with iris hooks, this expanded capsular bag helped to maintain the vitreous back. The CTR served to lift the bag up against the iris and effectively isolated the AC from the vitreous cavity. The formation of a seal between the vitreous cavity and the AC helped prevent further aqueous misdirection and vitreous prolapse during phacoemulsification, which may lead to the posterior capsule moving forward, resulting in polymerase chain reaction (PCR)^[14]. However, it is difficult to insert surgical devices when patients present with dense cataracts or extensive zonular deficiency. Rai *et al*^[15] found that inserting CTR as early as possible created additional pressure on the intact zonules, which led to further zonular deficiency. Therefore, a recommendation was made to delay CTR insertion as safely as possible. In the present study, the Cionni-modified CTR allowed implantation of IOL in the bag and intraoperatively promoted capsular bag centration. A minimal decentration of the IOL may occur in eyes with a single-eyelet CTR at the early postoperative period, and the decentration of the IOL was in the direction of fixation. In our study, the surgeon's assessment of zonular weakness determined which type of CTR to implant, as in other studies^[16-17]. Ocular trauma may have a more global angle of zonular weakness or dialysis than the intraoperatively estimated angle. Kim *et al*^[18] showed that 6 (6.7%) of 90 eyes had symptomatic IOL decentration with an average follow-up of 17.8mo, and these cases were all caused by 10-0 polypropylene breakage. These cases involved pediatric eyes and adult eyes. Gurler *et al*^[19] reported that after an average follow-up of 24mo, 6% of pediatric eyes needed secondary sutures for decentration of the IOL. Vasavada *et al*^[20] did not reveal symptomatic decentration of the IOL in eyes with traumatism, which is similar to our findings. The use of 10-0 polypropylene gives good immediate results, but the suture may disintegrate after several years, and this method needs to be improved in the future.

In the present study, the amount of IOL decentration and tilt measured by UBM was 0.48 ± 0.24 mm of vertical IOL decentration, 0.32 ± 0.13 mm of horizontal IOL decentration, $6.1^\circ \pm 2.6^\circ$ of horizontal IOL tilt, and $5.5^\circ \pm 2.6^\circ$ of vertical IOL tilt. All eyes in our study showed improved CDVA at the last postoperative examination. Goel reported that 20 of 22 eyes with traumatic zonular loss had elevated CDVA^[21]. Zhao *et al*^[22] reported that in the capsular bag fixation group, horizontal IOL decentration was 0.22 ± 0.17 mm, vertical IOL decentration was 0.25 ± 0.19 mm, horizontal IOL tilt was 4.04 ± 2.45 degrees, and vertical IOL tilt was 4.75 ± 2.27 degrees, which was similar to our results. Furthermore, posterior segment pathology could be masked by cataracts in some cases and was not observed. Therefore, patients who have traumatic

cataracts should be informed and warned of posttraumatic complications that may be found postoperatively. In the present study, there were no posterior segment complications associated with cataract surgeries, such as retinal detachment and macular edema. Due to the presence of vitreous in the AC during surgery, nine eyes required binocular anterior vitrectomy. PCO occurred in 8 eyes (45%) and was the most common visual complication after surgery. A study has shown that using intracapsular tension rings can reduce the secondary proliferation of lens epithelial cells^[23]. However, the Cionni-modified CTR had a fixed hook that lifted the anterior capsule away from the IOL, which facilitated lens epithelial cell migration into the capsule^[24]. In our study, we consider that the posterior capsule waves during the operation and the lens cortex are difficult to completely remove, which may lead to PCO after the operation. Thus, we performed Nd:YAG laser capsulotomy in these eyes, after which CTRs were stabilized. Our study indicated that it was safe to use Nd:YAG capsulotomy in eyes with traumatic cataract extraction and implantation of modified CTR. Dai *et al*^[25] showed that phacoemulsification with CTR implantation combined with ophthalmic endoscope-controlled goniosynechialysis is safe and effective in the treatment of secondary angle-closure glaucoma induced by traumatic lens subluxation. Jiang *et al*^[26] proved that four-eyelet CTR can effectively increase the rotational stability of toric IOLs in cataract patients with high myopia and astigmatism. The above studies confirmed the good results of using CTR in patients with glaucoma and high myopia. In our study, we further found that capsular bag preservation and better IOL concentration can be achieved without major complications in patients with severely traumatic subluxated cataracts.

In summary, although the surgeries are time-consuming and technically challenging and the learning curve is steep, the capsular bag could be saved in severely traumatic subluxated cataracts by using modified CTR. By inserting a disposable pouch retractor to engage the capsulorhexis to the center before phacoemulsification and fixing the CTR after implantation of the IOL, complications can be minimized, and good visual effects can be obtained in these damaged eyes.

ACKNOWLEDGEMENTS

Foundations: Supported by the National Natural Science Foundation of China (No.82070968); China Postdoctoral Science Foundation (No.2022M712386); Tianjin Health Research Project (No.TJWJ2022MS040; No.ZC20166); Nankai University Eye Institute (No.NKYKK202203; No.NKYKK202206); Tianjin Eye Hospital Research Project (No.YKYB1902); Natural Science Foundation of Tianjin (No.20JCQNJC01860); Tianjin Key Medical Discipline (Specialty) Construction Project (No.TJYXZDXK-016A).

Conflicts of Interest: Jiang H, None; Zhang W, None; Chu YH, None.

REFERENCES

- 1 Bardoloi N, Sarkar S, Burgute PS, Ghosh D, Deb AK. Capsular tension ring assisted phacoemulsification of morgagnian cataract. *Indian J Ophthalmol* 2021;69(7):1781-1785.
- 2 Cionni RJ, Osher RH. Management of profound zonular dialysis or weakness with a new endocapsular ring designed for scleral fixation. *J Cataract Refract Surg* 1998;24(10):1299-1306.
- 3 Li B, Snyder ME. Partial-thickness scleral tethering suture for optimum fixation and centration of transscleral-sutured intraocular lens-capsule complex. *J Cataract Refract Surg* 2019;45(12):1701-1703.
- 4 Das P, Ram J, Brar GS, Dogra MR. Results of intraocular lens implantation with capsular tension ring in subluxated crystalline or cataractous lenses in children. *Indian J Ophthalmol* 2009;57(6):431-436.
- 5 Cionni RJ, Osher RH, Marques DMV, Marques FF, Snyder ME, Shapiro S. Modified capsular tension ring for patients with congenital loss of zonular support. *J Cataract Refract Surg* 2003;29(9):1668-1673.
- 6 Chee SP, Chan NSW. Suture snare technique for scleral fixation of intraocular lenses and capsular tension devices. *Br J Ophthalmol* 2018;102(10):1317-1319.
- 7 Buttanri IB, Sevim MS, Esen D, Acar BT, Serin D, Acar S. Modified capsular tension ring implantation in eyes with traumatic cataract and loss of zonular support. *J Cataract Refract Surg* 2012;38(3):431-436.
- 8 Jiang HY, Fu WZ, Xu HX. The technique of phacoemulsification and intraocular lens implantation in subluxated cataract surgery. *Stem Cells Int* 2022;2022:3188710.
- 9 Forlini M, Bedi R. Intraocular lens implantation in the absence of capsular support: scleral-fixated vs retropupillary iris-claw intraocular lenses. *J Cataract Refract Surg* 2021;47(6):792-801.
- 10 Cheung CS, VanderVeen DK. Intraocular lens techniques in pediatric eyes with insufficient capsular support: complications and outcomes. *Semin Ophthalmol* 2019;34(4):293-302.
- 11 Goldfeather Ben-Zaken S, Kleinmann G. Results of using the AssiAnchor capsule device for subluxated crystalline lenses. *Indian J Ophthalmol* 2021;69(12):3511-3514.
- 12 Zhou L, Wu SC, Guo HF. Femtosecond laser combined with double-flange polypropylene suture capsular tension ring suspension for the treatment of subluxation of lens in Marfan syndrome. *Comput Math Methods Med* 2022;2022:9348311.
- 13 Ahmed IIK, Cionni RJ, Kranemann C, Crandall AS. Optimal timing of capsular tension ring implantation: Miyake-Apple video analysis. *J Cataract Refract Surg* 2005;31(9):1809-1813.
- 14 Wang AJ, Fan Q, Jiang YX, Lu Y. Primary scleral-fixated posterior chamber intraocular lenses in patients with congenital lens subluxation. *BMC Ophthalmol* 2021;21(1):411.
- 15 Rai G, Sahai AS, Kumar PR. Outcome of capsular tension ring (CTR) implant in complicated cataracts. *J Clin Diagn Res* 2015;9(12):NC05-NC07.
- 16 Yilmaz S, Mavi Yildiz A, Avci R. A comparative study of knotless versus knotted transscleral suture-fixated intraocular lens implantation. *Indian J Ophthalmol* 2022;70(1):131-137.
- 17 Sen P, Vinay Kumar S, Bhende P, Rishi P, Rishi E, Rao CT, Ratra D, Susvar P, Kummamuri S, Shaikh S, Gopal L. Surgical outcomes and complications of sutured scleral fixated intraocular lenses in pediatric eyes. *Can J Ophthalmol* 2018;53(1):49-55.
- 18 Kim EJ, Berg JP, Weikert MP, Kong LK, Hamill MB, Koch DD, Yen KG. Scleral-fixated capsular tension rings and segments for ectopia lentis in children. *Am J Ophthalmol* 2014;158(5):899-904.
- 19 Gurler B, Coskun E, Okumus S, Pinero DP, Ozcan E, Erbagci I. Surgical outcomes of isolated lens coloboma with or without cataract among young adults. *Can J Ophthalmol* 2014;49(2):145-151.
- 20 Vasavada AR, Praveen MR, Vasavada VA, Yeh RY, Srivastava S, Koul A, Trivedi RH. Cionni ring and in-the-bag intraocular lens implantation for subluxated lenses: a prospective case series. *Am J Ophthalmol* 2012;153(6):1144-1153.e1.
- 21 Goel N. Clinical outcomes of combined pars Plana vitrectomy and trans-scleral 4-point suture fixation of a foldable intraocular lens. *Eye (Lond)* 2018;32(6):1055-1061.
- 22 Zhao YE, Gong XH, Zhu XN, Li HM, Tu MJ, Coursey TG, Pflugfelder SC, Gu F, Chen D. Long-term outcomes of ciliary sulcus versus capsular bag fixation of intraocular lenses in children: an ultrasound biomicroscopy study. *PLoS One* 2017;12(3):e0172979.
- 23 Praveen MR, Shah GD, Vasavada AR, Dave KH. The effect of single-piece hydrophobic acrylic intraocular lenses on the development of posterior capsule opacification. *Am J Ophthalmol* 2015;160(3):470-478.e1.
- 24 Kumar DA, Agarwal A, Packiyalakshmi S, Jacob S, Agarwal A. Complications and visual outcomes after glued foldable intraocular lens implantation in eyes with inadequate capsules. *J Cataract Refract Surg* 2013;39(8):1211-1218.
- 25 Dai Q, Fu L, Liu XY, Pan WH. Effective treatment for secondary angle-closure glaucoma caused by traumatic lens subluxation: phacoemulsification with capsular-tension-ring implantation combined with ophthalmic endoscope-controlled goniosynechialysis. *Int J Ophthalmol* 2021;14(10):1548-1552.
- 26 Jiang HM, Liang K, Tao LM. Comparative evaluation of rotational stability of toric IOLs with four-eyelet vs two-eyelet capsular tension rings in eyes with high myopia. *Int J Ophthalmol* 2021;14(3):378-382.