

Unilateral blurred vision in pediatric patient associated with cavum velum interpositum cyst

Margarita Zamorano, Esperanza García-Romo, Román Blanco-Velasco, Belén Fernández, Francisco J. Monescillo, Bernardo Fernández de Arévalo

Department of Ophthalmology, University Hospital Guadalajara, Guadalajara 19002, Spain

Correspondence to: Margarita Zamorano. University Hospital Guadalajara, Calle Donante de Sangre, Guadalajara 19002, Spain. margazamo@gmail.com

Received: 2022-08-29 Accepted: 2023-05-16

DOI:10.18240/ijo.2023.07.23

Citation: Zamorano M, García-Romo E, Blanco-Velasco R, Fernández B, Monescillo FJ, Fernández de Arévalo B. Unilateral blurred vision in pediatric patient associated with cavum velum interpositum cyst. *Int J Ophthalmol* 2023;16(7):1164-1166

Dear Editor,

We present for the first time, a case of a paediatric patient with symptoms of intermittent blurred vision as first symptom of a cavum of the velum interpositum (CVI).

Intracranial anterior midline cysts can be found in three variants: cavum septum pellucidum, cavum vergae and cavum velum interpositum. The CVI is a midline virtual space above the choroid tissue of the third ventricle and thalamus, between the pillars of the fornix, with the corpus callosum and hippocampal commissure cranially, and the internal cerebral veins caudally^[1]. This structure is not covered by cells of the choroid or ependymal plexus that produce cerebrospinal fluid (CSF), but is connected to the subarachnoid space and may fill with CSF and create a cystic formation.

The pathophysiological mechanism for CVI cystic dilatation is unclear and it is also unclear whether isolated CVI cysts are a normal variant or developmental malformations. Clinical manifestations of CVI cysts have been described as headache, epilepsy, memory and behavioural disturbances and ophthalmological manifestations such as strabismus^[2].

We describe the ophthalmological and neurological findings in a girl who was referred to the ophthalmology department for intermittent decrease in vision, without complete loss of vision. The symptoms were present in her left eye with ipsilateral cranial headache with fifteen days of evolution. This paper is

adhered to the tenets of the Declaration of Helsinki and the patient signed the informed consent.

A 10-year-old girl was referred by her pediatrician for intermittent blurred vision in the left eye and ipsilateral headache for two weeks. The patient reported that she had had in the last month, four episodes of intermittent blurred vision lasting each one for 5min.

The pediatrician had taken a visual acuity of 0.6 in left eye on the Snellen test. On ophthalmological examination, visual acuity was unity in both eyes without correction and without refractive defect under cycloplegia. Of interest, no symptoms were present during our examination. Extrinsic and intrinsic ocular motility and slit-lamp examination were normal in both eyes. Fundus examination showed raised optic discs with preserved margins, normal appearing macules and a choroidal nevus in the left eye (Figure 1). Ultrasound-B of the eyeball was compatible with optic disc drusen in both eyes (Figure 2). An OCT of the retinal nerve fibre (Figure 3) layer and 24-2 automatic perimetry (Figure 4) were performed, both tests being normal.

In the absence of findings on examination, a brain magnetic resonance imaging (MRI) without contrast T1 sequence was performed. MRI showed, in both sagittal and axial sections, an interhemispheric cystic structure ($27 \times 35 \times 27 \text{ mm}^3$) compatible with a cyst of the CVI (Figure 5).

The patient was diagnosed with a CVI cyst, whose diagnosis is exceptional in ophthalmology.

Oral analgesia was prescribed to control the headache, which subsided with paracetamol 1 gram/8h for 24h. In this patient, since this was her first episode of symptoms, and her headache responded well to medical treatment, and since it has been described that with age the size of the CVI cyst can decrease spontaneously, conservative management and close follow-up by a neuropaediatric and ophthalmology department was decided. The patient came for a follow up visit after eight months and remains asymptomatic without new episodes. New ophthalmology controls have remained stable with no change in the imaging tests compared to previous ones.

The CVI cyst is a common finding in new-borns that disappears with brain maturation by the end of the first year

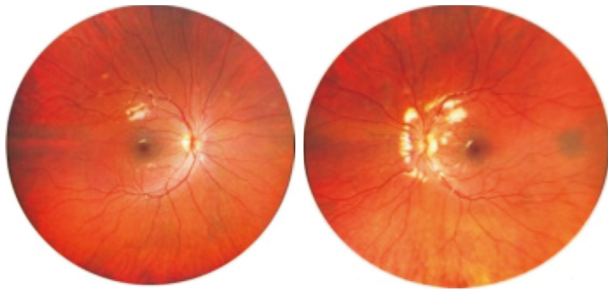


Figure 1 Raised optic discs with preserved margins, normal macules and a choroidal nevus in the left eye.

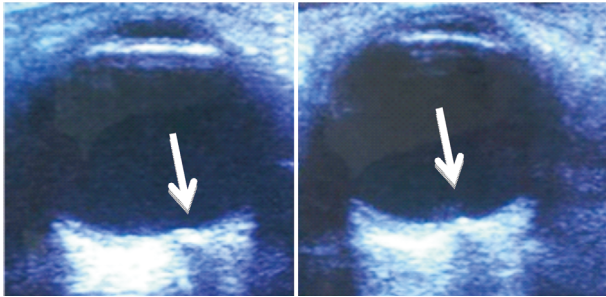


Figure 2 Optic drusen disc in both eyes.




Figure 3 OCT retinal nerve fibre layer is normal in both eyes OCT: Optical coherence tomography.

of life and rarely persists. Its prevalence has been reported between 2%-3% of new-borns.

The differential diagnosis of this midline brain cyst includes enlargement of the third ventricle, aneurysm of the Galen vein, interhemispheric cysts in relation to agenesis of the corpus callosum and suprasellar arachnoid cyst^[3].

Although most CVI cysts are asymptomatic, they may be associated with neurological or compressive symptoms when their size exceeds 10 mm. The treatment of choice consists of endoscopic fenestration to create a communication between the cyst and the ventricular system, thus reducing its size^[4].

In the paediatric population, the most frequent causes of blurred vision and headache are: astigmatism, myopia, hyperopia, amblyopia, optic neuritis and migraines with aura. Optic disc drusen are often detected incidentally on fundus examination. Most patients are asymptomatic, but cases with associated decreased vision and visual field defects have been reported. Therefore drusen should be considered within the differential causal diagnosis. However the patient had bilateral optic nerve drusen, and only blurred vision in the left eye. Also the patient presents accompanying headache. All this together makes us think that the neurological cause is more probable than the optic nerve drusen in this case.

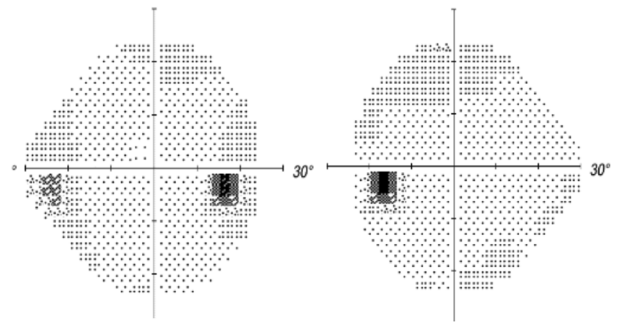


Figure 4 24-2 automatic perimetry is normal in both eyes.

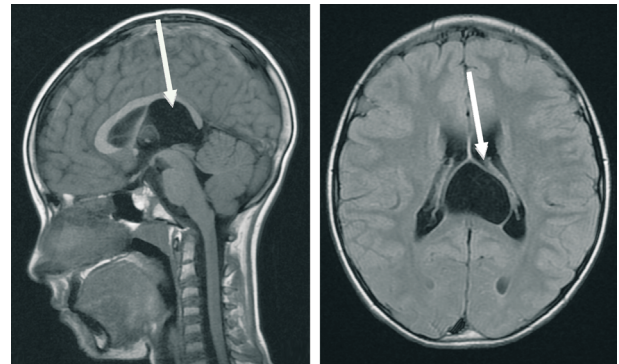


Figure 5 Cyst of the CVI seen on brain MRI CVI: Cavum of the velum interpositum; MRI: Magnetic resonance imaging.

Our patient referred unilateral intermittent blurred vision without defects in the visual field or in the OCT of the retinal nerve fibre layer in both eyes. The CVI cyst that was detected, suggest that this is the most probable aetiology of the symptoms reported by the patient. The intermittent symptoms could be explained by dynamic changes in the cyst dimensions. Such changes occur due to a valve mechanism between the CVI cyst and Galen's Vena Magna. Indeed transient increases in intracranial pressure have been described as a causal factor for changes in cyst dimensions. This valve mechanism has been observed *in vivo* and would support the hypothesis of a valve mechanism as a potential factor responsible for the growth of anterior midline cysts^[5].

In conclusion, we would like to highlight the importance of ruling out neurological diseases in paediatric patients with visual disturbances and no apparent causal findings. In the reported case, after excluding refractive and optic nerve pathology to explain her symptoms, an imaging test (MRI) led to the extremely rare diagnosis of CVI cyst. Even if there is not a 100% proven causality we do recommend that CVI should be added in the working hypothesis and differential diagnosis in patients with intermittent blurred vision. In this patient with intermittent symptoms, improvement of headache with oral analgesia, and no signs of compression, and given that these cysts tend to decrease in size with age, close interdisciplinary follow-up is indicated before carrying out more aggressive therapies such as endoscopic fenestration.

ACKNOWLEDGEMENTS

Authors' contributions: Zamorano M: Conception and design and draft the manuscript; García-Romo E, Blanco-Velasco R, Fernández B, Monescillo FJ, Fernández de Arévalo B: Revise the manuscript critically for important intellectual content; and final approval.

Conflicts of Interest: Zamorano M, None; García-Romo E, None; Blanco-Velasco R, None; Fernández B, None; Monescillo FJ, None; Fernández de Arévalo B, None.

REFERENCES

- 1 Arteaga JM, Parés P, Molet J, Oliver B, Tresserras P, Ayats E, Bartumeus F. Cavum velum interpositum neuroendoscopic treatment. *Neurocirugía* 2001;12(3):262.
- 2 Krejčí T, Vacek P, Krejčí O, Chlachula M, Szathmaryová S, Lipina R. Symptomatic cysts of the cavum septi pellucidi, cavum vergae and cavum veli interpositi: a retrospective duocentric study of 10 patients. *Clin Neurol Neurosurg* 2019;185:105494.
- 3 Moradi B, Rahmani M, Kia K, Ali Kazemi M, Tahmasebpour AR. Cavum velum interpositum cysts in normal and anomalous fetuses in second trimester of pregnancy: comparison of its size and prevalence. *Taiwan J Obstet Gynecol* 2019;58(6):814-819.
- 4 Al-Sharydah AM, Al-Suhbani SS, Al-Abdulwahhab AH, Al-Aftan MS, Gashgari AF. A unique finding of cavum velum interpositum colloid-like cyst and literature review of a commonplace lesion in an uncommon place. *Int J Gen Med* 2018;11:301-305.
- 5 Kojder K. Clinical and radiological characteristics of the cyst of the septum pellucidum in endoscopically treated patients. *Pomeranian J Life Sci* 2015;61(1):12-33.