

Efficacy and safety of ultrasound cycloplasty for the treatment of glaucoma: a Meta-analysis

Tian-Hong Wu, Xue Yin, Jian-Qing Li, Pei-Rong Lu

Department of Ophthalmology, the First Affiliated Hospital of Soochow University, Suzhou 215006, Jiangsu Province, China

Correspondence to: Pei-Rong Lu. Department of Ophthalmology, the First Affiliated Hospital of Soochow University, Shizi Street 188, Suzhou 215006, Jiangsu Province, China. lupeirong@suda.edu.cn

Received: 2023-02-25 Accepted: 2023-06-16

Abstract

● **AIM:** To evaluate the efficacy and safety of ultrasound cycloplasty (UCP) for glaucoma.

● **METHODS:** A comprehensive search of PubMed, Embase, Web of Science, and Google Scholar databases was used to select studies met the inclusion criteria. Meta-analysis was performed by Review Manager and StataCorp LLC.

● **RESULTS:** A total of 19 articles met the inclusion criteria. Overall, UCP is effective and safe in the glaucoma treatment, the risk ratio (RR) of the success rate was 2.28 (95%CI, 1.82-2.84). After UCP, patients had a significant reduction in intraocular pressure (IOP; mm Hg), the weighted mean difference (WMD) was 11.39 (95%CI, 9.88-12.90). In addition, UCP brings fewer postoperative complications with RR of 0.30 (95%CI, 0.19-0.49). Most of the complications were short-term and mild. Postoperatively, patients' use of IOP-lowering medications reduced, the standardized mean difference (SMD) was 0.78 (95%CI, 0.40-1.17). However, best corrected visual acuity (BCVA; logMAR) did not have obvious improvement after UCP, the WMD was 0.01 (95%CI, -0.06-0.09). This procedure does provide painfulness relief, with RR of 3.06 (95%CI, 1.95-4.81).

● **CONCLUSION:** UCP is effective and safe for suitable glaucoma. It can effectively decrease IOP in glaucoma patients, reduce the patients' dependence on IOP-lowering medications after surgery, relief the painfulness and has fewer long-term or severe postoperative complications, but the BCVA did not improve much.

● **KEYWORDS:** ultrasound cycloplasty; glaucoma; efficacy; safety

DOI:10.18240/ijo.2023.08.19

Citation: Wu TH, Yin X, Li JQ, Lu PR. Efficacy and safety of ultrasound cycloplasty for the treatment of glaucoma: a Meta-analysis. *Int J Ophthalmol* 2023;16(8):1317-1325

INTRODUCTION

Globally, glaucoma is an important irreversible and blinding eye disease that seriously threatens the visual health of the individuals^[1]. The increase in intraocular pressure (IOP) acts on the optic nerve, resulting in visual field damage and eventually causing optic nerve atrophy^[2-3]. Therefore, controlling IOP is a primary issue for glaucoma patients^[1]. Currently, the treatments for glaucoma including pharmacotherapy and surgical methods^[4]. For those in the absolute stage, with vision lost or refractory glaucoma, cyclodestructive surgeries are aimed to reduce IOP and relieve ocular pain^[5].

Cyclodestructive procedures for glaucoma have been applied to clinic widely since the 1930s^[6]. The early used cyclocryotherapy and cyclodiathermy were technically demanding and poorly secured for their unpredictable dose-effect, which may lead to some obvious and unpredictable side effects^[7-10]. Cyclophotocoagulation depends on tissue pigmentation, although it provides better focused energy, the scattered light energy opposite the treatment location may causes damage to adjacent tissue^[6,9-11]. Endoscopic cycloplasty is relatively safer, but it is an invasive surgery, and may cause lens dislocation^[12-13].

Ultrasound cycloplasty (UCP) develops in recent years based on high intensity focused ultrasound (HIFU)^[14]. Before the UCP being put into service, some researchers had used HIFU to treat glaucoma on both humans and rabbits and achieved effective and well tolerated results^[14-18]. It uses HIFU to act on the ciliary body, reducing aqueous humor production, causing scleral thinning and increasing aqueous humor outflow from the uveoscleral pathway^[19-20]. This procedure is precise and rapid, reducing damage to surrounding tissue of the surgical regions^[11,19,21]. A growing number of clinical trials have demonstrated that UCP can bring better surgical results and fewer postoperative complications compared to other cyclodestructive surgeries^[5,19,22-25]. Here we have a report on the treatment effects of this procedure.

MATERIALS AND METHODS

Literature Collection The articles retrieved for this Meta-analysis was obtained from PubMed, Embase, Web of Science, and Google Scholar databases. A total of 212 articles were collected.

Inclusion Criteria The literature was included if met the following criteria: 1) defined the conditions for successful surgery; 2) recorded the IOP before and after the operation at each follow-up; 3) showed the complications clearly; 4) presented the subtype of glaucoma. The articles should be in English, and there was no geographical restriction.

Risk of Bias Evaluation The risk of bias in the articles was evaluated using the “risk of bias table”, it was carried out by the software Review Manage 5.4 (The Cochrane Collaboration) according to the Cochrane Handbook.

Data Extraction The characteristic data extracted from the articles include the first author, year of publication, country in which the study was carried out, study design, number of the participants’ eyes, length of follow-up period, the mean IOP before and after treatment, the subtype of glaucoma, and history of glaucoma surgeries.

The primary outcomes of this Meta-analysis were the success rate, the IOP changes and complications after UCP surgery. The effectiveness of UCP treatment was studied by risk ratio (RR) of success and the IOP changes before and after surgery. The complications were divided into long-term (presented for more than or equal to 3mo after surgery) or severe (significantly affecting vision and visual function) ones and short-term (disappeared within 3mo) or mild (less impactful on vision or visual function) ones. The safety was reflected by the occurrence of long-term or severe complications. We also analyzed the secondary outcomes, including the reduction of IOP-lowering medications usage, the improvement in best corrected visual acuity (BCVA) and painfulness relief.

Statistical Analysis All statistical analyses for this article were performed with Review Manage 5.4 (The Cochrane Collaboration) and StataCorp LLC (version 16, USA). Data from the studies was tested for heterogeneity, and when $I^2 > 50\%$ or $P < 0.05$, the data was tested using a random effects model. Conversely, a fixed effects model was used.

The outcomes underwent a subgroup analysis in which we used postoperative follow-up time, study design, and patients’ race as subgroup criteria, in order to observe whether these indicators had effects on the three primary outcomes or not.

The method used in the sensitivity analysis was to delete studies one by one, so the stability and the consistency of the outcomes could be presented. What’s more, the potential publication bias was shown by the funnel plots.

RESULTS

Selection of the Included Studies In the beginning, a total

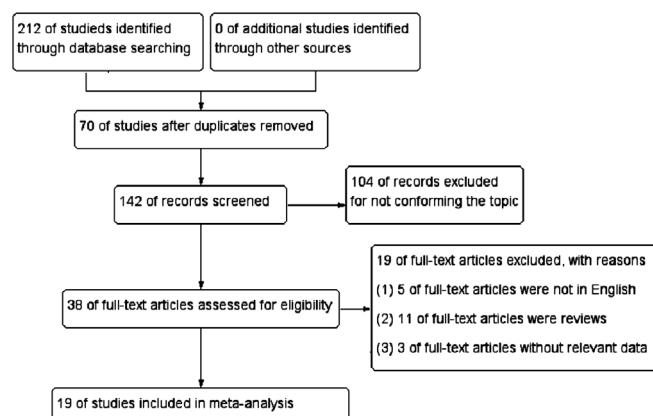


Figure 1 Flow diagram of the included studies of this Meta-analysis.

of 212 articles were founded, including 20 from PubMed, 26 from Embase, 15 from Web of Science, and 151 from Google Scholar. Through the screening, 70 of them were duplicates, by reading the title and abstract, 104 articles were found not fitting the topic, so they were excluded. Nineteen articles were excluded because they did not meet the criteria, and finally 19 were included in this Meta-analysis (Figure 1).

Quality and Characteristics of the Literature The “Risk of bias” was evaluated by the “Risk of bias table” (Figure 2). The characteristics of the included studies were shown in Table 1. A total of 1015 eyes from the 19 studies were included. Among them, 5 are cohort studies^[13,19,22,24,26], 10 are clinical trials^[20,25,27-34], 3 are interventional studies^[35-37] and 1 is case control study^[5].

Primary Outcomes In this Meta-analysis, one of the primary outcomes is the efficacy of the UPC (Figure 3A, 3B). The success rate of UCP was high [RR: 2.28 (95%CI, 1.82-2.84), $P < 0.00001$, $I^2 = 72\%$; Figure 3A]. Generally, success rate was higher than failure rate, but the result of Zhou *et al*^[20] was opposite, in which failure rate was higher. A statistically significant decrease was observed in postoperative IOP compared to preoperative one [weighted mean difference (WMD): 11.39 (95%CI, 9.88-12.90), $P < 0.00001$, $I^2 = 79\%$; Figure 3B]. Besides, we found that the procedure was safe and reliable, with few and mild postoperative complications [RR: 0.30 (95%CI, 0.19-0.49), $P < 0.00001$, $I^2 = 84\%$; Figure 3C], long-term or severe complications were rare, these were not even observed in some of the studies. The incidence of long-term or severe complications was overall significantly lower than that of short-term or mild, except the studies of Almobarak *et al*^[24] and Wang *et al*^[19], with $RR > 1$ (Figure 3C). Details of postoperative complications are presented in Table 2.

Secondary Outcomes The use of IOP-lowering medications after the surgery was significantly reduced [SMD: 0.78 (95%CI, 0.40-1.17), $P < 0.00001$, $I^2 = 84\%$; Figure 4A]. However, the BCVA (logMAR) of the patients had no statistically significant improvement after UCP [WMD: 0.01



Figure 2 Risk of bias graph and summary.

(95%CI, -0.06 to 0.09), $P=0.75$, $I^2=0$; Figure 4B]. UCP is very effective for painfulness relief [RR: 3.06 (95%CI, 1.95-4.81), $P<0.00001$, $I^2=18\%$; Figure 4C].

Subgroup Analysis When conducting the subgroup analysis, the duration of follow-up time, study design, and patients' race were used as grouping criteria for the success rate, the changes in IOP and the incidence of complications. There was only one case control study, and only one was from Africa, so they were not included in the subgroup analysis. The interventional study was found to be the source of heterogeneity in these three primary outcomes, with the RR of success rate being 3.51 (95%CI, 2.48-4.96, $P=0.57$, $I^2=0$), WMD of IOP changes being 8.00 (95%CI, 6.69-9.30, $P=0.78$, $I^2=0$) and the RR of postoperative complications being 0.11 (95%CI, 0.03-0.40, $P=0.2$, $I^2=37\%$; Table 3). Follow-up time was also a source of heterogeneity for IOP changes, the WMD was 11.39 (95%CI, 9.88-12.90, $P=0.09$, $I^2=47\%$) for the group with more than one year follow-up (Table 3).

Sensitivity Analysis and Publication Bias When the studies were removed one by one, no significant changes were observed in the overall results. Therefore, it is concluded that these results are reliable and stable (Figure 5). The funnel plots represent the publication bias of the primary outcomes' metric, the distribution of points in the graph of the primary outcomes is generally symmetrical, suggesting that little publication bias exists (Figure 6).

DISCUSSION

The conclusion we obtained from this Meta-analysis is that UCP is effective and safe as a treatment for glaucoma. Effectiveness is demonstrated by the fact that patients' postoperative IOP was controlled and had gained long-term stability, postoperative patients also had a significant reduction in terms of IOP-lowering medications usage. Wang *et al*^[19] and Yu *et al*^[5] compared UCP with cyclocryotherapy and cyclophotocoagulation respectively, the former concluded that UCP was overall more effective than cyclocryotherapy, the latter found patients' ocular pain was less severe after UCP compared to cyclophotocoagulation.

Long-term or severe complications were less frequent than short-term or mild complications in most studies, but result was opposite in the study of Wang *et al*^[19] and Almobarak *et al*^[24]. The main reason for the former study was that their short-term complications were too few, a total of 7 person-times, it appeared that there were many long-term complications in contrast, in fact, only one case of phthisis was the long-term or serious complications. The probable reason for the latter was that UCP was a secondary procedure in this trial, and these complications were caused by the preceding procedures, furthermore, 8 of the 17 cases were progression of cataracts, which is a multifactorial disease.

Nevertheless, even though the IOP was controlled after UCP, the patients' visual acuity still had no statistically significant improvement. UCP as a cyclodestructive procedure is suitable for absolute stage glaucoma, patients in this period usually possess relatively poor vision, the preexisting elevated IOP had caused irreversible damage to the vision, or these patients may combine with other ocular diseases that had already affected their visual acuity. So, many studies did not pay much attention to visual acuity improvement.

Pain relief effects of UCP is faster and more pronounced, in some studies it worked in a matter of hours and rarely recurred^[5,19]. Wang *et al*^[19] used a pain scale of 0-10 to make pain assessment easy, the preoperative pain assessment was 6.31±1.8, it declined to 0.09±0.3 six months after the surgery. Yu *et al*^[5] listed postoperative pain score, and found that the number of patients corresponding to pain grading from 0 to 3 were 9, 3, 2 and 0 respectively. Wang *et al*^[31] and Zhou *et al*^[20] reported several patients felt pain during UCP procedure but this was tentative and the painfulness disappeared after

Table 1 Characteristics of included studies

First author (year)	Country	Study design	Sample size (n)	Follow-up time (mo)	IOP (mm Hg)		Glaucoma subtype			Glaucoma surgery history (person-time)
					Preoperative	Postoperative	POAG (n)	PACG (n)	SG/NVG (n)	
Leshno (2020) ^[37]	Israel	Prospective interventional study	15	24	26.80±5.00	17.60±4.40	9	0	6/0	3
Paul (2022) ^[13]	India	Prospective cohort study	28	12	24.93±4.27	15.82±3.14	21	0	7/2	NA
Deb-Joardar (2018) ^[35]	India	Prospective interventional study	73	12	23.5±3.00	15.70±5.40	65	0	8/0	73
Almobarak (2022) ^[24]	Saudi Arabia	Retrospective cohort study	66	24	23.02±6.10	16.44±5.30	66	0	0/0	30
Almobarak (2022) ^[26]	Saudi Arabia	Retrospective cohort study	182	24	23.46±6.30	14.69±4.40	69	66	47/19	77
Figus (2021) ^[30]	Swiss	Prospective clinical trial	66	24	24.30±2.90	15.90±3.60	54	0	12/0	10
Giannaccare (2019) ^[36]	Italy	Prospective interventional study	49	12	27.70±9.20	19.80±6.90	24	9	16/5	25
Giannaccare (2021) ^[32]	Italy	Prospective clinical trial	66	24	28.50±9.60	17.00±5.40	36	11	19/7	28
Liu (2020) ^[27]	China	Retrospective clinical trial	37	6	44.10±11.90	30.40±14.50	2	3	32/20	13
Rouland (2021) ^[22]	France	Prospective cohort study	104	36	27.60±8.90	17.00±6.80	60	2	42/0	76
Torky (2019) ^[34]	Egypt	Retrospective clinical trial	62	12	35.20±8.30	20.60±8.70	13	10	39/15	NA
Luo (2022) ^[29]	China	Retrospective clinical trial	23	6	37.20±12.10	22.00±7.20	7	9	7/NA	16
Yu (2020) ^[5]	China	Retrospective case control study	28	12	43.36±12.68	22.57±4.50	4	3	7/3	NA
Marques Sarmento (2021) ^[33]	Portugal	Prospective clinical trial	49	12	26.90±7.40	17.80±6.40	24	2	23/4	7
Wang (2020) ^[19]	China	Prospective cohort study	49	6	54.60±9.70	30.30±9.30	0	0	49/49	26
Morais (2021) ^[28]	Portugal	Prospective clinical trial	14	12	28.50±7.61	15.23±10.33	13	0	1/1	15
Wang (2021) ^[31]	China	Prospective clinical trial	36	6	53.61±12.40	30.53±15.72	2	2	32/24	8
Rong (2022) ^[25]	China	Retrospective clinical trial	43	12	28.40±14.70	14.40±3.90	18	15	10/4	12
Zhou (2022) ^[20]	China	Prospective clinical trial	25	12	39.70±6.10	27.10±11.00	1	6	18/12	11

Data of IOP: Mean±standard deviation. IOP: Intraocular pressure; POAG: Primary open angle glaucoma; PACG: Primary angle-closure glaucoma; SG: Secondary glaucoma; NVG: Neovascular glaucoma; NA: Not available.

Table 2 Details of postoperative complications

First author (year)	Short-term or mild					Long-term or severe						
	Corneal problems	Transient mydriasis	Transient hypotony	Ocular pain	Others	Astigmatism	Mydriasis	Cataract development	Hypotony	Ocular pain	Phthisis	Others
Leshno (2020) ^[37]	-	-	-	-	13	-	-	-	-	-	-	-
Paul (2022) ^[13]	-	-	-	-	9	-	-	-	-	-	-	-
Deb-Joardar (2018) ^[35]	7	-	-	-	135	2	1	-	3	-	-	33
Almobarak (2022) ^[24]	1	-	-	-	3	-	-	8	2	-	-	7
Almobarak (2022) ^[26]	3	-	-	-	41	-	-	34	2	-	3	25
Figus (2021) ^[30]	10	13	3	2	71	-	-	-	-	-	-	6
Giannaccare (2019) ^[36]	19	-	-	-	81	-	-	-	-	-	-	-
Giannaccare (2021) ^[32]	8	3	-	-	22	-	-	-	-	-	-	3
Liu (2020) ^[27]	8	1	1	30	74	-	1	-	-	14	1	31
Rouland (2021) ^[22]	70	18	4	-	79	-	-	-	1	-	-	3
Torky (2019) ^[34]	6	2	-	-	65	-	-	-	-	-	-	-
Luo (2022) ^[29]	2	-	-	5	24	1	-	-	-	-	-	1
Yu (2020) ^[5]	2	-	-	-	-	-	-	-	-	-	-	1
Marques Sarmento (2021) ^[33]	1	9	-	-	11	-	2	-	1	-	-	14
Wang (2020) ^[19]	1	-	2	-	4	-	-	-	-	-	1	-
Morais Sarmento (2021) ^[28]	9	-	2	-	25	-	-	-	-	-	-	15
Wang (2021) ^[31]	-	-	-	-	32	-	-	-	2	-	-	1
Rong (2022) ^[25]	-	-	-	-	16	-	-	-	-	-	-	-
Zhou (2022) ^[20]	-	-	-	-	23	-	-	-	-	-	-	6

Corneal problems including keratitis, corneal edema and corneal abrasion; short-term or mild other complications including anterior chamber reaction, conjunctival hyperemia and macular edema; long-term or severe other complications including macular edema, choroid detachment and visual acuity reduction; all data are in units of person-time.

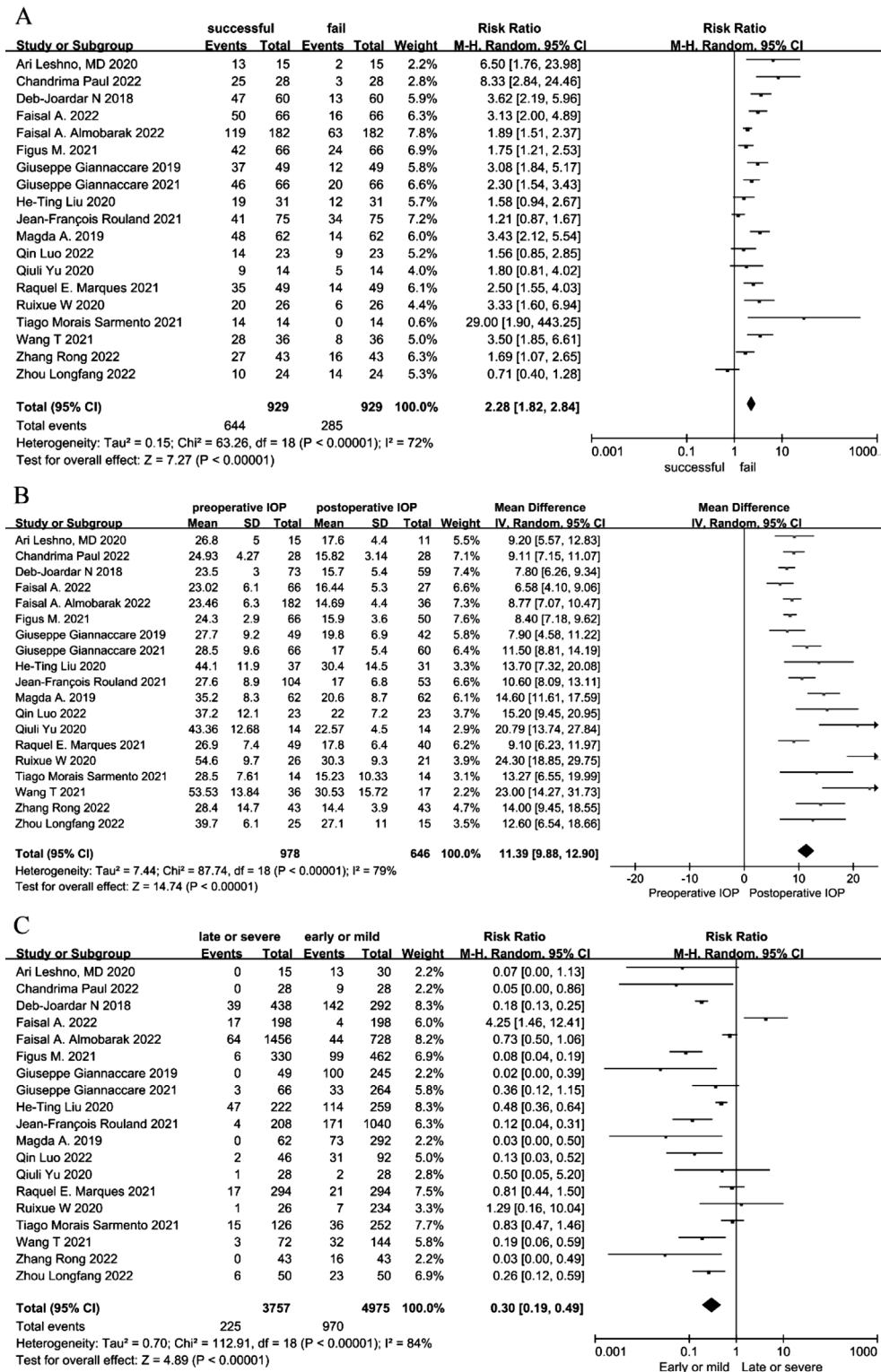


Figure 3 Forest plots of the primary outcomes A: The efficacy of ultrasound cycloplasty (UCP) surgery; B: The mean intraocular pressure (IOP) before and after UCP; C: Postoperative complications. When calculating the incidence of complications, we used the kinds of complications multiply by the number of incidences of each complication (person-time).

surgery. UCP as a treatment for pain relief in the final stage of glaucoma patients is worth considering.

Bolek *et al*^[38] and Sousa *et al*^[39] specifically investigated the size of the pupils and their sensitivity to light reflection after UCP, both of them came to the same conclusion: UCP did cause a short-term effect on the pupils, mainly in the form of

reduced reflection to light and irregular pupils. However, this phenomenon disappeared over time. Among the studies we included, changes in pupil size usually returned to normal at the last follow-up, only two patients experienced sustained anisocoria in the research of Marques *et al*^[33]. UCP has little effect on change of pupil dilation.

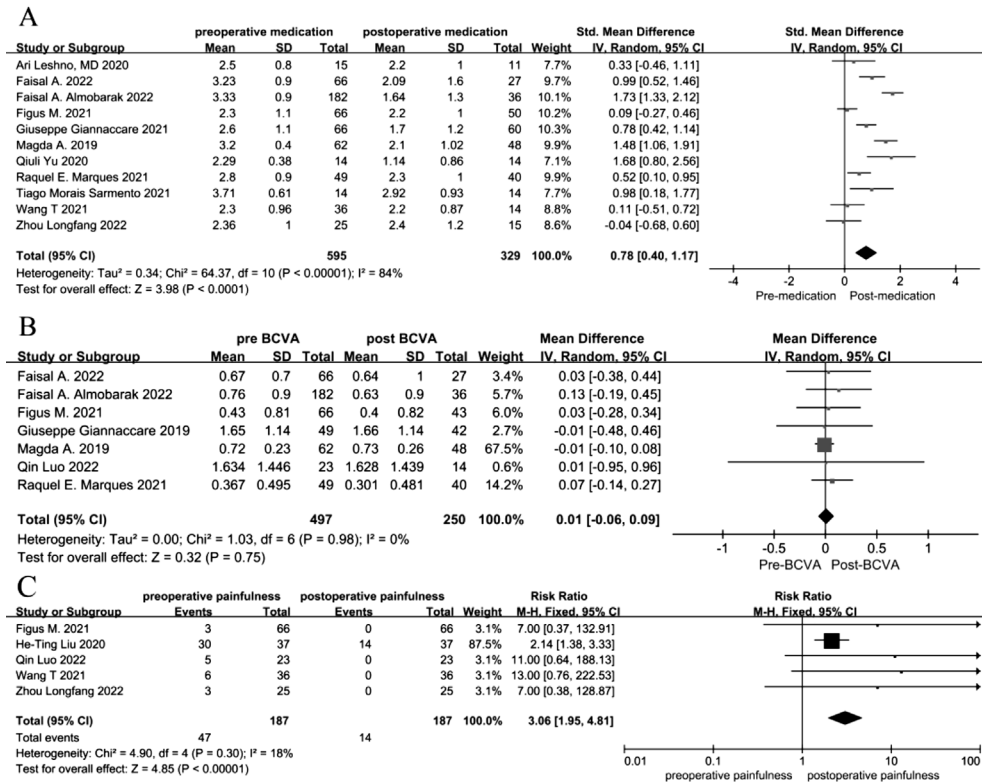


Figure 4 Forest plots of the secondary outcomes A: Preoperative and postoperative intraocular pressure (IOP)-lowering medications usage; B: Best corrected visual acuity (BCVA; logMAR) before and after surgery; C: Number of patients who felt painfulness before and after surgery.

Table 3 Results of the subgroup analysis

Parameters	Subgroups	Number of studies	Success rate			IOP changes			Incidence of complications		
			RR (95%CI)	I ² (%)	Heterogeneity P value	WMD (95%CI)	I ² (%)	Heterogeneity P value	RR (95%CI)	I ² (%)	Heterogeneity P value
Follow-up time	≤1y	13	2.58 (1.98,3.53)	70	<0.0001	13.40 (10.86,15.94)	83	<0.00001	0.29 (0.17, 0.49)	79	<0.00001
	>1y	6	2.02 (1.50,2.72)	71	0.004	11.39 (9.88, 12.90)	47	0.09	0.34 (0.10, 1.14)	91	<0.00001
Patients' race	Asia	12	4.80 (3.73, 6.17)	77	<0.00001	9.44 (8.61, 10.27)	84	<0.00001	0.63 (0.49, 0.79)	90	<0.00001
	Europe	6	3.99 (2.89, 5.50)	77	0.0005	9.17 (8.26, 10.08)	78	<0.00001	0.39 (0.28, 0.53)	86	0.0007
Study design	Cohort study	5	2.46 (1.53, 3.94)	83	0.0001	10.97 (7.74, 14.20)	89	<0.00001	0.56 (0.15, 2.15)	87	<0.00001
	Clinical trail	10	1.99 (1.48, 2.69)	68	0.0008	12.85 (10.27, 14.88)	74	<0.0001	0.25 (0.12, 0.50)	79	<0.00001
	Interventional study	3	3.51 (2.48, 4.96)	0	0.57	8.00 (6.69, 9.30)	0	0.78	0.11 (0.03, 0.40)	37	0.2

Study of Yu *et al*^[5] was the only one case control study, and Figus *et al*^[30] was the only one from Africa, so they were not included in the subgroup analysis. IOP: Intraocular pressure; RR: Risk ratio; WMD: Weighted mean difference.

Four studies included more than 75% of primary open angle glaucoma (POAG) patients^[13,24,28,36], the success rate was relatively higher. Giannaccare *et al*^[32] demonstrated that rate of success was higher in POAG patients, but after multivariate analysis, this was no longer significant. Conclusions on whether POAG affects UCP surgical outcomes are inconsistent and further research are needed. Luo *et al*^[29] concluded that primary angle-closure glaucoma (PACG) achieved better results than other type of glaucoma. But they thought this conclusion would be confirmed by other series on a larger population. Zhou *et al*^[20] found the success rate of the neovascular glaucoma (NVG) was lower. Wang *et al*^[19] included more than 50% patients with NVG, and the incidence of long-term or severe complications was higher. There existed

67% patients in the study of Wang *et al*^[31] combined with NVG, but the success rate was high and long-term or severe complications were few. We considered this may be due to their short follow-up time. The above results convince us that NVG affects the effectiveness and safety of UCP. Figus *et al*^[30] conducted the study on the surgery-naive glaucoma patients, they found UCP was effective, valuable, and well-tolerated, patients in their study needed no additional procedures after the first UCP treatment. Almobarak *et al*^[23] performed UCP on patients who had a failed previous glaucoma surgery and observed the results, concluding that the effectiveness and safety of UCP as a secondary glaucoma procedure were also guaranteed. Luo *et al*^[29] illustrated that previous glaucoma surgeries had no effect on the outcomes

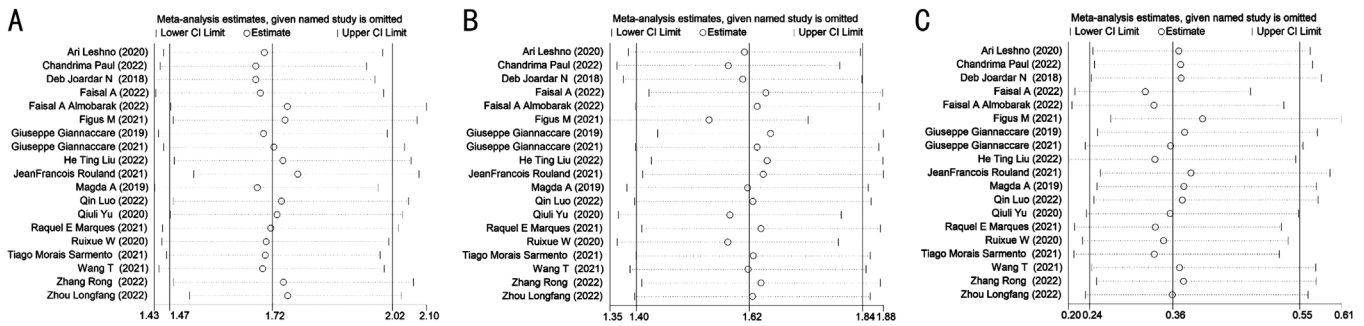


Figure 5 Sensitivity analyses of the primary outcomes A: The success rate; B: The intraocular pressure changes; C: Incidence of complications.

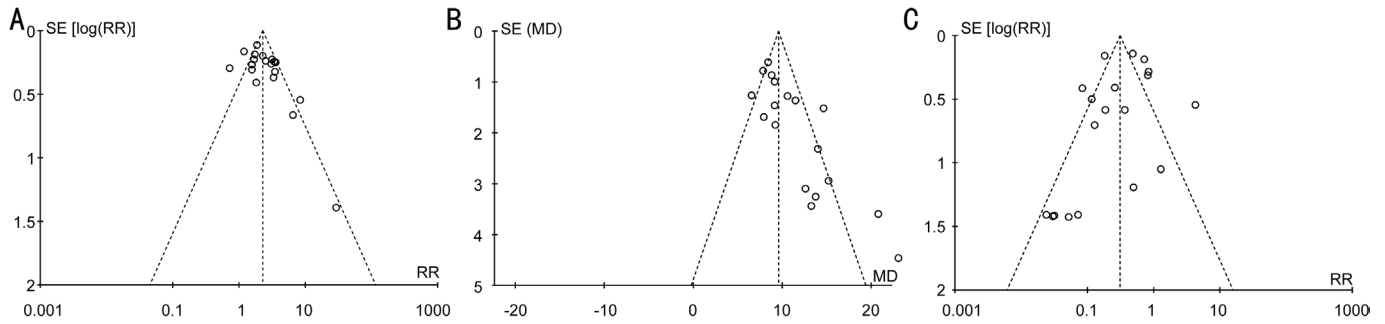


Figure 6 Funnel plots of the primary outcomes A: The funnel plot of effectiveness; B: The mean intraocular pressure changes; C: Incidence of postoperative complications.

of UCP procedure. Aptel *et al*^[39] reported that for patients who failed in the first UCP surgery, a second one was considered, which was also safe and effective. De Gregorio *et al*^[40] evaluate long-term results of repeated ultrasonic circular cyclocoagulation in uncontrolled glaucoma patients, they found that multiple treatments were safe and increased the overall procedure efficacy. Together, these results suggest that history of anti-glaucoma surgery or repeated UCP procedure have no effects on the efficacy and safety of outcomes. Although a lot of clinical studies have now confirmed that UCP is safe and effective, Luo *et al*^[41] reported a case: for the patient with cataract combined with angle-closure glaucoma, UCP was not the preferred method but cataract surgery was the best treatment option. Marques *et al*^[42] measured the effects of the UCP on corneal astigmatism and total induced astigmatism, they drew the conclusion that UCP may increase corneal astigmatism to some extent, but it did not affect total astigmatism. Bolek *et al*^[43] performed corneal topography and measurement of corneal parameters, the results reflected that the effect of UCP on corneal astigmatism decreased over time. Pellegrini *et al*^[44] conducted the study of intraocular inflammation after UCP, a dramatic increase in flare values was found on the first postoperative day, the values reached baseline by 3 and 6mo postoperatively. Bolek *et al*^[45] assessed the scleral and conjunctival thickness by optical coherence tomography. The thickness of sclera increased after UCP, however, it declined to initial value over time, there existed no statistically significant difference comparing to preoperative

thickness. These are all consistent with our description of post-UCP complications that will diminish over time. Torky *et al*^[46] used Phaco-UCP as the surgery method, which combined phacoemulsification and ultrasound cycloplasty, they concluded that the Phaco-UCP was also safe and effective. Zheng *et al*^[47] investigated the suitable probe model for UCP in Chinese, and currently, there have been a certain number of studies on the efficacy and safety of UCP, but few on the specific surgical implementation. More attention is worth paying to this direction. There is a lack of studies with large sample sizes and long follow-up periods regarding the safety and efficacy of UCP.

Limitations of this study: First, the selection bias and implementation bias are high because all the included studies are not randomized controlled trial (RCT), only one of them is a case-control study. Second, UCP has not been commonly used in clinical practice, and there is a lack of long-term observation regarding the postoperative effects and safety. The longest and only one observation period in our included studies is 3y^[22], therefore, the long-term effects cannot be concluded here. Additionally, six of the included articles had a sample size of less than 30^[5,13,20,28-29,37], and prospective studies inevitably have the result of patients being missed during follow-up process, this may influence the accuracy of outcomes. Last but not least, when conducting the subgroup analysis, the subtype of glaucoma, and initial or secondary procedure should be used as grouping criteria, but all studies included patients with mixed glaucoma subtypes and glaucoma surgery history,

except Almobarak *et al*^[24] with all POAG, Wang *et al*^[19] with all NVG, and Deb-Joardar and Reddy^[35] with all included patients having underwent a history of glaucoma surgery, the subgroup analysis in this article is not very comprehensive.

ACKNOWLEDGEMENTS

Authors' contributions: Wu TH and Lu PR designed the study. Wu TH searched the literature, analyzed the data, and wrote this literature. Lu PR, Yin X, and Li JQ polished the article.

Conflicts of Interest: Wu TH, None; Yin X, None; Li JQ, None; Lu PR, None.

REFERENCES

- Chen D, Guo XJ, Luo SK, Lu Y, Tang XR. Efficacy and safety of high-intensity focused ultrasound cyclo-plasty in glaucoma. *BMC Ophthalmol* 2022;22(1):401.
- Preda MA, Karancsi OL, Munteanu M, Stanca HT. Clinical outcomes of micropulse transscleral cyclophotocoagulation in refractory glaucoma-18mo follow-up. *Lasers Med Sci* 2020;35(7):1487-1491.
- Pinto LA, Melamed S, Nardi M and Stalmans I. Ultrasound cyclo plasty in surgery naïve open angle glaucoma patients. Interim month-18 results of a prospective multicenter clinical trial. *World Glaucoma Congress* 2019. https://eyetechcare.com/fileadmin/user_upload/2019-poster-wgc-pinto-eu-bn02-study.pdf
- Tsang S, Cheng J, Lee JWY. Developments in laser trabeculoplasty. *Br J Ophthalmol* 2016;100(1):94-97.
- Yu QL, Liang Y, Ji FF, Yuan ZL. Comparison of ultrasound cycloplasty and transscleral cyclophotocoagulation for refractory glaucoma in Chinese population. *BMC Ophthalmol* 2020;20(1):387.
- Anand N, Klug E, Nirappel A, Solá-Del Valle D. A review of cyclodestructive procedures for the treatment of glaucoma. *Semin Ophthalmol* 2020;35(5-6):261-275.
- Michelessi M, Bicket AK, Lindsley K. Cyclodestructive procedures for non-refractory glaucoma. *Cochrane Database Syst Rev* 2018; 4(4):CD009313.
- Posarelli C, Covello G, Bendinelli A, Fogagnolo P, Nardi M, Figus M. High-intensity focused ultrasound procedure: the rise of a new noninvasive glaucoma procedure and its possible future applications. *Surv Ophthalmol* 2019;64(6):826-834.
- Aptel F, Tadjine M, Rouland JF. Efficacy and safety of repeated ultrasound cycloplasty procedures in patients with early or delayed failure after a first procedure. *J Glaucoma* 2020;29(1):24-30.
- Dastiridou AI, Katsanos A, Denis P, Francis BA, Mikropoulos DG, Teus MA, Konstas AG. Cyclodestructive procedures in glaucoma: a review of current and emerging options. *Adv Ther* 2018;35(12):2103-2127.
- Aptel F, Charrel T, Palazzi X, Chapelon JY, Denis P, Lafon C. Histologic effects of a new device for high-intensity focused ultrasound cyclocoagulation. *Invest Ophthalmol Vis Sci* 2010;51(10):5092-5098.
- Francis BA, Pouw A, Jenkins D, Babic K, Vakili G, Tan J, Chopra V, Green RL. Endoscopic cycloplasty (ECPL) and lens extraction in the treatment of severe plateau iris syndrome. *J Glaucoma* 2016;25(3):e128-e133.
- Paul C, Divya J, Sengupta S, Kamal R, Paul A, Mitra I. Efficacy and safety of ultrasound cycloplasty in Indian eyes with open-angle glaucoma. *Indian J Ophthalmol* 2022;70(12):4168-4171.
- Charrel T, Aptel F, Birer A, Chavrier F, Romano F, Chapelon JY, Denis P, Lafon C. Development of a miniaturized HIFU device for glaucoma treatment with conformal coagulation of the ciliary bodies. *Ultrasound Med Biol* 2011;37(5):742-754.
- Aptel F, Denis P, Rouland JF, Renard JP, Bron A. Multicenter clinical trial of high-intensity focused ultrasound treatment in glaucoma patients without previous filtering surgery. *Acta Ophthalmol* 2016;94(5):e268-e277.
- Aptel F, Charrel T, Lafon C, Romano F, Chapelon JY, Blumen-Ohana E, Nordmann JP, Denis P. Miniaturized high-intensity focused ultrasound device in patients with glaucoma: a clinical pilot study. *Invest Ophthalmol Vis Sci* 2011;52(12):8747-8753.
- Denis P, Aptel F, Rouland JF, Nordmann JP, Lachkar Y, Renard JP, Sellem E, Baudouin C, Bron A. Cyclocoagulation of the ciliary bodies by high-intensity focused ultrasound: a 12-month multicenter study. *Invest Ophthalmol Vis Sci* 2015;56(2):1089-1096.
- Aptel F, Bégé A, Razavi A, Romano F, Charrel T, Chapelon JY, Denis P, Lafon C. Short- and long-term effects on the ciliary body and the aqueous outflow pathways of high-intensity focused ultrasound cyclocoagulation. *Ultrasound Med Biol* 2014;40(9):2096-2106.
- Wang RX, Wang T, Li N. A comparative study between ultrasound cycloplasty and cyclocryotherapy for the treatment of neovascular glaucoma. *J Ophthalmol* 2020;2020:4016536.
- Zhou LF, Hu D, Lan J, Liu YM, Lv MY, Pan XJ. Efficacy and safety of single Ultrasound Cyclo-Plasty to treat refractory glaucoma: results at 1y. *Eur J Ophthalmol* 2022;32(1):268-274.
- Polack PJ, Iwamoto T, Silverman RH, Driller J, Lizzi FL, Coleman DJ. Histologic effects of contact ultrasound for the treatment of glaucoma. *Invest Ophthalmol Vis Sci* 1991;32(7):2136-2142.
- Rouland JF, Aptel F. Efficacy and safety of ultrasound cycloplasty for refractory glaucoma: a 3-year study. *J Glaucoma* 2021;30(5):428-435.
- Almobarak FA, Alrubean A, Alsarhani WK, Aljenaidel A, Osman E. Ultrasound cyclo plasty after failed glaucoma surgery: outcomes and complications. *Ophthalmol Ther* 2022;11(4):1601-1610.
- Almobarak FA, Alrubean A, Alsarhani W, Aljenaidel A, Osman EA. Outcomes and predictors of failure of ultrasound cyclo plasty for primary open-angle glaucoma. *J Clin Med* 2022;11(22):6770.
- Rong Z, Li FH. Safety and efficacy of 8- and 10-sector ultrasound cyclocoagulation: a retrospective study. *Research Square* 2022. <https://www.researchsquare.com/article/rs-1741154/v1>
- Almobarak FA, Alrubean A, Alsarhani WK, Aljenaidel A, Osman EA. Ultrasound cyclo plasty in glaucoma: 2-year outcomes. *J Glaucoma* 2022;31(10):834-838.
- Liu HT, Zhang Q, Jiang ZX, Xu YX, Wan QQ, Tao LM. Efficacy and safety of high-dose ultrasound cyclo-plasty procedure in refractory

- glaucoma. *Int J Ophthalmol* 2020;13(9):1391-1396.
- 28 Morais Sarmiento T, Figueiredo R, Garrido J, Passos I, Rebelo AL, Candeias A. Ultrasonic circular cyclocoagulation prospective safety and effectiveness study. *Int Ophthalmol* 2021;41(9):3047-3055.
- 29 Luo Q, Xue WW, Wang YL, Chen B, Wang SS, Dong YP, Ru Y, Ge L. Ultrasound cycloplasty in Chinese glaucoma patients: results of a 6-month prospective clinical study. *Ophthalmic Res* 2022;65(4):466-473.
- 30 Figus M, Posarelli C, Nardi M, Stalmans I, Vandewalle E, Melamed S, Skaat A, Leshno A, Sousa DC, Pinto LA. Ultrasound cycloplasty for treatment of surgery-naïve open-angle glaucoma patients: a prospective, multicenter, 2-year follow-up trial. *J Clin Med* 2021;10(21):4982.
- 31 Wang T, Wang RX, Su Y, Li N. Ultrasound cycloplasty for the management of refractory glaucoma in Chinese patients: a before-after study. *Int Ophthalmol* 2021;41(2):549-558.
- 32 Giannaccare G, Pellegrini M, Bernabei F, Urbini L, Bergamini F, Ferro Desideri L, Bagnis A, Biagini F, Cassottana P, Del Noce C, Carnevali A, Scorcìa V, Traverso CE, Vagge A. A 2-year prospective multicenter study of ultrasound cycloplasty for glaucoma. *Sci Rep* 2021;11(1):12647.
- 33 Marques RE, Ferreira NP, Sousa DC, Barata AD, Sens P, Marques-Neves C, Abegão Pinto L. High intensity focused ultrasound for glaucoma: 1-year results from a prospective pragmatic study. *Eye (Lond)* 2021;35(2):484-489.
- 34 Torky MA, Al Zafiri YA, Hagraş SM, Khattab AM, Bassiouny RM, Mokbel TH. Safety and efficacy of ultrasound ciliary plasty as a primary intervention in glaucoma patients. *Int J Ophthalmol* 2019;12(4):597-602.
- 35 Deb-Joardar N, Reddy KP. Application of high intensity focused ultrasound for treatment of open-angle glaucoma in Indian patients. *Indian J Ophthalmol* 2018;66(4):517-523.
- 36 Giannaccare G, Vagge A, Sebastiani S, Urbini LE, Corazza P, Pellegrini M, Carmassi L, Bergamini F, Traverso CE, Campos EC. Ultrasound cyclo-plasty in patients with glaucoma: 1-year results from a multicentre prospective study. *Ophthalmic Res* 2019;61(3):137-142.
- 37 Leshno A, Rubinstein Y, Singer R, Sher I, Rotenstreich Y, Melamed S, Skaat A. High-intensity focused ultrasound treatment in moderate glaucoma patients: results of a 2-year prospective clinical trial. *J Glaucoma* 2020;29(7):556-560.
- 38 Bolek B, Wylegala A, Mazur R, Wylegala E. Pupil irregularity after ultrasound ciliary plasty in glaucoma treatment. *Acta Ophthalmol* 2019;97.
- 39 Sousa DC, Ferreira NP, Marques-Neves C, Somers A, Vandewalle E, Stalmans I, Pinto LA. High-intensity focused ultrasound cycloplasty: analysis of pupil dynamics. *J Curr Glaucoma Pract* 2018;12(3):102-106.
- 40 De Gregorio A, Pedrotti E, Stevan G, Montali M, Morselli S. Safety and efficacy of multiple cyclocoagulation of ciliary bodies by high-intensity focused ultrasound in patients with glaucoma. *Graefes Arch Clin Exp Ophthalmol* 2017;255(12):2429-2435.
- 41 Luo JH, Liu Z, Zhao L, Zhou Y, Kong L, Sun Y. Postoperative complicated peripheral cortical cataract after ultrasound cycloplasty: a case report. *BMC Ophthalmol* 2021;21(1):16.
- 42 Marques RE, Sousa DC, Vandewalle E, Somers A, Melamed S, Nardi M, Figus M, Stalmans I, Abegao Pinto L. The effect of glaucoma treatment using high-intensity focused ultrasound on total and corneal astigmatism: a prospective multicentre study. *Acta Ophthalmol* 2020;98(8):833-840.
- 43 Bolek B, Wylegala A, Wylegala E. The influence of ultrasound ciliary plasty on corneal parameters. *J Glaucoma* 2020;29(10):899-904.
- 44 Pellegrini M, Sebastiani S, Giannaccare G, Campos EC. Intraocular inflammation after ultrasound cycloplasty for the treatment of glaucoma. *Int J Ophthalmol* 2019;12(2):338-341.
- 45 Bolek B, Wylegala A, Wylegala E. Assessment of scleral and conjunctival thickness of the eye after ultrasound ciliary plasty. *J Ophthalmol* 2020;2020:9659014.
- 46 Torky MA, Alzafiri YA, Abdelhameed AG, Awad EA. Phaco-UCP; combined phacoemulsification and ultrasound ciliary plasty versus phacoemulsification alone for management of coexisting cataract and open angle glaucoma: a randomized clinical trial. *BMC Ophthalmol* 2021;21(1):53.
- 47 Zheng SY, Wang DQ, Huang ZH, et al. The distribution of ultrasound cycloplasty probe models in Chinese glaucoma patients. *Research Square* 2022. <https://www.researchsquare.com/article/rs-1343113/v1>