

# Clinical efficacy and changes of serum VEGF-A, VEGF-B, and PLGF after conbercept treating neovascular age-related macular degeneration

Xiao-Dong Chen<sup>1,2,3</sup>, Chan Li<sup>1,2</sup>, Guo-Long Ding<sup>1,2</sup>, Yan Suo<sup>1,2</sup>, Yu-Sheng Zhu<sup>2</sup>, Hui-Qin Lu<sup>1,2,3</sup>

<sup>1</sup>Department of Ophthalmology, Xi'an No.1 Hospital, Xi'an 710002, Shaanxi Province, China

<sup>2</sup>First Affiliated Hospital of Northwest University, Northwest University, Xi'an 710002, Shaanxi Province, China

<sup>3</sup>Shaanxi Institute of Ophthalmology, Xi'an 710002, Shaanxi Province, China

**Correspondence to:** Hui-Qin Lu. Department of Ophthalmology, Xi'an No.1 Hospital, Xi'an 710002, Shaanxi Province, China. 13389255280@163.com

Received: 2023-01-15 Accepted: 2023-07-12

## Abstract

• **AIM:** To evaluate the clinical efficacy and systemic safety profile of conbercept in clinical practice on vascular endothelial growth factor (VEGF)-A, VEGF-B, and placental growth factor (PLGF) levels after intravitreal injections for the neovascular age-related macular degeneration (AMD).

• **METHODS:** Thirty-five patients (35 eyes) with neovascular AMD received intravitreal injections of conbercept treatment with *pro re nata* protocol. Best-corrected visual acuity (BCVA) and central retinal thickness (CRT) were detected before the intravitreal injection and at 1, 3, and 12mo after conbercept treatment. The levels of serum VEGF-A, VEGF-B, and PLGF were measured by enzyme-linked immunosorbent assay before the injection and 1 and 12mo after conbercept treatments.

• **RESULTS:** At baseline, the mean BCVA score was 39.89±14.64 letters. The mean BCVA scores were 51.03±15.78, 56.71±14.38, and 52.49±10.16 letters at 1, 3, and 12mo after conbercept treatment, and the BCVA improvements were all significant, respectively ( $P<0.05$ ). At baseline, the mean CRT was 436.7±141.9 μm. At 1, 3, and 12mo after conbercept treatment, the mean CRT values were 335.1±147.8, 301.1±116.5, and 312.2±98.22 μm, and the CRT improvements were all significant, respectively ( $P<0.05$ ). At baseline, 1 and 12mo after conbercept treatment, the mean levels of serum VEGF-A were 1013.8±454.3, 953.1±426.4, and 981.5±471.7 pg/mL, the mean levels of serum VEGF-B were 46.93±24.76,

42.99±19.16, and 45.32±18.76 pg/mL, the mean levels of serum PLGF at these points were 251.7±154.9, 241.3±166.7, and 245.6±147.2 pg/mL, respectively. Compared with the baseline, the levels of serum VEGF-A, VEGF-B, and PLGF did not significantly change at 1 and 12mo after conbercept treatment, respectively ( $P>0.05$ ).

• **CONCLUSION:** Conbercept intravitreal injection leads to BCVA and CRT improvement, however, it does not significantly affect systemic serum VEGF-A, VEGF-B, and PLGF levels at 1 and 12mo after intravitreal injection treating neovascular AMD.

• **KEYWORDS:** conbercept; vascular endothelial growth factor; placental growth factor; age-related macular degeneration

**DOI:10.18240/ijo.2023.09.16**

**Citation:** Chen XD, Li C, Ding GL, Suo Y, Zhu YS, Lu HQ. Clinical efficacy and changes of serum VEGF-A, VEGF-B, and PLGF after conbercept treating neovascular age-related macular degeneration. *Int J Ophthalmol* 2023;16(9):1489-1495

## INTRODUCTION

Age-related macular degeneration (AMD) is a leading macular disease that causes blindness in the elderly (over 55 years old) populations in developed countries<sup>[1-3]</sup>. The AMD is usually divided into non-neovascular AMD and neovascular AMD<sup>[4-5]</sup>. The neovascular AMD is only about 10% of all AMD cases, but it accounts for 90% of severe visual impairment in AMD<sup>[6]</sup>. Although the pathogenesis of AMD is not thoroughly understood, vascular endothelial growth factor (VEGF) has been known as a key factor that induces choroidal neovascularization (CNV)<sup>[7]</sup>. Currently, the anti-VEGF agent intravitreal injection was proved to be an effective method to treat neovascular AMD. There are two types of anti-VEGF drugs commonly used in clinics: monoclonal drugs, such as bevacizumab and ranibizumab, and fusion protein drugs, such as aflibercept and conbercept<sup>[8-9]</sup>. The anti-VEGF drugs were injected into the vitreous cavity to assure its anti-VEGF effectiveness were limited to the eyeball. However, there are

some studies showed that intravitreal injection caused to anti-VEGF agent be absorbed into the systemic circulation and caused some potential adverse events<sup>[10-11]</sup>.

Conbercept is an anti-VEGF agent which was manufactured by Chengdu Kanghong Biotech Co., Ltd., China. It is an engineered fusion protein yielded by the gene recombination of VEGF receptor (VEGFR)-1 and VEGFR-2 with the Fc fragment of human immunoglobulin, which can bind VEGF-A, VEGF-B, and placental growth factor (PLGF) and has successfully improved best-corrected visual acuity (BCVA) and central retinal thickness (CRT) in the patients with CNV<sup>[12-14]</sup>. It was reported that conbercept significantly decreased serum VEGF levels at one day and one week after treatment, and this side effect did not sustain for one month<sup>[15]</sup>. However, to date, the long-term alterations of systemic levels of VEGF-A, VEGF-B, and PLGF in patients treated with conbercept are not fully clear.

This present study mainly evaluated the clinical effects of intravitreal conbercept injection and changes in serum levels of VEGF-A, VEGF-B, and PLGF in neovascular AMD at 1 and 12mo after multiple conbercept treatments.

## SUBJECTS AND METHODS

**Ethical Approval** The procedures of this study were approved by the Ethics Committees of Xi'an No.1 Hospital (2021-01) and conformed to the tenets of the World Medical Association's Declaration of Helsinki. This study was registered in the Chinese Clinical Trial Registry (ChiCTR2100053627). All enrolled patients obtained informed consent.

**Participants** Before participation in study, all enrolled patients followed inclusion criteria<sup>[16-17]</sup>: being at least 50 years old and possessing a BCVA letter score between 73 and 19 letters (20/40 Snellen equivalent and 20/400 Snellen equivalent). Patients would be excluded with any of the following significant ocular clinical signs: macular atrophy or foveal scarring, anti-VEGF or steroids treatment within recent six months, laser therapy or ocular surgery such as laser photocoagulation, photodynamic therapy, macular surgery, vitrectomy, cataract surgery, *etc.* Patients with ocular active inflammation or infection and the patients with systemic disease such as uncontrolled diabetes mellitus and hypertension, renal failure, myocardial infarction, cerebral vascular accident within recent six months were also excluded from the study.

**Best-Corrected Vision Acuity** The BCVA was evaluated at baseline and at 1, 3, and 12mo after the intravitreal injection. The BCVA was assessed by The Early Treatment Diabetic Retinopathy Study (ETDRS) vision acuity chart at four meters of distance<sup>[13]</sup>.

**Central Retinal Thickness** The CRT between the macular fovea to the Bruch membrane was detected by optical coherence tomography (OCT; Heidelberg, Germany) at

baseline and 1, 3, and 12mo after conbercept treatment. CRT was measured by using the active eye tracking and automatic follow-up scan function and manual caliper of OCT.

**Enzyme-Linked Immunosorbent Assay** The vein blood specimens from patients were obtained just before the first injection and at 1 and 12mo after the conbercept intravitreal injection. The serums were extracted and centrifuged from all blood specimens at room temperature and then were immediately stored at -80°C until assay. Serum VEGF-A, VEGF-B, and PLGF concentrations were determined by VEGF-A (Product No.SEA143Hu), VEGF-B (Product No.SEA144Hu), and PLGF (Product No.SEA114Hu) enzyme-linked immunosorbent assay (ELISA) kits (Cloud-Clone Corp., Wuhan, China) according to the instructions given by the manufacturer. The detection limit of these three ELISA kits is 15.6–1000 pg/mL in the instruction manual. Briefly, the standards or samples were set and tested in 96-well microplates. The 100 µL of standards or samples were added to each well and mixed by gently shaking. Then, at 37°C, the plate was incubated for 90min. The supernatant was removed from the wells and biotinylated antibody working solutions (100 µL) were added to each well. The standards and samples were incubated for 60min at 37°C and washed with wash buffer for three times. Next step, 90 µL of substrate solutions were added to each well and incubated at 37°C for 15min. Next, 50 µL of stop solutions were added into each well. Finally, the absorbance value was detected with a microplate reader at 450 nm, and the concentrations of VEGF-A, VEGF-B, and PLGF were calculated.

**Intravitreal Conbercept Injection** The included patients obtained intravitreal injection of conbercept for consecutive 3mo, and then *pro re nata* (PRN) treatment regimen was given if the following changes were observed in subsequent visits: a loss of five letters or more, fresh hemorrhage in macular area, an increase of subretinal or interretinal fluid, an increase in CRT of at least 50 µm, or an increase of leakage area on fluorescein angiography. When the eye had been prepared, 0.05 mL of conbercept (0.5 mg) intravitreal injection was carried out through the pars plana located 3.5 mm behind the corneal limbus.

**Statistical Analysis** All data were presented as mean±standard deviation (SD). All statistical analysis was executed using Graph Pad Prism 9. The data differences between the baseline and post-conbercept treatment were analyzed by one-way ANOVA and Tukey test.  $P < 0.05$  was statistically significant.

## RESULTS

The clinical characteristics of all participants in the study are shown in the Table 1. Thirty-five Chinese patients, or 35 eyes, with clinically significant neovascular AMD underwent intravitreal injection of conbercept in the present study. There

**Table 1 Characteristics of conbercept intravitreal injection of all participants**

Characteristics	Data
No. of patient	35
Gender	
Male	18
Female	17
Age (y)	66.9±8.5
BCVA (letters)	39.89±14.64
CRT (μm)	436.7±141.9
Injection times	
4	15
5	11
6	7
7	2

BCVA: Best-corrected vision acuity; CRT: Central retinal thickness.

were eighteen men (51.4%) and seventeen women (48.6%) and the mean ages of the patients were 66.9±8.5y. The mean ETDRS BCVA was 39.89±14.64 letters. The mean CRT at baseline was 436.7±141.9 μm. All patients received injections more than three times: 15 patients were injected 4 times, 11 patients were injected 5 times, 7 patients were injected 6 times, and two patients were injected 7 times. The average number of conbercept injections in 12mo was 4.9.

The BCVA was significantly improved after the intravitreal conbercept injection compared with that at baseline. At baseline, the mean BCVA score was 39.89±14.64 letters. At 1, 3, and 12mo after intravitreal conbercept injection, the mean BCVA scores were 51.03±15.78, 56.71±14.38, and 52.49±10.16 letters, respectively ( $P<0.05$ ). Compared with baseline, the mean improvements of BCVA were 11.1, 16.8, and 12.6 letters at 1, 3, and 12mo, respectively ( $P<0.05$ ; Figure 1).

Compared with baseline, the mean CRT measured was improved at 1, 3, and 12mo after conbercept injection as shown in a series of OCT images of a typical neovascular AMD case (Figure 2). At baseline, the mean CRT was 436.7±141.9 μm. At 1mo after injection, the mean CRT was 335.1±147.8 μm. Compared with baseline, the mean improvements of CRT were about 101.6 μm ( $P<0.05$ ). At 3mo after injection, the mean CRT was 301.1±116.5 μm. Compared with baseline, the mean improvements of CRT were 135.5 μm ( $P<0.05$ ). At 12mo after injection, the mean CRT was 312.2±98.22 μm. Compared with baseline, the mean improvements of CRT were 124.5 μm ( $P<0.05$ ; Figure 3).

Serum VEGF-A, VEGF-B, and PLGF levels were detected by ELISA at baseline and at 1 and 12mo after intravitreal conbercept injection. The mean levels of serum VEGF-A at these points were 1013.8±454.3, 953.1±426.4, and 981.5±471.7 pg/mL, respectively. The mean levels of serum

VEGF-B at these points were 46.93±24.76, 42.99±19.16, and 45.32±18.76 pg/mL, respectively. The mean levels of serum PLGF at these points were 251.7±154.9, 241.3±166.7, and 245.6±147.2 pg/mL, respectively. Compared with the baseline, the levels of serum VEGF-A, VEGF-B, and PLGF did not significantly change at 1 and 12mo after conbercept treatment, respectively ( $P>0.05$ ; Figure 4).

## DISCUSSION

In this present study, the effects of intravitreal conbercept injection and changes in serum VEGF-A, VEGF-B, and PLGF levels were observed in neovascular AMD in the real world. Our results showed that intravitreal conbercept injection significantly improved visual acuity and CRT, and no serious adverse reactions and complications were observed in patients with neovascular AMD. Since conbercept was authorized by China's Food and Drug Administration to treat AMD in 2013, it has more successfully achieved visual and anatomic benefits through intravitreal injections<sup>[18]</sup>. The phase 1 clinical trial of conbercept (KH902) in the treatment of exudative AMD showed that there was no dose-limiting toxicity or serious drug-related adverse events in 28 exudative AMD subjects in all treatment groups, and no conbercept antibodies were found in serum. On day 42 after injection with conbercept, BCVA increased by 19.6 letters on average, approximately 57% of subjects improved visual acuity by 15 letters or more, macular CRT decreased by 77.2 μm from baseline, and CNV area decreased by 12.6% on average<sup>[19]</sup>. The AURORA study results showed that the BCVA at 3mo was the same as or better than at 12mo in the 0.5 and 2.0 mg conbercept groups in neovascular AMD patients. During follow-up 12mo, repeated intravitreal conbercept injections were well-tolerated in these AMD patients<sup>[16]</sup>. The PHOENIX study, a recent clinical trial of conbercept treating the neovascular AMD, showed that 3 initial monthly injections of conbercept followed by quarterly treatments were effective to the neovascular AMD<sup>[17]</sup>. Recently, some researcher reported, compared to ranibizumab, the conbercept has similar safety and efficacy for the treating neovascular AMD<sup>[20]</sup>. All the above studies suggested that conbercept has a good therapeutic effect on neovascular AMD.

Conbercept consists of the immunoglobulin-like region two of human VEGFR1 and the immunoglobulin-like regions three and four of human VEGFR2 fused with human immunoglobulin Fc fragments, which can bind to VEGF-A, VEGF-B, and PLGF. VEGF-A is the key factor in vasculogenesis and angiogenesis and induces cellular chemotaxis, the expression of plasminogen activators, and collagenases in endothelial cells<sup>[21-22]</sup>. VEGF-B does not directly promote angiogenesis under normal conditions but can influence vascular growth indirectly by affecting VEGFA

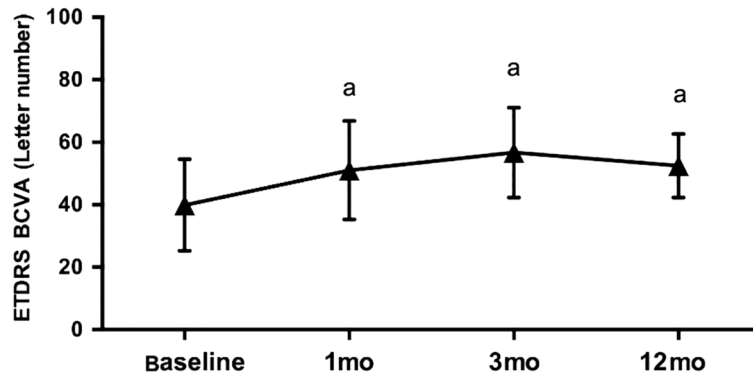


Figure 1 The BCVA of 35 eyes at baseline and at 1, 3, and 12mo after intravitreal conbercept injection followed by a 3+PRN protocol <sup>a</sup> $P < 0.05$  vs baseline. BCVA: Best-corrected visual acuity; PRN: *Pro re nata*.

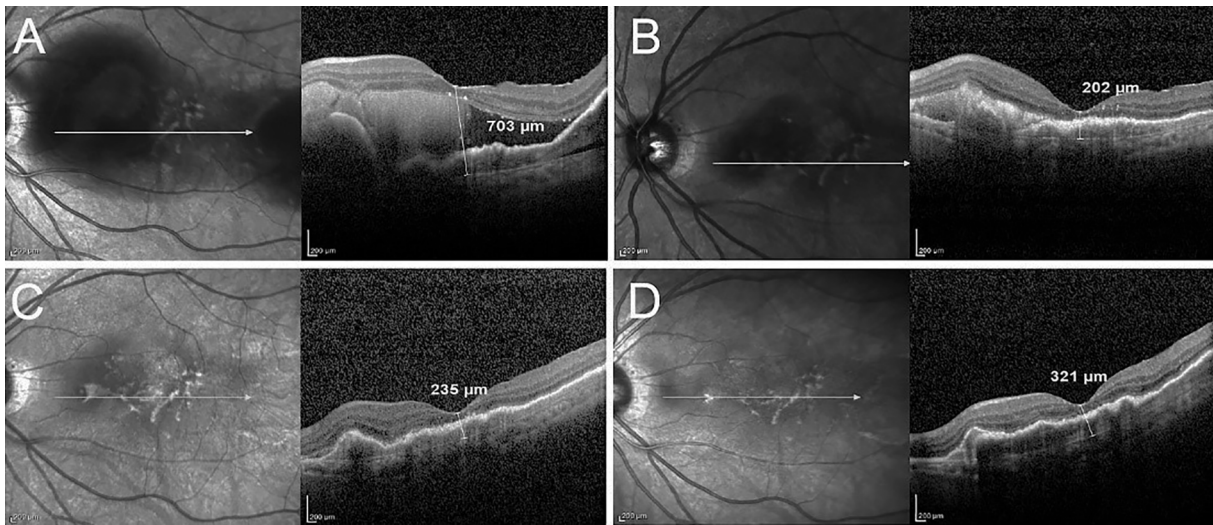


Figure 2 A series of OCT images of a typical neovascular age-related macular degeneration patient at baseline and after intravitreal conbercept injection. Horizontal OCT showed CRT at baseline (A), 1<sup>st</sup> month (B), 3<sup>rd</sup> month (C), and 12<sup>th</sup> month (D) after conbercept injection. OCT: Optical coherence tomography; CRT: Central retinal thickness.

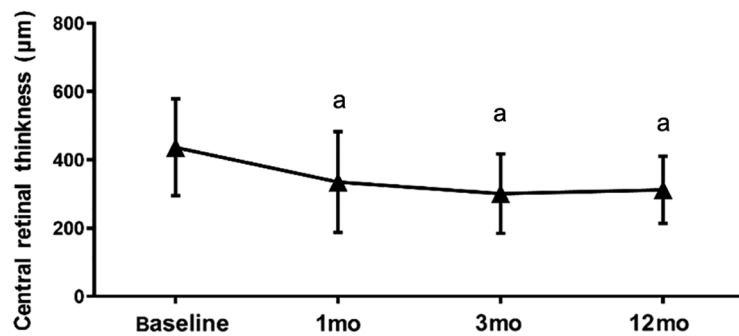


Figure 3 The CRT of 35 eyes at baseline and at 1, 3, and 12mo after intravitreal conbercept injection followed by a 3+PRN protocol <sup>a</sup> $P < 0.05$  vs baseline. CRT: Central retinal thickness; PRN: *Pro re nata*.

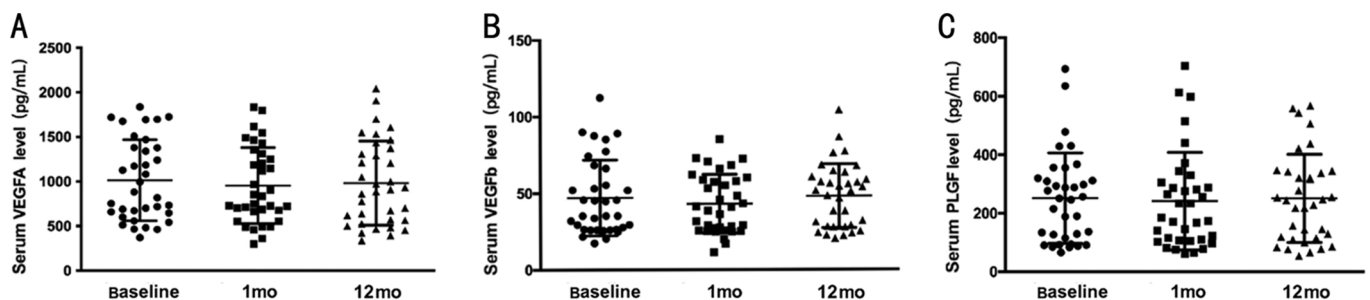


Figure 4 The levels of serum VEGF-A, VEGF-B, and PLGF of 35 eyes at baseline and 1 and 12mo after intravitreal conbercept injection followed by a 3+PRN protocol. VEGF: Vascular endothelial growth factor; PRN: *Pro re nata*; PLGF: Placental growth factor.

action<sup>[23]</sup>. PLGF can also stimulate vessel growth and modulate vascular cell responses that are distinct from VEGF-A<sup>[24-25]</sup>. In previous reports, the median of baseline plasma VEGF concentration was 61.0 pg/mL in healthy patients without chorioretinal diseases<sup>[26]</sup>, and serum VEGF concentrations in AMD patients were 323.64 pg/mL and serum VEGF concentrations in control subjects were 392.94 pg/mL<sup>[27]</sup>. Serum levels of VEGF-B in retinal neovascular and non-neovascular diseases were 30.4 and 50.4 pg/mL, respectively<sup>[28]</sup>. The mean concentration value of plasma PLGF of normal women was 614.42±34.79 pg/mL during antepartum<sup>[29]</sup>. Although VEGF is viewed as a pathological factor and plays a prominent role in the occurrence of neovascular AMD, it is also a master regulator of vascular development and homeostasis, which can activate receptors on vascular endothelial cells to promote vascular endothelial cell survival, proliferation, and permeability<sup>[30]</sup>. Some researchers thought that the reduction of VEGF in the blood caused by anti-VEGF agents might be an inadvertent off-target effect that could raise concerns about safety. Therefore, we should pay close attention to systemic risks of off-target by intravitreal anti-VEGF.

Currently, optimized administration regimens commonly used in anti-VEGF therapy include a “PRN” and a “treat and extend” (T&E) protocol. These two regimens are personalized anti-VEGF treatment approach, which have the advantage of reducing the clinical workload and the number of follow-up visits, whereas it is unclear whether repeated multiple intravitreal injections cause anti-VEGF drug uptake into the systemic circulation. In our present study, we found the levels of serum VEGF-A, VEGF-B, and PLGF did not significantly decline at 1mo and 12mo after intravitreal conbercept injection by 3+PRN regimen in patients with neovascular AMD. This suggests that long-term and frequent intravitreal injection of conbercept has no significant effect on systemic VEGF-A, VEGF-B, and PLGF levels. However, some studies showed that ranibizumab may decrease systemic VEGF levels on a pro re nata regimen, and bevacizumab can significantly reduce the VEGF levels in the blood plasma for up to one month in patients with diabetic macular edema or AMD<sup>[31-32]</sup>. Some researchers have reported that the level of VEGF protein in serum decreased significantly at the first day and first week after intravitreal conbercept injection, but this effect did not last until the first month after treatment. In contrast, ranibizumab did not significantly affect serum VEGF concentration<sup>[15]</sup>. Some previous reports also showed that intravitreal aflibercept injection significantly decreased serum and plasma VEGF concentrations at one week and one month after injection, but this decline was not sustained two months after injection<sup>[33]</sup>. Other researcher reported that the systemic VEGF levels were significantly reduced throughout the observational period of

4wk after intravitreal aflibercept injection, but intravitreal ranibizumab injection was not observed significant systemic effects of plasma VEGF<sup>[26]</sup>. Our data showed that the average levels of serum VEGF-A, VEGF-B, and PLGF at 1mo after conbercept treatment are all lower than baseline, whereas this decrease was not significant difference. Therefore, these studies suggested that intravitreal injection of fusion protein anti-VEGF drugs, such as conbercept or aflibercept, might decrease systemic VEGF levels in a shortest period after treatment, even though they did not affect systemic VEGF levels for more than one month after treatment. For anti-VEGF agents, pharmacokinetic parameters are important for estimation of local effect and systemic off-target effect. Current data about half-life data on anti-VEGF agents after intravitreal injection are limited and based on animal studies. It was reported that the vitreous half-life of aflibercept was 3.63d in rabbits, while ranibizumab was 3d in primates and 2.88d in Dutch-belted rabbits<sup>[34]</sup>. Some studies have shown that the IC50 value (half inhibitory concentration) of conbercept was similar to aflibercept and was almost 38 to 48 times greater than bevacizumab and ranibizumab<sup>[15,35-36]</sup>. Considering that a decline in systemic VEGF levels might cause the possibility of unexpected systemic effect, we should be aware of potential systemic risks caused by intravitreal anti-VEGF agents in future treatment.

In conclusion, conbercept significantly improved BCVA and CRT and did not significantly affect serum VEGF-A, VEGF-B, and PLGF levels after intravitreal injection. Due to the limitations of the small population sample size in our present study, in the future, we should consider planning larger sample studies about changes in systemic VEGF-A, VEGF-B, and PLGF after intravitreal conbercept injection.

#### ACKNOWLEDGEMENTS

**Foundations:** Supported by the Bethune Lumitin Research Funding for the young and middle-aged Ophthalmologists, China (No.BJ-LM202009); Shaanxi Province Key Research and Development Project, China (No.2022SF-312).

**Conflicts of Interest:** Chen XD, None; Li C, None; Ding GL, None; Suo Y, None; Zhu YS, None; Lu HQ, None.

#### REFERENCES

- 1 Deng Y, Qiao L, Du M, Qu C, Wan L, Li J, Huang L. Age-related macular degeneration: epidemiology, genetics, pathophysiology, diagnosis, and targeted therapy. *Genes Dis* 2022;9(1):62-79.
- 2 Fleckenstein M, Keenan TDL, Guymer RH, et al. Age-related macular degeneration. *Nat Rev Dis Primers* 2021;7(1):31.
- 3 Guymer RH, Campbell TG. Age-related macular degeneration. *Lancet* 2023;401(10386):1459-1472.
- 4 Heloterä H, Kaarniranta K. A linkage between angiogenesis and inflammation in neovascular age-related macular degeneration. *Cells* 2022;11(21):3453.

- 5 Handa JT, Bowes Rickman C, Dick AD, *et al.* A systems biology approach towards understanding and treating non-neovascular age-related macular degeneration. *Nat Commun* 2019;10(1):3347.
- 6 Jager RD, Mieler WF, Miller JW. Age-related macular degeneration. *N Engl J Med* 2008;358(24):2606-2617.
- 7 Yeo NJY, Chan EJJ, Cheung C. Choroidal neovascularization: mechanisms of endothelial dysfunction. *Front Pharmacol* 2019;10:1363.
- 8 Khanna S, Komati R, Eichenbaum DA, *et al.* Current and upcoming anti-VEGF therapies and dosing strategies for the treatment of neovascular AMD: a comparative review. *BMJ Open Ophthalmol* 2019;4(1):e000398.
- 9 Arrigo A, Bandello F. Molecular features of classic retinal drugs, retinal therapeutic targets and emerging treatments. *Pharmaceutics* 2021;13(7):1102.
- 10 Reibaldi M, Fallico M, Avitabile T, *et al.* Frequency of intravitreal anti-VEGF injections and risk of death. *Ophthalmol Retina* 2022;6(5):369-376.
- 11 Zehden JA, Mortensen XM, Reddy A, Zhang AY. Systemic and ocular adverse events with intravitreal anti-VEGF therapy used in the treatment of diabetic retinopathy: a review. *Curr Diab Rep* 2022;22(10):525-536.
- 12 Ferro Desideri L, Traverso CE, Nicolo M. An update on conbercept to treat wet age-related macular degeneration. *Drugs Today* 2020;56(5):311.
- 13 Gao L, Liu J, Zhang P, Ma JH, Wang H. Clinical outcomes of 1+PRN and 3+Q3M regimens of intravitreal conbercept injection for exudative age-related macular degeneration. *Sci Rep* 2020;10:8010.
- 14 Zhang S, Chen FF, Zhang WW, Liu YJ, Chen H, Xie ZG. Long-term clinical effects of intravitreal injections of conbercept for the treatment of choroidal neovascularization in patients with pathological myopia. *Int J Ophthalmol* 2022;15(12):1971-1977.
- 15 Jin EZ, Bai YJ, Luo L, *et al.* Serum levels of vascular endothelial growth factor before and after intravitreal injection of ranibizumab or conbercept for neovascular age-related macular degeneration. *Retina* 2017;37(5):971-977.
- 16 Li XX, Xu GZ, Wang YS, *et al.* Safety and efficacy of conbercept in neovascular age-related macular degeneration. *Ophthalmology* 2014;121(9):1740-1747.
- 17 Călugăru D, Călugăru M. Conbercept for treatment of neovascular age-related macular degeneration: results of the randomized phase 3 phoenix study. *Am J Ophthalmol* 2019;198:262-263.
- 18 Sun XD, Lu XM. Profile of conbercept in the treatment of neovascular age-related macular degeneration. *Drug Des Dev Ther* 2015:2311.
- 19 Zhang M, Zhang JJ, Yan M, *et al.* A phase 1 study of KH902, a vascular endothelial growth factor receptor decoy, for exudative age-related macular degeneration. *Ophthalmology* 2011;118(4):672-678.
- 20 Wang X, Yu CF, Yang JS, *et al.* Comparison of efficacy and safety between conbercept and ranibizumab in neovascular age-related macular degeneration: a meta-analysis of randomized controlled trials. *Ophthalmic Res* 2022;65(2):140-151.
- 21 Moens S, Goveia J, Stapor PC, Cantelmo AR, Carmeliet P. The multifaceted activity of VEGF in angiogenesis -implications for therapy responses. *Cytokine Growth Factor Rev* 2014;25(4):473-482.
- 22 Varricchi G, Loffredo S, Galdiero MR, *et al.* Innate effector cells in angiogenesis and lymphangiogenesis. *Curr Opin Immunol* 2018;53:152-160.
- 23 Lal N, Puri K, Rodrigues B. Vascular endothelial growth factor B and its signaling. *Front Cardiovasc Med* 2018;5:39.
- 24 Uemura A, Fruttiger M, D'Amore PA, *et al.* VEGFR1 signaling in retinal angiogenesis and microinflammation. *Prog Retin Eye Res* 2021;84:100954.
- 25 Van Bergen T, Etienne I, Cunningham F, *et al.* The role of placental growth factor (PlGF) and its receptor system in retinal vascular diseases. *Prog Retin Eye Res* 2019;69:116-136.
- 26 Zehetner C, Kralinger MT, Modi YS, *et al.* Systemic levels of vascular endothelial growth factor before and after intravitreal injection of aflibercept or ranibizumab in patients with age-related macular degeneration: a randomised, prospective trial. *Acta Ophthalmol* 2015;93(2):e154-e159.
- 27 Gu XY, Yu XB, Dai H. Intravitreal injection of ranibizumab for treatment of age-related macular degeneration: effects on serum VEGF concentration. *Curr Eye Res* 2014;39(5):518-521.
- 28 Mesquita J, Castro-de-Sousa JP, Vaz-Pereira S, Neves A, Passarinha LA, Tomaz CT. Evaluation of the growth factors VEGF-A and VEGF-B in the vitreous and serum of patients with macular and retinal vascular diseases. *Growth Factors* 2018;36(1-2):48-57.
- 29 Jeevaratnam K, Nadarajah VD, Judson JP, *et al.* Periodic assessment of plasma sFlt-1 and PlGF concentrations and its association with placental morphometry in gestational hypertension (GH) - a prospective follow-up study. *BMC Pregnancy Childbirth* 2010;10:58.
- 30 Rattner A, Williams J, Nathans J. Roles of HIFs and VEGF in angiogenesis in the retina and brain. *J Clin Invest* 2019;129(9):3807-3820.
- 31 Enders P, Muether PS, Hermann M, Ristau T, Fauser S. Long-term alterations of systemic vascular endothelial growth factor levels in patients treated with ranibizumab for age-related macular degeneration. *Retina* 2015;35(3):454-458.
- 32 Zehetner C, Kirchmair R, Huber S, *et al.* Plasma levels of vascular endothelial growth factor before and after intravitreal injection of bevacizumab, ranibizumab and pegaptanib in patients with age-related macular degeneration, and in patients with diabetic macular oedema. *Br J Ophthalmol* 2013;97(4):454-459.
- 33 Wang X, Sawada T, Sawada O, *et al.* Serum and plasma vascular endothelial growth factor concentrations before and after intravitreal injection of aflibercept or ranibizumab for age-related macular degeneration. *Am J Ophthalmol* 2014;158(4):738-744.
- 34 Kaiser SM, Arepalli S, Ehlers JP. Current and future anti-VEGF agents for neovascular age-related macular degeneration. *J Exp Pharmacol* 2021;13:905-912.
- 35 Zhang M, Yu DC, Yang C, *et al.* The pharmacology study of a new

recombinant human VEGF receptor-fc fusion protein on experimental choroidal neovascularization. *Pharm Res* 2009;26(1):204-210.  
36 Papadopoulos N, Martin J, Ruan Q, *et al.* Binding and neutralization

of vascular endothelial growth factor (VEGF) and related ligands by VEGF Trap, ranibizumab and bevacizumab. *Angiogenesis* 2012;15(2):171-185.

---

## CORRIGENDUM

### Posterior scleral application of a mitomycin C-soaked sponge during trabeculectomy

*Kun Hu, Yun-He Song, Feng-Bin Lin, Ying-Zhe Zhang, Ling Jin, Meng-Yin Liang, Robert N. Weinreb, Xiu-Lan Zhang*  
(*Int J Ophthalmol* 2023;16(7):1071-1077, doi:10.18240/ijo.2023.07.11)

The authors would like to make the following change to the above article:

“MMC was administered as a subconjunctival injection 0.02 mg/mL and 0.1 mL” on page 1073 should be changed to “MMC was administered as a subconjunctival injection 0.2 mg/mL and 0.1 mL”.

The authors apologize for any inconvenience caused by this error.

### Intracameral 5-fluorouracil and viscous dispersive viscoelastic for diffuse epithelial downgrowth management in aphakia

*Santiago Montolio-Marzo, Ester Fernández-López, Jose Vicente Piá-Ludeña, Juan María Davó-Cabrera, Enrique Antonio Alfonso-Muñoz, Cristina Peris-Martínez*  
(*Int J Ophthalmol* 2020;13(5):845-847, doi:10.18240/ijo.2020.05.23)

The authors would like to make the following change to the above article:

“Then the anterior chamber was irrigated with 5-fluorouracil (5-FU) in a concentration of 1000 mg/0.1 mL in 0.1 mL of a viscous dispersive viscoelastic (DisCoVisc<sup>®</sup>, Alcon, USA).” on page 845 should be changed to “Then the anterior chamber was irrigated with 5-fluorouracil (5-FU) in a concentration of 1000 µg/0.1 mL in 0.1 mL of a viscous dispersive viscoelastic (DisCoVisc<sup>®</sup>, Alcon, USA).”

The authors apologize for any inconvenience caused by this error.