

Visualized analysis of research on myopic traction maculopathy based on CiteSpace

Heng-Di Zhang¹, Ling Zhang², Fei Han¹, Ning Lin³, Wei Jiang¹

¹Department of Ophthalmology, the General Hospital of Western Theater Command, PLA, Chengdu 610083, Sichuan Province, China

²Department of Oncology, the General Hospital of Western Theater Command, PLA, Chengdu 610083, Sichuan Province, China

³Department of Clinical Nutrition, the General Hospital of Western Theater Command, PLA, Chengdu 610083, Sichuan Province, China

Correspondence to: Heng-Di Zhang. 270# Rongdu Avenue, the General Hospital of Western Theater Command, PLA, Chengdu 610083, Sichuan Province, China. 93428326@qq.com

Received: 2023-03-05 Accepted: 2023-08-01

Abstract

● **AIM:** To analyze the global scientific output concerning myopic traction maculopathy (MTM) and to summarize the research frontiers and hot topics of MTM related researches.

● **METHODS:** Data were collected for bibliometric and visualization analyses from Web of Science (WOS) Core Collection. Exported records were analyzed for titles, publication years, research institutions, journal names, authors, keywords, and abstracts using CiteSpace software version 6.1.

● **RESULTS:** A total of 839 related studies were analyzed, the publication volume increased annually, with Asia the most active region of MTM research. Optical coherence tomography angiography, optical coherence tomography, macular hole, high myopia, macular buckling were identified as the focus of the current research. Progression, association, classification and shape were identified as the major research frontiers.

● **CONCLUSION:** MTM is a major cause of visual loss in pathological myopic eyes. During the preceding 17y, the number of annual publications in MTM research increased gradually. Studies on the progression nature of MTM, genome-wide association study and proper classification of MTM might still be the frontiers of MTM researches.

● **KEYWORDS:** myopic traction maculopathy; bibliometric analysis; CiteSpace

DOI:10.18240/ijo.2023.12.26

Citation: Zhang HD, Zhang L, Han F, Lin N, Jiang W. Visualized analysis of research on myopic traction maculopathy based on CiteSpace. *Int J Ophthalmol* 2023;16(12):2117-2124

INTRODUCTION

Myopic traction maculopathy (MTM) refers to a spectrum of sight threatening diseases including retinoschisis/maculoschisis/foveoschisis, foveal/retinal detachment, lamellar macular holes and full-thickness macular holes with or without retinal detachment (MHRD)^[1]. MTM is a major cause of blindness in pathologic myopia (PM). Up to 35% of pathologic myopes were reported to be affected by MTM^[2]. Considering the threat of MTM and PM to public health (7% of the Western population and 12%–27% of the Asian population suffered from visual disability caused by PM)^[3], it is important to understand MTM and its associations. Various studies have been published in this area, such as surgical approaches aiming at resolving tangential and perpendicular traction force, as well as new classifications based on emerging detection technology, but controversy and uncertainties still remain. Therefore, visual analysis research of this field is valuable in providing an overview and generating a more comprehensive understanding of MTM research about the achievements and future research trends. CiteSpace is a widely used software which provides insights into research areas *via* analyzing co-cited references, co-occurrence keywords and other information based on bibliographic records from the Web of Science (WOS). In this study, we aimed at investigating scientific hotspots, research trends, and frontiers in MTM research based on CiteSpace from the WOS database.

MATERIALS AND METHODS

Data Acquisition Data were collected for bibliometric and visualization analyses from WOS Core Collection. We used “myopic traction maculopathy”, “myopic macular schisis”, “myopic retinoschisis”, and “myopic macular hole” as the search terms to retrieve MTM-related studies. Articles published between 2005 to 2022 were retrieved. Document types were restricted to articles and reviews, without language or data category restrictions. After removing irrelevant and

duplicate documents using CiteSpace, a total of 839 related studies were retrieved finally.

Research Methods Exported records were analyzed for titles, publication years, research institutions, journal names, authors, keywords and abstracts. Data were downloaded from WOS and 500 pieces of data as one file were imported into CiteSpace software version 6.1 one by one for quantitative and qualitative analyses.

Parameter Settings Time-slicing was set between 2005 and 2022 (1y per slice). The co-occurrence of keywords and co-cited reference were selected to generate a visualized knowledge network for analysis. The threshold (top N per slice) was set to 50, and the critical path (Pathfinder) and pruning graph (Pruning Sliced Networks) were selected as the pruning options. Nodes and links were used to generate visualization knowledge graphs. Each node in the graph represented an element to be analyzed, such as a cited journal, an institution or an author. Different colors of the node correspond to different years, and the size of the node represented the frequency of the citation. The links between nodes represented the co-occurrence or co-citation relationship. The thickness of the linking lines represented the strength of the relationship, and the color corresponded to the first co-citation or co-occurrence time of nodes. Cool colors indicate earlier years and warm colors indicate more recent years. Nodes with high betweenness centrality (>0.1 , node presented with purple rings on the outer circle) were usually considered turning points or pivotal points in a field.

RESULTS

Articles Published in MTM-Related Research Altogether 903 MTM-related publications were retrieved. After preprocessed by CiteSpace software, 64 literature records unrelated to the subject were excluded, and 839 articles were finally included, among which 734 were articles and 105 were reviews. The annual number of publications increased from 1 in 2005 to 106 in 2022. The average annual number of published articles was 46 (Figure 1).

Analysis of Journals and Co-Cited Journals The 159 journals were involved in MTM-related research area after statistical analysis, from which the top five journals were screened out. The highest impact factor of the related journal was 36.61 while the average impact factor was 3.68, suggesting that MTM research was a highly topical subject area. Research results for MTM were mainly distributed in the ‘Ophthalmology’ and ‘Medicine general internal’ areas. Co-cited journals were those cited together by other researchers, and co-citation analysis indicated the distribution of key knowledge sources in the MTM research field. The most frequently cited journal was *American Journal of Ophthalmology*, followed by *Ophthalmology*, while *Biomaterial* ranks the first in terms of centrality.

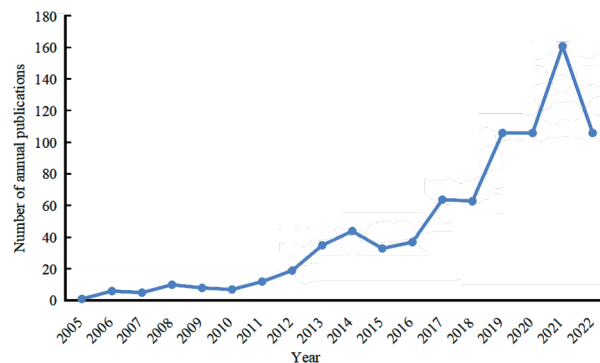


Figure 1 The number of myopic traction maculopathy research publications from 2005 to 2022.

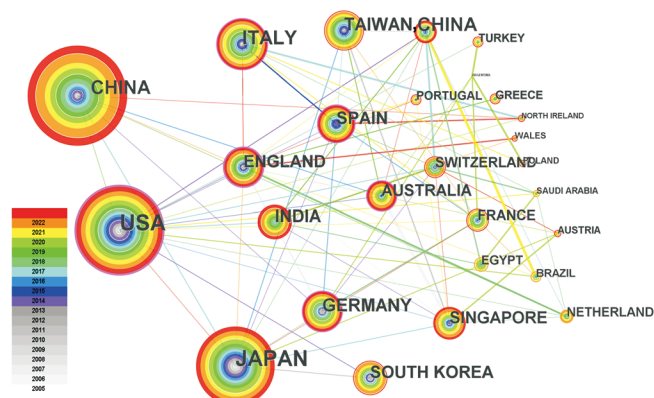


Figure 2 A country/region cooperation map related to myopic traction maculopathy research from 2005 to 2022. The nodes in the map represent countries/regions. The lines between the nodes represent cooperation relations.

Analysis of Countries/Regions The countries/regions cooperation network map is shown in Figure 2. Node number and size correspond to the publications volume generated by countries/regions, and the thickness of connective lines between nodes indicated the strength of cooperation between them. MTM research outputs were mainly derived from different regions of Asia, the Americas, and Europe, which is consistent with the high morbidity of PM in these regions. Altogether 839 references were published by research groups in 52 countries, and the top five countries/regions were China, the United States, Japan, Italy, and Germany. The top five countries/regions in terms of centrality were the United States (0.40), England (0.38), Australia (0.16), Italy (0.12), and Germany (0.12). The centrality of these five countries was greater than 0.1, indicating that these countries had a certain influence in the field of MTM research. The network density was 0.1131, suggesting a weak to moderate cooperative strength between countries/regions.

Analysis of Institutions Several research institutions contributed to the study outputs of MTM, among which the Tokyo Medical and Dental University ranked first with 47 articles, followed by the Capital Medical University and Sun Yat-sen University. The top 10 institutions published 31.59% of MTM studies.

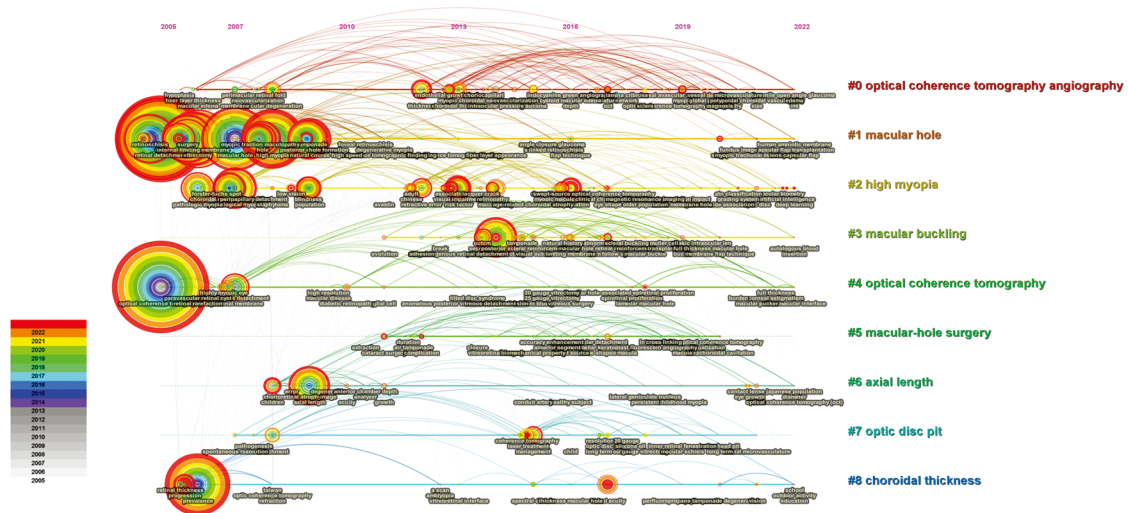


Figure 3 Timeline view of myopic traction maculopathy research hotspots.

The network density in this study was 0.0073 (>0.5 denotes a tight network), which indicated that the global MTM research cooperation network was relatively weak. The Singapore Natl Eye Center displayed a good domestic cooperation relationship. Most institutions were concentrated in universities and a few in hospitals.

Analysis of Authors and Co-Cited Authors The top 10 authors have collectively published a total of 198 papers, accounting for 24.06% of all published papers on MTM research. Ohno-Mastui K was identified as the most active author in the field of MTM research with 47 publications, followed by Chen Y, and Wang Y. Author co-citation levels were considered to reflect authors' academic influence in a certain field. Ikuno Y ranked the highest in citation counts ($n=271$), followed by Ohno-Mastui K ($n=237$), Shmada N ($n=226$), Pannozo G ($n=224$) and Spaide RF ($n=188$). The top five cited authors in centrality were Akiba J, Grossniklaus HE, Gass JDM, Curtin BJ, and Saw SM.

Analysis of Keywords Keywords cluster map consisting of 465 nodes and 2015 links were generated through cluster analysis of MTM publications (Figure 3). The top 10 keywords in frequency and centrality are shown in Table 1. As shown in Figure 3, the closer the research timeline view color is to the warm tones (orange and red), the more recent the study is. Optical coherence tomography angiography (OCTA), optical coherence tomography (OCT), macular hole, high myopia, macular buckling (MB) are the focus of the current research. Analysis of the frequency and centrality of keywords is believed to reflect the research trends. Keywords with the strongest citation burst potentially reveal hotspots and emerging trends in the research field. In recent years, progression (refers to the progression nature of pathological myopia, posterior staphyloma and MTM), association [refers to Genome-wide association study (GWAS)], classification (refers to

Keywords	Year	Strength	Begin	End	2005 - 2022
retinoschisis	2005	7.4	2005	2011	[Red bar from 2005 to 2011]
removal	2005	4.15	2005	2018	[Red bar from 2005 to 2018]
macular hole surgery	2005	3	2005	2014	[Red bar from 2005 to 2014]
traction	2005	7.71	2006	2014	[Red bar from 2006 to 2014]
retinal detachment	2005	4.58	2007	2012	[Red bar from 2007 to 2012]
macular hole	2005	3.48	2007	2009	[Red bar from 2007 to 2009]
foveal detachment	2005	6.03	2010	2016	[Red bar from 2010 to 2016]
complication	2005	3.18	2012	2017	[Red bar from 2012 to 2017]
reproducibility	2005	4.4	2013	2015	[Red bar from 2013 to 2015]
photodynamic therapy	2005	3.54	2013	2014	[Red bar from 2013 to 2014]
follow up	2005	3.27	2013	2014	[Red bar from 2013 to 2014]
myopic choroidal neovascularization	2005	2.97	2014	2014	[Red bar at 2014]
visual outcm	2005	3.91	2015	2018	[Red bar from 2015 to 2018]
coherence tomography	2005	3.42	2015	2018	[Red bar from 2015 to 2018]
pars plana vitrectomy	2005	3.82	2016	2017	[Red bar from 2016 to 2017]
gas tamponade	2005	3.62	2017	2017	[Red bar at 2017]
laser treatment	2005	3.61	2017	2020	[Red bar from 2017 to 2020]
eye shape	2005	3.4	2017	2019	[Red bar from 2017 to 2019]
lamellar macular hole	2005	3.12	2018	2019	[Red bar from 2018 to 2019]
low vision	2005	3.09	2018	2020	[Red bar from 2018 to 2020]
visual acuity	2005	4.27	2019	2020	[Red bar from 2019 to 2020]
progression	2005	7.48	2020	2022	[Red bar from 2020 to 2022]
association	2005	4.8	2020	2022	[Red bar from 2020 to 2022]
shape	2005	3.44	2020	2022	[Red bar from 2020 to 2022]
classification	2005	3.68	2021	2022	[Red bar from 2021 to 2022]

Figure 4 Top 25 keywords with the strongest citation bursts.

the classification of MTM) and shape (refers to the shape of sclera wall and posterior fundus) have become major research frontiers (Figure 4).

Co-citation relationship refers to two or more articles that are cited by one or more articles at the same time. Cluster analysis of co-cited references often reveals the common concerns of the literature and thus potentially reflects the research frontiers in a certain study field. The top five citations were articles published respectively by the following authors. Ruiz-Medrano *et al*^[4] in 2019 proposed a new classification and grading system for MTM, taking atrophic (A), tractional (T) and neovascular (N) components into accounts. Holden *et al*^[5] in 2016 published a Meta-analysis, estimating that 938 million people would be affected by high myopia by 2050.

Table 1 The top 10 keywords related to myopic traction maculopathy

Ranking	Frequency	Keywords	Ranking	Centrality	Keywords
1	249	Optical coherence tomography	1	0.14	Children
2	218	Retinal detachment	2	0.14	Axial length
3	203	Eye	3	0.13	Optical coherence tomography
4	149	Prevalence	4	0.13	Prevalence
5	139	High myopia	5	0.13	Posterior staphyloma
6	134	Macular hole	6	0.11	Progression
7	126	Vitreotomy	7	0.10	Eye
8	106	Internal limiting membrane	8	0.10	Epiretinal membrane
9	98	Retinoschisis	9	0.10	Pathological myopia
10	89	Pars plana vitrectomy	10	0.09	Choroidal neovascularization

Ohno-Matsui *et al*^[6-7] in 2016 performed a review about current understanding of the various ocular complications in high myopia, and they also proposed another classification system for myopic maculopathy in 2015, in which myopic maculopathy were divided into 5 categories, from “no myopic retinal degenerative lesion” (category 0) to “macular atrophy” (category 4). Shirohana *et al*^[8] in 2018 analyzed 729 eyes using ultrawide-field swept-source OCT, and described the association between posterior staphylomas and macular retinoschisis. They found that the epiretinal membranes or vitreoretinal attachments might act together with staphylomas as causative factors for macular retinoschisis.

DISCUSSION

MTM is a spectrum of complications of PM. PM is characterized by excessive axial elongation which causes deformations of the posterior segment of the eye and leads to visual impairment^[9]. The prevalence rate for PM is expected to keep rising in the years ahead^[10], making PM associated ocular disorders one of the leading causes of irreversible vision loss. According to our analysis, during the preceding 17y, the number of annual publications in MTM research increased gradually, indicating that MTM continues to be a major concern of global researchers.

PM often occurs in high myopes^[10]. Globally, the prevalence rate of high myopia ranges from 1% to 4.7%^[11], reaching its highest in East Asia with a prevalence rate of 2.6%–5.5%^[12]. Previous study reported that up to 35.0% high myopes suffered from MTM^[2], and East Asia is also the region with the highest incidence of MTM. This is consistent with the country/region publication volume in our analysis that Asia (mainly China and Japan) ranked the first in publication volume. The institution analysis also indicates that universities in Asia (Tokyo Medical and Dental University, Capital Medical University, and Sun Yat-sen University) were the most active institutions. The cooperation map of countries and institutions, however, showed that the global research of MTM was relatively scattered. Only a few countries and institutions had built a limited cooperative

relationship. Considering the high incidence of MTM and PM, and severe complications caused by them, it is necessary to establish closer research partnerships and improve the efficiency of international MTM research.

The research hotspots and frontiers of MTM over the past 17y were summarized based on the results of keywords cluster analyses. The progression nature of MTM, detection and examination for MTM, proper classification of MTM and surgical therapy for MTM are the major concerns in this field. MTM is increasingly recognized of its progressive nature^[13]. Shimada *et al*^[14] described the progression of MTM as an increasing of height and extent of schisis, or the development of a lamellar macular hole, full-thickness macular hole, or foveal detachment. The progression rate of MTM varies among different studies, from 11.6% to 68.9%. Shimada *et al*^[15] studied 207 eyes with MTM over a mean follow-up period of 36.2mo. MTM progression was found in 26 eyes (11.6%), and the rate was even higher in stage 4 (S4) eyes (eyes with entire macular area retinoschisis), with a reported rate of 42.9%. Gaucher *et al*^[16] found that 68.9 % (20/29 eyes) of the eyes with foveoschisis progressed with enlargement of retinal cleavage and/or visual decline, during a mean follow-up period of 31.2mo. Recently, Li *et al*^[17] reported that 43.4% MTM eyes (49/113) evolved over a mean follow-up period of 38.2mo. The mechanism of MTM progression has not yet been fully revealed, and the risk factors were reported to be age, excessive elongation of axial length (AL), posterior staphyloma, stiff internal limiting membrane (ILM), epiretinal membrane, vitreous adhesion, and chorioretinal atrophy^[18-20]. The relationship between MTM and axial elongation has long been observed^[21]. Previous studies reported that a long AL was an independent risk factor of MTM^[22]. However, an excessive elongation of AL may not be enough on its own to cause MTM. Parolini *et al*^[23] found no direct correlation between the MTM stage and AL. They further hypothesized that it was the scleral wall shape, rather than the AL itself, that influenced the MTM stage. They retrospectively reviewed 321 eyes

and identified 281 eyes with MTM and found that tractional changes were related to posterior staphyloma location and distribution. Yu *et al*^[24] also found a significant difference in eye shape between MTM and non-MTM eyes. Most MTM eyes had non-uniform expansion of the eyeball, while non-MTM eyes usually had a uniform expansion^[25]. Changes in eye shape instead of axial elongation itself, may stretch the foveal area and the surrounding retina and thus cause MTM.

Choroidal atrophy is another factor that may affect MTM progression. Choroid thickness is known to be thinner in highly myopic eyes than in normal eyes^[26]. Researchers found that choroidal thickness patterns were distinctly different in eyes with myopic maculopathy, compared with those in normal eyes and high myopia eyes with normal fundus^[27-28]. These findings indicated that the choroidal thickness was negatively correlated with severity of myopic maculopathy. The Singapore Epidemiology of Eye Diseases-2 study group reported that MTM was significantly associated with macular chorioretinal atrophy. They explained that in the areas of advanced chorioretinal atrophy, the inner retina-posterior sclera attachment was weak and traction force might facilitate the dissociation of the retinal tissue in these areas^[29]. Previous studies supported the hypothesis that choroidal atrophy might contribute greatly to the pathogenesis of myopic maculopathy. Choroid attenuation may serve as a predictor of the development of advanced myopic maculopathy in high myopia children^[30]. However, the role of the choroid in MTM has not been fully elucidated. More studies on choroid morphological changes, choroid vessels, choroidal blood flow, as well as choroid thickness changes may help to reveal the relationship between choroid and MTM.

Recently, the genetic background for PM and myopic maculopathy has been brought to forefront. Hosoda *et al*^[31] identified *CCDC102B* as a susceptibility gene for myopic maculopathy in GWAS in 2018, which was not significantly associated with myopia itself. This finding suggests that myopic maculopathy may have a different gene background from high myopia. In 2022, Kassam *et al*^[32] assessed the effectiveness of polygenic risk scores (derived from the largest GWAS of myopia in Europeans) in predicting the risk of myopic macular degeneration in a total of 5894 subjects and found that it was a valid predictor in identifying high risk population for high myopia and myopic macular detachment^[32]. These encouraging findings indicate that myopic maculopathy might be predicted and prevented, even in patients who already suffer from high myopia. The gene background of myopic maculopathy and PM remains mostly unknown. GWASs on fundus shape, staphyloma and choroid atrophy might be able to identify susceptibility genes associated with MTM, but not

with high myopia, and thus contribute to the predicting and control of the development of myopic maculopathy.

The detection and examination methods of MTM have always been evolving. MTM was extremely difficult to be observed due to limitations of fundoscopy, the high transparency nature of retina and the thinning of choroid in high myopic eyes. Therefore, MTM was widely believed to be the tractional aspect of PM for many years. However, the advent and development of OCT changed the cognition. MTM is now recognized as a single clinical disorder with a spectrum of pathological changes^[33-36]. Recent advances in OCT technology, including enhanced depth imaging OCT and swept source OCT, are able to provide high resolution images and enable researchers to obtain reliable and stable measurements of choroid^[8]. The advent of OCTA further enables authors to detect retino-choroidal capillaries blood flow impairment in a non-invasive way^[37-40]. With the help of OCT/OCTA technology, authors are able to observe early signs of MTM, which were previously difficult to detect. However, the interpretation of choroidal circulation exhibited by OCTA images remains a challenge in PM eyes. Further studies are needed to reveal the relationship of choroidal circulation and MTM pathogenesis.

MTM classification evolves with the development of new technologies. Proper classification provides guidance to the timing of intervention and treatment strategies for MTM. Shimada *et al*^[14] first divided the progression process of MTM into 4 stages, from focal irregularity of external retina (S1) to retinal detachment resulted from outer macular hole (S4). The same group in 2013 proposed a classification system defining the progression of myopic retinoschisis as 5 stages: from stage 0, no maculoschisis to S4, entire macular area schisis^[15]. Ruiz-Medrano *et al*^[4] formulated the ATN classification system based on three fundus manifestations: atrophy, traction, and neovascularization. In their system, macular tractional changes were divided into five stages: inner or/and outer foveoschisis, foveal detachment, macular hole, and retinal detachment. Recently, Parolini *et al*^[23] proposed the MTM Staging System which emphasized on the progressive nature of MTM. MTM were described as Stage 1, the inner or inner-outer maculoschisis; Stage 2, outer maculoschisis; Stage 3, maculoschisis-detachment; Stage 4 macular detachment and the disappear of schisis. Each stage was further divided into 3 patterns according to foveal profiles: intact fovea structure (stage a), fovea inner lamellar macular hole (stage b) and fovea full-thickness macular hole (stage c). Based on this classification system, the authors suggested that eyes with stages 1a and 2a MTM should be followed for 2y, while eyes in other stages and patterns should be given surgical interventions^[41].

There are two main surgical approaches in treating MTM: episcleral approach, including posterior scleral reinforcement and MB; and intraocular approach, including pars plana vitrectomy (PPV), with or without peeling of ILM, and the use of various endotamponade. Shevelev first reported transplantation of material for sclera reinforcement. Since then, many studies had published revision and modification of MB^[42]. As MB was proved to be able to compensate for the perpendicular force caused by axial elongation and posterior staphyloma, it was considered the criterion for the treatment of MHRD before 1980s^[43]. In the following years, PPV emerged to be a promising new technology as tangential and centripetal traction on vitreoretinal surface was proved to be an important factor in the pathogenesis of MTM. However, the success rate of PPV in high myopic macular detachment remains limited, with a high rate of reopen or failed macular hole, recurrence of retinal detachment and the risk of inducing iatrogenic macular hole^[44-46]. The unsatisfactory surgical results of PPV led to reconsideration of MB^[47]. Researchers reported that MB had a higher reattachment rate in treating the myopic MHRD compared with PPV^[48]. Some authors proposed that combining PPV+ILM maneuvers and MB might be able to yield more beneficial results. Cao *et al*^[49] performed a Meta-analysis of the efficiency of combined PPV and posterior sclera reinforcement in treating MTM. They reported that 80% of patients had best corrected visual acuity improvement, 93% had retinal reattachment and 65% had macular hole closed, as well as decreased central foveal thickness. In that study, the average AL shortening was 1.74 mm. Parolini *et al*^[41] retrospectively reviewed 157 MTM eyes after MB or PPV or combined surgery, and concluded that PPV is better in addressing the tangential traction existing on the vitreo-retinal surface, while MB is better in resolving the perpendicular traction induced by posterior staphyloma. As the PPV and MB focus on two different aspects of the MTM pathology, surgeons should select proper approaches according to the MTM stages and classifications, separately or combined^[50-52].

In conclusion, in order to provide an insight into the evolving trend of MTM research, we reviewed MTM research history in the past 17y using the visualization software CiteSpace, and analyzed MTM research strengths, research hotspots, and frontiers for MTM research, which may guide new directions for further study.

To the best of our knowledge, this is the first bibliometric analysis on MTM, In their bibliometric analysis on myopia in 2022, Wang *et al*^[53] selected 100 most influential publications, with the research orientation mainly on refractive surgery, epidemiology, and etiology of myopia. Zhang *et al*^[54] published bibliometrics analysis on PM in 2022 and identified “choroidal neovascularization”, “bevacizumab”, “intravitreal

injection” and “photodynamics therapy” as hot topics for high myopia research, these research directions represents the neovascular aspect of high myopia. These researchers all focused on myopia and high myopia, different from our research hotspots and fronts. The main study outcomes were as follows: 1) described the potential collaborators network of the main research field to provide references for strengthening international cooperation and exchanges; 2) followed frontiers and emerging trends in MTM research, and studies on the progression nature of MTM, genome-wide association study and proper classification of MTM might still be the frontiers of MTM researches; 3) identified the hotspots of MTM researches. OCT/OCTA, macular hole, high myopia, and MB are the focus of current studies; 4) OCT based classification may guide clinical strategies for the treatment of MTM.

There are some limitations of this study. First, we selected the literature in the WOS database, while literature in other databases may be excluded, thus researches concerning MTM may not be fully covered. Second, as the literature search was conducted in Jan. 2023, some newly published researches could not be covered.

ACKNOWLEDGEMENTS

Foundation: Supported by Sichuan Administration of Traditional Chinese Medicine (No.2021MS422).

Conflicts of Interest: Zhang HD, None; Zhang L, None; Han F, None; Lin N, None; Jiang W, None.

REFERENCES

- Panozzo G. Optical coherence tomography findings in myopic traction maculopathy. *Arch Ophthalmol* 2004;122(10):1455.
- Wakazono T, Yamashiro K, Miyake M, Nakanishi H, Oishi A, Ooto S, Tsujikawa A, Yoshimura N. Association between eye shape and myopic traction maculopathy in high myopia. *Ophthalmology* 2016;123(4): 919-921.
- Wong TY, Ferreira A, Hughes R, Carter G, Mitchell P. Epidemiology and disease burden of pathologic myopia and myopic choroidal neovascularization: an evidence-based systematic review. *Am J Ophthalmol* 2014;157(1):9-25.e12.
- Ruiz-Medrano J, Montero JA, Flores-Moreno I, Arias L, Garcia-Layana A, Ruiz-Moreno JM. Myopic maculopathy: current status and proposal for a new classification and grading system (ATN). *Prog Retin Eye Res* 2019;69:80-115.
- Holden BA, Fricke TR, Wilson DA, *et al*. Global prevalence of myopia and high myopia and temporal trends from 2000 through 2050. *Ophthalmology* 2016;123(5):1036-1042.
- Ohno-Matsui K, Lai TYY, Lai CC, Cheung CMG. Updates of pathologic myopia. *Prog Retin Eye Res* 2016;52:156-187.
- Ohno-Matsui K, Kawasaki R, Jonas JB, *et al*, META-analysis for Pathologic Myopia (META-PM) Study Group. International photographic classification and grading system for myopic maculopathy. *Am J Ophthalmol* 2015;159(5):877-883.e7.

- 8 Shinohara K, Tanaka N, Jonas JB, Shimada N, Moriyama M, Yoshida T, Ohno-Matsui K. Ultrawide-field OCT to investigate relationships between myopic macular retinoschisis and posterior staphyloma. *Ophthalmology* 2018;125(10):1575-1586.
- 9 Flitcroft DI, He MG, Jonas JB, et al. IMI—defining and classifying myopia: a proposed set of standards for clinical and epidemiologic studies. *Invest Ophthalmol Vis Sci* 2019;60(3):M20-M30.
- 10 Ohno-Matsui K, Wu PC, Yamashiro K, et al. IMI pathologic myopia. *Invest Ophthalmol Vis Sci* 2021;62(5):5.
- 11 Verkicharla PK, Ohno-Matsui K, Saw SM. Current and predicted demographics of high myopia and an update of its associated pathological changes. *Ophthalmic Physiol Opt* 2015;35(5):465-475.
- 12 Ikuno Y. Overview of the complications of high myopia. *Retina* 2017;37(12):2347-2351.
- 13 Kong KJ, Xu SS, Wang YC, et al. Progression patterns of myopic traction maculopathy in the fellow eye after pars plana vitrectomy of the primary eye. *Invest Ophthalmol Vis Sci* 2021;62(15):9.
- 14 Shimada N, Ohno-Matsui K, Yoshida T, Sugamoto Y, Tokoro T, Mochizuki M. Progression from macular retinoschisis to retinal detachment in highly myopic eyes is associated with outer lamellar hole formation. *Br J Ophthalmol* 2008;92(6):762-764.
- 15 Shimada N, Tanaka Y, Tokoro T, Ohno-Matsui K. Natural course of myopic traction maculopathy and factors associated with progression or resolution. *Am J Ophthalmol* 2013;156(5):948-957.e1.
- 16 Gaucher D, Haouchine B, Tadayoni R, Massin P, Erginay A, Benhamou N, Gaudric A. Long-term follow-up of high myopic foveoschisis: natural course and surgical outcome. *Am J Ophthalmol* 2007;143(3):455-462.e1.
- 17 Li SW, Li TT, Wang XN, Cai X, Lu B, Chen Y, Liu C, Wu Q. Natural course of myopic traction maculopathy and factors influencing progression and visual acuity. *BMC Ophthalmol* 2021;21(1):347.
- 18 Frisina R, Gius I, Palmieri M, Finzi A, Tozzi L, Parolini B. Myopic traction maculopathy: diagnostic and management strategies. *Clin Ophthalmol* 2020;14:3699-3708.
- 19 Cheong KX, Xu LQ, Ohno-Matsui K, Sabanayagam C, Saw SM, Hoang QV. An evidence-based review of the epidemiology of myopic traction maculopathy. *Surv Ophthalmol* 2022;67(6):1603-1630.
- 20 Tian JX, Qi Y, Zhang YH, Lin CX, Wang NL. Inter-eye comparison in highly myopic patients with unilateral myopic traction maculopathy. *Curr Eye Res* 2022;47(4):642-649.
- 21 Kim HK. Factors associated with axial length elongation in high myopia in adults. *Int J Ophthalmol* 2021;14(8):1231-1236.
- 22 Wu PC, Chen YJ, Chen YH, Chen CH, Shin SJ, Tsai CL, Kuo HK. Factors associated with foveoschisis and foveal detachment without macular hole in high myopia. *Eye* 2009;23(2):356-361.
- 23 Parolini B, Palmieri M, Finzi A, et al. The new myopic traction maculopathy staging system. *Eur J Ophthalmol* 2021;31(3):1299-1312.
- 24 Yu X, Ma W, Liu B, et al. Morphological analysis and quantitative evaluation of myopic maculopathy by three-dimensional magnetic resonance imaging. *Eye (Lond)* 2018;32(4):782-787.
- 25 Moriyama M, Ohno-Matsui K, Modegi T, Kondo J, Takahashi Y, Tomita M, Tokoro T, Morita I. Quantitative analyses of high-resolution 3D MR images of highly myopic eyes to determine their shapes. *Invest Ophthalmol Vis Sci* 2012;53(8):4510.
- 26 Wong CW, Phua V, Lee SY, Wong TY, Cheung CMG. Is choroidal or scleral thickness related to myopic macular degeneration? *Invest Ophthalmol Vis Sci* 2017;58(2):907.
- 27 Fang YX, Du R, Nagaoka N, Yokoi T, et al. OCT-based diagnostic criteria for different stages of myopic maculopathy. *Ophthalmology* 2019;126(7):1018-1032.
- 28 Zhou YP, Song ML, Zhou MW, Liu YM, Wang FH, Sun XD. Choroidal and retinal thickness of highly myopic eyes with early stage of myopic chorioretinopathy: tessellation. *J Ophthalmol* 2018;2018:2181602.
- 29 Matsumura S, Sabanayagam C, Wong CW, et al. Characteristics of myopic traction maculopathy in myopic Singaporean adults. *Br J Ophthalmol* 2021;105(4):531-537.
- 30 Yokoi T, Jonas JB, Shimada N, Nagaoka N, Moriyama M, Yoshida T, Ohno-Matsui K. Peripapillary diffuse chorioretinal atrophy in children as a sign of eventual pathologic myopia in adults. *Ophthalmology* 2016;123(8):1783-1787.
- 31 Hosoda Y, Yoshikawa M, Miyake M, et al. CCDC102B confers risk of low vision and blindness in high myopia. *Nat Commun* 2018;9(1):1782.
- 32 Kassam I, Foo LL, Lanca C, Xu L, Hoang QV, Cheng CY, Hysi P, Saw SM. The potential of current polygenic risk scores to predict high myopia and myopic macular degeneration in multiethnic Singapore adults. *Ophthalmology* 2022;129(8):890-902.
- 33 Shinohara K, Shimada N, Moriyama M, Yoshida T, Jonas JB, Yoshimura N, Ohno-Matsui K. Posterior staphylomas in pathologic myopia imaged by widefield optical coherence tomography. *Invest Ophthalmol Vis Sci* 2017;58(9):3750.
- 34 Ellabban AA, Tsujikawa A, Matsumoto A, et al. Three-dimensional tomographic features of dome-shaped macula by swept-source optical coherence tomography. *Am J Ophthalmol* 2013;155(2):320-328.e2.
- 35 You QS, Peng XY, Xu L, Chen CX, Wang YX, Jonas JB. Myopic maculopathy imaged by optical coherence tomography. *Ophthalmology* 2014;121(1):220-224.
- 36 Zhao XJ, Ding XY, Lyu CC, et al. Morphological characteristics and visual acuity of highly myopic eyes with different severities of myopic maculopathy. *Retina* 2020;40(3):461-467.
- 37 Wong CW, Teo YCK, Tsai STA, et al. Characterization of the choroidal vasculature in myopic maculopathy with optical coherence tomographic angiography. *Retina* 2019;39(9):1742-1750.
- 38 Li Y, Foo LL, Wong CW, Li J, Hoang QV, Schmetterer L, Ting DSW, Ang M. Pathologic myopia: advances in imaging and the potential role of artificial intelligence. *Br J Ophthalmol* 2023;107(5):600-606.
- 39 Wang YB, Jiang CY, Zhao XJ, Chen J, Li J, Huang X, Liu BQ, Lu L. Changes in myopic maculopathy based on atn classification system. *Retina* 2022;42(4):679-688.

- 40 Li Y, Zheng FH, Foo LL, *et al.* Advances in OCT imaging in myopia and pathologic myopia. *Diagnostics (Basel)* 2022;12(6):1418.
- 41 Parolini B, Palmieri M, Finzi A, Frisina R. Proposal for the management of myopic traction maculopathy based on the new MTM staging system. *Eur J Ophthalmol* 2021;31(6):3265-3276.
- 42 Susvar P, Sood G. Current concepts of macular buckle in myopic traction maculopathy. *Indian J Ophthalmol* 2018;66(12):1772.
- 43 Parolini B, Palmieri M, Finzi A, Besozzi G, Frisina R. Myopic traction maculopathy: a new perspective on classification and management. *Asia Pac J Ophthalmol (Phila)* 2021;10(1):49-59.
- 44 Chen GH, Mao SH, Tong YH, Jiang FZ, Yang JS, Li WS. Fovea sparing versus complete internal limiting membrane peeling for myopic traction maculopathy: a meta-analysis. *Int Ophthalmol* 2022;42(3):765-773.
- 45 Hattori K, Kataoka K, Takeuchi J, Ito Y, Terasaki H. Predictive factors of surgical outcomes in vitrectomy for myopic traction maculopathy. *Retina* 2018;38(Suppl 1):S23-S30.
- 46 Wang YL, Zhao XY, Zhang WF, Yang JY, Chen YX. Fovea-sparing versus complete internal limiting membrane peeling in vitrectomy for vitreomacular interface diseases. *Retina* 2021;41(6):1143-1152.
- 47 He Q, Wang X, Shi QH, Xie CY, Xue AQ, Wei RH. Posterior scleral reinforcement for the treatment of myopic traction maculopathy. *BMC Ophthalmol* 2022;22(1):1-8.
- 48 Alkabes M, Mateo C. Macular buckle technique in myopic traction maculopathy: a 16-year review of the literature and a comparison with vitreous surgery. *Graefes Arch Clin Exp Ophthalmol* 2018;256(5):863-877.
- 49 Cao K, Wang JD, Zhang JS, *et al.* The effectiveness and safety of posterior scleral reinforcement with vitrectomy for myopic foveoschisis treatment: a systematic review and meta-analysis. *Graefes Arch Clin Exp Ophthalmol* 2020;258(2):257-271.
- 50 Zhang P, Hou LX, Hao YH, Wang K, Shang QL. A pilot study on vitrectomy combined with scleral shortening for eyes with myopic macular retinoschisis—2y follow-up results. *Int J Ophthalmol* 2021;14(2):263-268.
- 51 Huang Y, Wei WB, Duan AL. Long-term outcome of pathologic myopic foveoschisis treated with posterior scleral reinforcement followed by vitrectomy. *Int J Ophthalmol* 2022;15(6):975-982.
- 52 Chen J, Chen SD, Zhao XJ, Lian P, Yu XL, Huang X, Liu BQ, Li YH, Lu L. Characteristics and management of myopic traction maculopathy in myopic eyes with axial length less than 26.5 mm. *Retina* 2022;42(3):540-547.
- 53 Wang XJ, Chen D, Jiang Y, Chou YY, Luo Y, Li Y, Ma J, Zhong Y. The 100 most influential articles in myopia: a bibliometric analysis. *Int J Ophthalmol* 2022;15(1):150-156.
- 54 Zhang XD, Wang CX, Jiang HH, Jing SL, Zhao JY, Yu ZY. Trends in research related to high myopia from 2010 to 2019: a bibliometric and knowledge mapping analysis. *Int J Ophthalmol* 2021;14(4):589-599.