

# Symmetry of upper eyelid after unilateral blepharoptosis repair with minimally invasive conjoint fascial sheath suspension technique

Yianzhu Liu<sup>1,2</sup>, Wenli Chen<sup>1,2</sup>, Xia Chen<sup>1,2</sup>

<sup>1</sup>Tianjin Eye Hospital, Tianjin 300020, China

<sup>2</sup>Tianjin Key Lab of Ophthalmology and Visual Science, Tianjin 300020, China

**Co-first authors:** Yianzhu Liu and Wenli Chen

**Correspondence to:** Wenli Chen. Tianjin Eye Hospital; Tianjin Key Lab of Ophthalmology and Visual Science, Tianjin 300020, China. wenlichenf@126.com

Received: 2023-01-05 Accepted: 2023-10-31

## Abstract

• **AIM:** To investigate the symmetry of upper eyelid in patients with unilateral mild and moderate blepharoptosis who underwent unilateral minimally invasive combined fascia sheath (CFS) suspension.

• **METHODS:** A retrospective study of patients who underwent unilateral minimally invasive CFS suspension surgery between January 2018 and December 2021. Inclusion criteria included unilateral mild and moderate ptosis, good levator muscle function (>9 mm) and follow-up of at least 6mo. Pre- and post-operative symmetry was graded subjectively for marginal reflex distance 1 (MRD1), tarsal platform show (TPS) and eyebrow fat span (BFS). A *t*-test was used to evaluate MRD1, TPS and BFS asymmetry by calculating delta values. The Bézier curve tool of the Image J software was used to extract the upper eyelid contours, where the symmetry was measured by the percentage of overlapping curvatures (POC).

• **RESULTS:** Totally 105 patients (105 eyelids) were included (mild group, *n*=84; moderate group, *n*=21). Postoperatively, all patients increased MRD1 and decreased TPS in the ptotic eye while maintaining unchanged BFS. The asymmetric delta value for MRD1 was measured to be 1.48±0.86 preoperatively, and it decreased to 0.58±0.67 postoperatively in all cases (*P*=0.0004). In patients with mild ptosis, the asymmetry value of TPS fell significantly from 1.15±0.62 to 0.68±0.38 (*P*=0.0187). The symmetry of the upper eyelid contour increased in all subgroups of patients, with a POC of 59.39%±13.45% preoperatively and POC of 78.29%±13.80% postoperatively.

• **CONCLUSION:** Minimally invasive CFS suspension is proved to be an effective means of improving the symmetry of unilateral ptosis in terms of MRD1 (all subgroups), POC (all subgroups) and TPS (only mild group), whereas BFS is unaffected.

• **KEYWORDS:** symmetry; unilateral blepharoptosis; minimally invasive combined fascia sheath suspension

**DOI:10.18240/ijo.2024.01.07**

**Citation:** Liu Y, Chen W, Chen X. Symmetry of upper eyelid after unilateral blepharoptosis repair with minimally invasive conjoint fascial sheath suspension technique. *Int J Ophthalmol* 2024;17(1):53-60

## INTRODUCTION

Patients with unilateral mild and moderate ptosis usually require surgical treatment of the unaesthetic eyelid. There are three viable options basically: Muller's muscle-conjunctival resection (MMCR)<sup>[1-2]</sup>, the Fasanella-Servat procedure and levator aponeurosis repair<sup>[3]</sup>. Traditionally surgery for aponeurotic ptosis has been directed upon the levator aponeurosis complex, in the majority of cases, through an anterior approach. The transconjunctival route was probably the first method of surgery employed to shorten the levator muscle. However, the existing MMCR or modified MMCR are beset by question of the accuracy of repair while the traditional open approaches are excessively invasive, leaving scars and prolonging recovery time<sup>[4-6]</sup>. More recently, a new technique of minimally invasive combined fascial sheath (CFS) suspension has been introduced for blepharoptosis correction<sup>[5,7]</sup>. The CFS, also known as check ligament, inferior ligament of Whitnall, suspensory ligament of superior fornix, and transverse superior fascial expansion, is a thick fibrous sheath located at the top of Muller's muscle. Histologically, CFS is composed of thick collagen bundle and confluent elastic fibers without any smooth muscles. Due to its tough nature, it has been used successfully in open, anterior approach of blepharoptosis surgery<sup>[7-11]</sup>. In this research, we have further developed this technique and used the CFS as a fixation point from which to suspend the tarsus using sutures. This allows

correction of blepharoptosis and the formation of double eyelids at the same time.

From a functional standpoint, the CFS suspension technique has been proven to be an effective way to correct blepharoptosis. Previous studies have reported the marginal reflex distance 1 (MRD1) improved significantly post-operation<sup>[5]</sup>. However, surgery for blepharoptosis also has cosmetic implications, and controlling symmetry can be difficult, especially for unilateral ptotic patients. Beyond the basic measurement of MRD1, the purpose of this study was to analyze the symmetry of the upper eyelid in patients who underwent unilateral minimally invasive CFS suspension. Pre- and post-operative symmetry was subjectively graded of MRD1, tarsal platform show (TPS), and eyebrow fat span (BFS). In addition, we also investigated the symmetry of upper eyelid contours, based on the percentage of overlapping curvatures (POC), which uses a semi-automated method of curve adjustment (Bézier curves) to estimate the range of differences in the upper eyelid contours.

### SUBJECTS AND METHODS

**Ethical Approval** This study was conducted in accordance with the tenets of the Declaration of Helsinki and was approved by Tianjin Eye Hospital Foundation Institutional Review Board (No.2021026). All authors had permission to access patient records. We confirmed that all written consent was obtained from the participant.

**Subjects** The data of patients treated from January 2018 and December 2021 were collected. The inclusion criteria included: 1) unilateral mild and moderate ptosis; 2) good levator muscle function (>9 mm); 3) no previous ptosis repair surgery history; 4) follow-up of at least 6mo. All ptotic eyes were required to meet the criterion of marginal reflex distance 1 (MRD1) greater than 1 mm. Mild ptosis was defined as a difference in MRD1 of 2 mm or less between the ptotic eye and the fellow normal eye, and moderate ptosis was defined as a 2- to 4-mm difference. Mild blepharoptosis was corrected by suspension sutures with 2-3 loops, whereas moderate blepharoptosis was corrected with 5 loops. All surgeries were performed by the same surgeon.

For all patients, preoperative and postoperative digital photographs were taken in primary gaze, with the plane of the face parallel to the plane of the camera back. Lighting was accomplished with a slave-driven studio soft box flash unit. The camera was Canon EOS 550D.

**Surgical Design and Technique** Once the patient was in an upright position, the amount of ptosis correction needed was established. The height of the eyelid on the ptotic side was determined according to the contralateral normal eyelid. Ideally, the position of the ptotic upper eyelid margin was 1-2 mm higher than the normal side. The mark should be made 1 mm shorter than the normal side for the strength of the

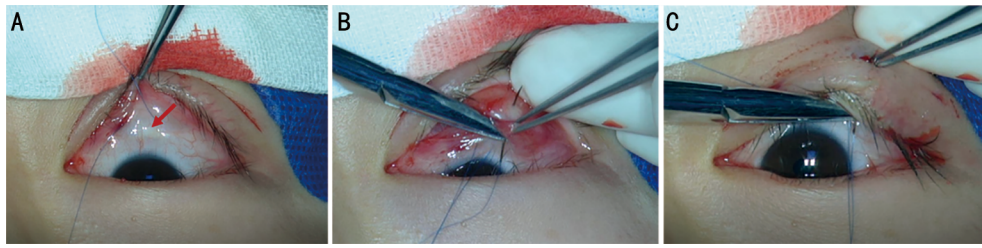
levator muscle of the ptotic eye was weaker and the crease was assumed to be wider.

Surgeries were performed under local anesthesia in all patients. The skin of the upper eyelid and superior fornix were infiltrated with 2% lidocaine with 1:100 000 epinephrine. Following local anesthesia, the skin crease incision was performed at the marked area (1 mm minor slits). Turning the upper eyelid inside out, a 5-0 nylon suture was applied at the upper margin of the central part of the tarsus and suspended in the anterior superior direction. This suspension provides exposure of the fornix of the superior conjunctiva. Once the superior fornix was exposed, the CFS can be readily distinguished from the surrounding tissue because it was whiter in comparison to the surrounding conjunctiva (Figure 1). A 6-0 nylon suture was inserted into the CFS and passed through the soft tissue for 1 to 2 mm. The same suture was reinserted into the CFS and extended to the tarsal plate at the depth between the levator aponeurosis and the Muller's muscle, eventually piercing through the tarsus. Likewise, another end of the suture passed through the same route and penetrated the tarsus in the same place. Then two needles come out of the small incision made in the skin earlier. Then, the thread was tied into a slipknot. After completion of all suspension sutures, patients were instructed to sit up to assess the position of the upper eyelid margin. The thread was adjusted until the margin of the ptotic lid was placed 1-2 mm higher than the healthy lid. At last, a fixed knot was made and buried in the minor slit of the upper eyelid. The 5-0 nylon suture was removed. Mild blepharoptosis was corrected by 2-3 loops suspension sutures, while moderate blepharoptosis was corrected by 5 loops. The detailed design of the suture placement has been described in our previous study<sup>[5]</sup>.

**Statistical Analysis** The photos were attained before the surgery and at 6mo postoperatively in a standardized fashion with the same camera, at the same distance from the patients. Patients were required to stabilize their brows, ensuring their frontalis muscle was not recruited. All measurements were obtained by Image J 1.80 (National Institutes of Health <https://imagej.nih.gov/ij/>). The corneal diameter was standardized to 11.5 mm to convert the pixel measurements to millimeters. MRD1 was measured from the centre of the pupil to the lowermost margin of the upper eyelid in the mid-pupillary line, while TPS was calculated between the skin fold at the eyelid crease and the eyelid margin. BFS was measured between the skin fold to the top of the eyebrow hairs (Figure 2A).

To analyze eyelid symmetry based on MRD1, TPS, and BFS measurements, the asymmetry value *delta* was used, calculated using the following formula. The *R* and *L* stand for the measurements from the right and left sides<sup>[1]</sup>.

$$\text{delta} = |(R - L)|$$



**Figure 1** The minimally invasive CFS suspension method for the correction of ptosis A: CFS (whitish tissue) can be perceived as a distinct structure. The suture is inserted into the CFS and passed through the soft tissue 1-2 mm. B: Shortening of the distance between the upper margin of the tarsal plate and CFS; C: After piercing through the tarsus, the needle exited from the minor slit previously made. CFS: Combined fascia sheath.

Using the Bézier icon in Image J, the user was able to draw a straight line between the lateral canthus and the end of the ciliated part, then this line can be adjusted to fit the eyelid contour by dragging the two control points around (Figure 2B). The numerical coordinates of the line representing the contour were saved and transferred to MATLAB for graphical analysis (MathWorks, Natick, Mass.). The final contour lines relative to the pupil center are displayed in Figure 2C.

The symmetry of the eyelid contours was obtained by calculating the POC<sup>[12]</sup>.

$$POC = \left(1 - \frac{\sum_{i=1}^N |y_{l,i} - y_{r,i}|}{\sum_{i=1}^N |y_{l,i} + y_{r,i}|}\right) \times 100\%$$

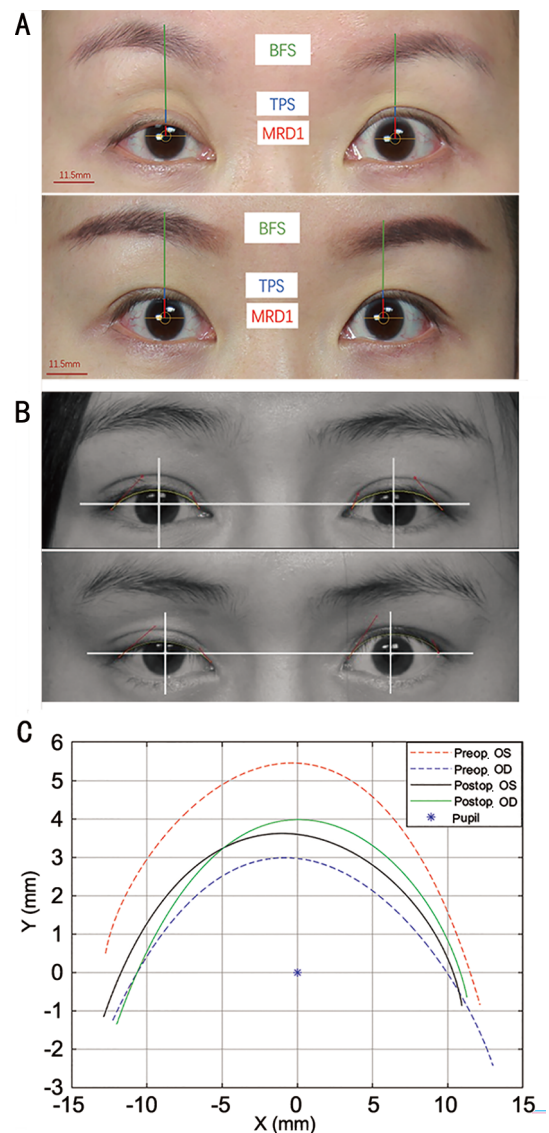
In this equation,  $y_l$  and  $y_r$  are the y-coordinates of the left and right eyes, respectively. The numerator stands for the sum of the absolute differences between  $y_l$  and  $y_r$  at each point of  $i$ , whereas the denominator stands for the absolute sum of  $y_l$  and  $y_r$ .  $N$  is the total number of points constituting Bézier curve.

A paired student's  $t$ -test was used to evaluate the parametric pre- and post-operative results.

## RESULTS

A total of 105 patients were enrolled, 68 were women and 37 were men, with a mean age of  $32.4 \pm 10.3$ y, ranging from 20 to 52 years old. In this study, 105 patients were divided into two groups: 84 patients were diagnosed with mild ptosis and had 2 or 3 loop suspension sutures placed (mild group), whereas 21 patients had a diagnosis of moderate ptosis and underwent 5 loops (moderate group). Surgical interventions were tolerated by all patients. No postoperative complications such as hemorrhage, infection, or corneal erosion were noted. Eyelid contour may be slightly unsymmetrical compared to the normal side in few patients, but no secondary surgery was needed.

There was an overall data and a comparison between the mild and moderate groups (Table 1). For MRD1, all ptotic eyes presented an increasing tendency after surgery, whereas healthy eyes showed a decreasing trend (Figure 3A). In the mild ptosis group, the MRD1 of the ptotic eyes increased from  $1.87 \pm 0.62$  to  $2.65 \pm 0.87$  ( $P=0.005$ ), while the value in the



**Figure 2** Examples of how preoperative and postoperative clinical photographs are employed in Image J software and bilateral eyelid contours are extracted A: Photos demonstrating the measurement of marginal reflex distance 1 (MRD1), tarsal platform show (TPS) and eyebrow fat span (BFS) pre- and post-operation; B: Adjustment of a Bézier curve to the lid contour moving freely between two control points (lateral canthus and the end of the ciliated part) pre- and post-operation; C: Superimposed Bézier curves of the right and left eyelids before and after the operation.

**Table 1 Overall data and comparison between mild and moderate ptosis**

Parameters	All subjects	Mild ptosis	Moderate ptosis
Preop. MRD1 of ptotic eye (mm)	1.71±0.66	1.87±0.62	1.19±0.31
Preop. MRD1 of healthy eye (mm)	3.19±0.58	3.03±0.37	3.84±0.56
Postop. MRD1 of ptotic eye (mm)	2.67±1.07	2.65±0.87	2.73±1.28
Postop. MRD1 of healthy eye (mm)	2.57±0.97	2.34±0.68	3.51±0.48
Preop. TPS of ptotic eye (mm)	3.48±1.18	3.34±1.26	4.03±0.91
Preop. TPS of healthy eye (mm)	2.22±0.83	2.19±0.97	2.36±0.15
Postop. TPS of ptotic eye (mm)	2.57±1.17	2.44±1.28	3.08±0.71
Postop. TPS of healthy eye (mm)	2.51±0.96	2.55±1.08	2.37±0.57
Preop. BFS of ptotic eye (mm)	20.08±3.10	19.83±3.15	21.03±3.46
Preop. BFS of healthy eye (mm)	17.62±2.26	17.75±2.37	17.09±2.38
Postop. BFS of ptotic eye (mm)	19.01±2.43	18.79±2.70	19.87±1.81
Postop. BFS of healthy eye (mm)	17.54±2.04	17.51±2.21	17.64±1.85
Preop. POC (%)	59.39±13.45	63.16±8.17	44.33±8.35
Postop. POC (%)	78.29±13.80	81.55±8.53	65.27±14.95

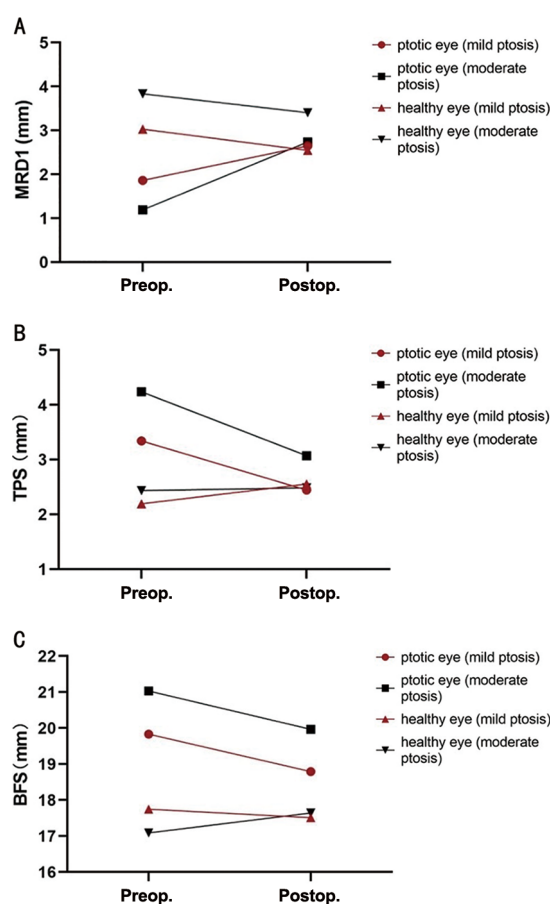
MRD1: Marginal reflex distance 1; TPS: Tarsal platform show; BFS: Eyebrow fat span; POC: Percentage of overlapping curvatures.

healthy eyes decreased from  $3.03\pm 0.37$  to  $2.34\pm 0.68$  ( $P=0.022$ ). Similarly, in the moderate group, the MRD1 of ptotic eyes rose from  $1.19\pm 0.31$  to  $2.73\pm 1.28$  ( $P=0.047$ ), with the value in the healthy eyes declining to  $3.51\pm 0.48$  ( $P=0.032$ ).

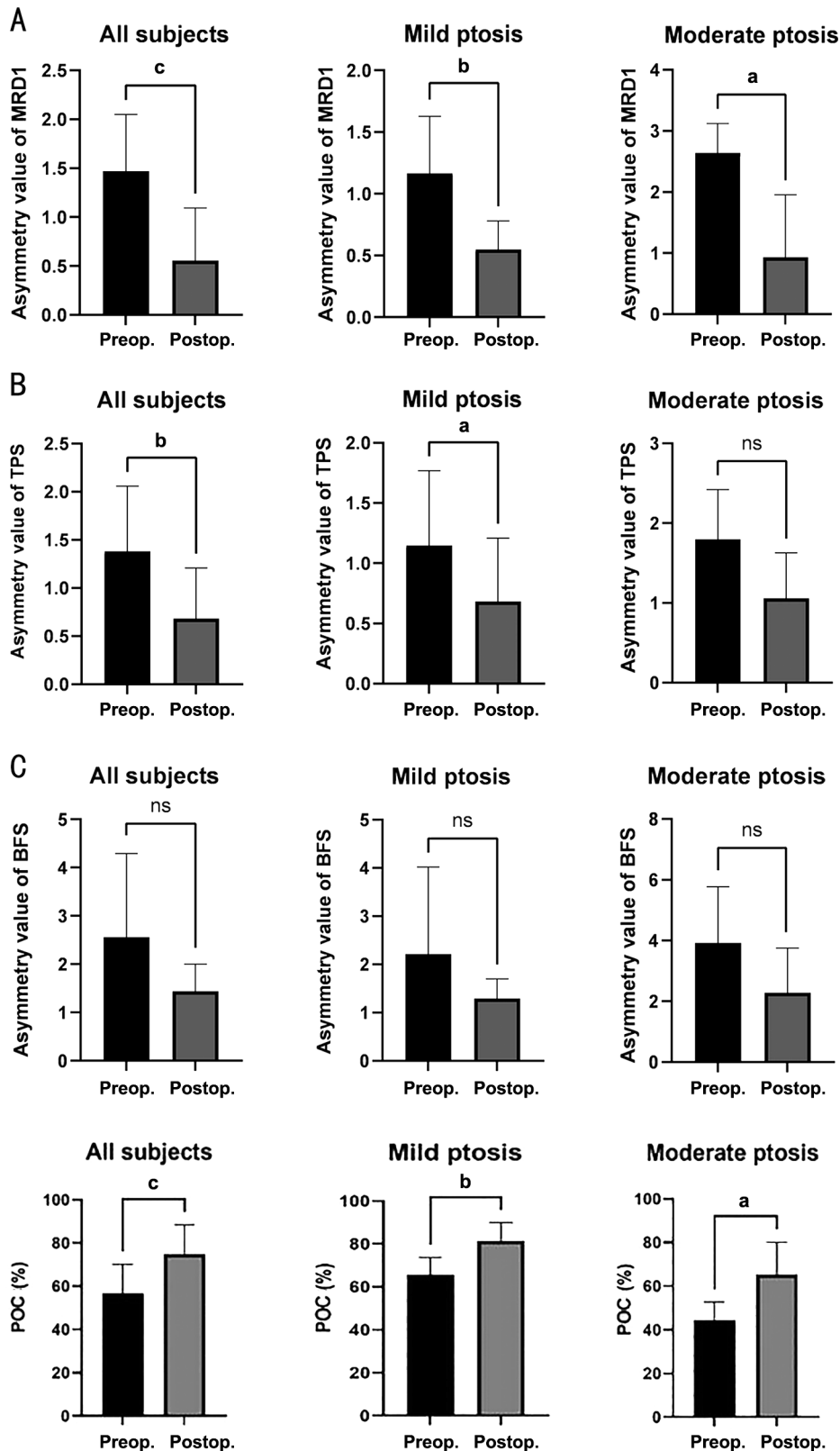
In unilateral ptotic patients, the amount of TPS of ptotic eyes was noticed greater than the healthy eyes before surgery (Figure 3B). Postoperatively the TPS of ptotic eyes in mild and moderate groups all fell significantly ( $P=0.003$  and  $P=0.05$ , respectively). As for the healthy eyes, the mild group revealed an increasing trend, whereas the moderate group remained unchanged ( $P=0.008$  and  $P=0.83$ , respectively).

In terms of BFS, the value of the ptotic side was found higher than the unaffected side preoperatively ( $20.08\pm 3.10$  and  $17.62\pm 2.26$  respectively,  $P=0.0005$ ). After surgery, although some patients exhibited reducing BFS of the ptotic side, there was no statistical significance found in either the mild or moderate groups ( $P=0.195$  and  $P=0.292$ , respectively). In all cases, the BFS in health reveal the same (Figure 3C).

An asymmetry analysis was performed on MRD1, TPS, and BFS, where MRD1 and TPS showed meaningful changes after surgery, while BFS remained little improved. The asymmetry value was measured as the delta value of the long side minus that of the short side (Figure 4A). Preoperative MRD1 asymmetry measured  $1.48\pm 0.86$ , and it decreased to  $0.58\pm 0.67$  postoperatively in all cases ( $P=0.0004$ ). There was a greater improvement in MRD1 asymmetry in the mild group compared to the moderate group ( $0.53\pm 0.32$  and  $0.78\pm 1.02$  respectively). Figure 4B illustrates the asymmetry changes in TPS, for mild ptotic patients, the asymmetry value decreased significantly from  $1.15\pm 0.62$  to  $0.68\pm 0.38$  ( $P=0.0187$ ). Although there was an improved tendency of the asymmetry in the moderate group, no statistically significant differences [from  $1.67\pm 0.62$  to  $1.06\pm 0.57$  ( $P=0.0745$ )] were observed. Figure 4C



**Figure 3 Evaluation of the change of MRD1, TPS and BFS before and after the operation** A: In mild and moderate ptosis groups, the marginal reflex distance 1 (MRD1) of the ptotic eyes increased while the value for healthy eyes declined; B: The tarsal platform show (TPS) of ptotic eyes in mild and moderate groups all fell significantly postoperatively. As for the healthy eyes, mild group revealed an increasing trend, whereas the moderate group remained unchanged; C: Eyebrow fat span (BFS) of the ptotic side was higher than that of the unaffected side preoperatively. No statistical significance was found postoperatively in mild and moderate groups of the ptotic side.



**Figure 4 Evaluation of the symmetry of MRD1, TPS, BFS and POC before and after the operation** Asymmetry value was measured as the delta of longer minus the shorter side. A: The difference of marginal reflex distance 1 (MRD1) between the two eyes decreased significantly postoperatively in all subgroups; B: For mild ptotic patients, the asymmetry value of tarsal platform show (TPS) fell significantly. Though there was an improved tendency of the asymmetry in moderate group, no statistically significant difference was observed. C: All cases and subgroups analysis showed a decreasing trend in the difference in eyebrow fat span (BFS) between two eyes postoperatively, though the change was not significant; D: There was a significant difference in degrees of contour symmetry between patients with mild and moderate ptosis before and after surgery. Percentage of overlapping curvatures (POC) was lower in the moderate group preoperatively, but surgeries lead to a dramatic rise in POC in both groups. Statistical analysis was conducted using Student's *t*-test with <sup>a</sup>*P*<0.05, <sup>b</sup>*P*<0.01, <sup>c</sup>*P*<0.001.

demonstrates the changes in BFS asymmetry before and after surgery, all cases and subgroups analysis showed a decreasing trend, though the change was not significant.

The degree of contour symmetry was a significantly different between patients with mild and moderate ptosis before and after surgery (Figure 4D). POC was lower in the moderate group preoperatively ( $63.16\% \pm 8.17\%$  and  $44.33\% \pm 8.35\%$ ), but surgeries lead to a dramatic rise in POC in both groups ( $P=0.0013$ ), reaching  $81.55\% \pm 8.53\%$  and  $65.27\% \pm 14.95\%$  respectively.

### DISCUSSION

The primary goal of this study is to investigate the symmetry of upper eyelid in patients with unilateral mild and moderate blepharoptosis who underwent CFS suspension. Though many researchers mainly focus on the successful rate of one procedure, surgery for blepharoptosis also has cosmetic implications, and symmetry control can be difficult, especially for unilateral ptotic patients. Thus, only assessing the eyelid margin position seems inadequate to address the other aesthetic determinants of blepharoptosis surgery. It is equally important to control symmetry in TPS, BFS, and upper eyelid contour as well<sup>[13]</sup>.

CFS is a transparent fascia wrapping the posterior half of the levator and gradually fusing with the upper part of the aponeurosis sheath surrounding the superior rectus. When looking upwards, the superior rectus brings the CFS upwards, therefore, both forces from the levator and the superior rectus are transmitted to the tarsal plate through the suspension sutures<sup>[10,14-15]</sup>.

The CFS suspension technique has been proven to be an effective way to correct blepharoptosis. Previous studies have reported that the MRD1 improved significantly post-operation<sup>[5]</sup>. In this research, we confirmed the result and further discovered that the symmetry was improved in all subgroups in terms of MRD1. The underlying reason for this includes MRD1 elevation of operative eyes and fall of healthy eyes. Whether the Hering's phenomenon should be taken into consideration to determine the design of the ptosis operation has always been controversial. Some surgeons preferred bilateral ptosis operation since preoperative Hering's phenomenon and intraoperative contralateral upper eyelid changes<sup>[16-17]</sup>. Furthermore, it was found that Hering's law effect was more common with the levator advancement approach than with Muller ectomy<sup>[17]</sup>. In our research, the repair of the ptotic eyelid did result in contralateral eyelid drooping due to Hering's law phenomena, but the change was not significant. The reasons behind this are multifaceted. The retraction of the contralateral eyelid depends on multiple factors: the orbicularis oculi, the frontalis muscle, the sympathetic reaction by Muller's muscle, and coexisting mild

ptosis in the opposite eye. The ocular dominance also has a strong influence on the compensatory retraction as well<sup>[18]</sup>. Therefore, predicting contralateral ptosis postoperatively seems difficult and impracticable. As a result, we eliminated the effect of increased innervation and designed the height of the eyelid of the ptotic side according to the contralateral side. The presentation of the tarsal platform show is a multifactorial combination of eyelid margin position, subcutaneous fat and eyebrow position. In fact, the symmetry of TPS may be more important than MRD1 in perceiving facial appearance<sup>[13,19]</sup>. In order to form or perfect the eyelid crease, patients especially who lack a supratarsal crease, tend to choose the anterior approach of blepharoptosis surgery as it attaches the skin to deep structures. Our method allows the needle passes transversely through the CFS and tarsal plate, lifting the ptotic eyelid and forming a double eyelid simultaneously. After a 6mo follow-up time, we found TPS of ptotic eyes in the mild and moderate groups all fell significantly. With regard to the asymmetry analysis, patients in the mild group revealed an improved delta value, whereas the value of moderate group did not show a statistically significant difference, suggesting the eyebrow compensation may play a crucial role in the control of the eyelid fold width. Because of the compensatory force triggered by ptosis, as the eyebrow moves upward, the soft tissues are elevated off the tarsal plate to an excessive level, leading to the increase of TPS measurement. Unexpectedly, based on our data, the eyebrow compensation phenomenon did now alleviate post-CFS suspension in all patients. It is possible that the contributing factor of eyebrow compensation may not have a discernible effect in the mild ptosis group, as a minor improvement can make a difference, in that case, the sole factor of eyelid margin elevation could ameliorate asymmetry. But in cases of moderate ptosis, the symmetry of the TPS is not easily acquired due to brow compensation.

In this series of patients who underwent unilateral CFS suspension for ptosis of the eyelids, after surgery, we observed an improved trend of eyebrow symmetry in some patients, but other patients either remained in their original condition or improved minimally. Therefore, the quantified analysis of the asymmetry value delta did not show significant differences across cases and subgroups. This could be explained by the fact that more severe cases of blepharoptosis were associated with greater descent of the eyebrows following the operation. The contraction of the frontalis muscle, due to the visual incentive to clear the visual axis, was weaker in mild and moderate ptosis than in severe cases, resulting in fewer differences after ptosis repair. A study using CFS suspension to correct moderate-severe ptosis showed a descended eyebrow position, improved facial symmetry, and reduced forehead lines<sup>[20]</sup>. The analysis from a similar study revealed that half of the preoperatively



asymmetric brow patients who underwent MMCR surgery improved in symmetry of the brow for both unilateral and bilateral cases. This response, however, was difficult to predict and poorly related to MRD1 symmetry<sup>[21]</sup>. On the other hand, the frontalis muscle itself has several anatomical variations, which can strongly influence its function in synchronous action with the levator/Muller muscle<sup>[22]</sup>. Taken together, these research and our data indicate that brow compensation remains somewhat idiosyncratic in both incidence and response to eyelid ptosis surgery.

Eyelid contour analysis has been performed with a variety of methods. Temporal/nasal distances and area ratios were often utilized to describe and compare upper eyelid contour<sup>[23]</sup>, while polynomial functions to extracted eyelid contour were also employed<sup>[24]</sup>. Moreover, some investigators measured the distances from mid pupil to the upper eyelid radially at intervals of 15° (total, 180°) along the palpebral fissure, and measurements at each angle were compared for symmetrical analysis<sup>[25]</sup>. In recent studies, multiple researchers all used the Bezier curve function of the Image J software to extract the upper eyelid contour<sup>[12,26-27]</sup>. In the present study, we employed the same protocol and evaluate the degree of contour symmetry by calculating the POC.

Although we saw a dramatic decline in the differences of MRD1 between the ptotic and healthy eyes after surgery, the overall POC was only 74.68%±13.80%, suggesting that assessing MRD1 alone may be insufficient for determining the success of the outcomes. The reason behind this is that POC also takes into account the horizontal position of the peak of the upper eyelid. Digital analysis of the upper eyelid showed that the uppermost point of the normal upper eyelid was just temporal to the mid pupillary line<sup>[28]</sup>. However, the strategy we employed for correction of mild blepharoptosis correction is 2 or 3 suspension sutures, moderate ptosis with 5 sutures, all sutures were centered on the mid pupillary line. These slight differences may cause an unintended shift in the peak of the upper eyelid.

Limitations of this study include the retrospective nature of its data analysis, the imbalanced ratio of the two subgroups, and the limited number of races. Our study only involved Asian patients, the majority of whom with single eyelid have excessively swollen upper eyelids. Caucasian patients may present different outcomes due to anatomical variation. Furthermore, we measured the TPS and BFS in the central eyelid. Although this method was chosen to simplify the analysis, a more comprehensive cosmetic measurement would include the actual contour of the TPS and BFS. For example, the central TPS is measured in a symmetrical fashion, but some patients may have an asymmetry in the temporal third of the TPS. Therefore, further investigation should be a more

comprehensive objective analysis including eyelid crease contour, eyebrow contour, or even the eyelash direction may be necessary, hopefully leading to a more rigorous analysis of the aesthetic outcome of ptosis surgery.

In conclusion, our findings may have implications for understanding the predictability of this procedure. Minimally invasive CFS suspension can be an effective operation for improving TPS symmetry in the mild ptotic group and MRD1, POC in all the subgroups. However, it does exert an inconclusive effect on brow compensation, so patients and surgeons may expect unimproved asymmetrical brow position as a result of CFS suspension surgery.

#### ACKNOWLEDGEMENTS

**Foundation:** Supported by Tianjin Key Medical Discipline Construction Project (No.TJYXZDXK-016A).

**Conflicts of Interest:** Liu Y, None; Chen W, None; Chen X, None.

#### REFERENCES

- 1 Yeh SH, Liao SL, Wei YH. Efficacy and predictability of Muller's muscle-conjunctival resection with different tarsectomy lengths for unilateral blepharoptosis treatment. *BMC Ophthalmol* 2021;21(1):83.
- 2 Khooshabeh R, Baldwin HC. Isolated Muller's muscle resection for the correction of blepharoptosis. *Eye (Lond)* 2008;22(2):267-272.
- 3 Pang NK, Newsom RW, Oestreicher JH, Chung HT, Harvey JT. Fasanella-servat procedure: indications, efficacy, and complications. *Can J Ophthalmol* 2008;43(1):84-88.
- 4 Fazil K, Ozturker C, Ozturk Karabulut G, Aygit ED, Kepez Yildiz B, Taskapili M, Kaynak P. Anterior-approach versus posterior-approach levator advancement surgery in aponeurotic ptosis. *J Craniofac Surg* 2020;31(5):1318-1321.
- 5 Melita D, Innocenti A. Minimally invasive conjoint fascial sheath suspension for blepharoptosis correction. *Aesthetic Plast Surg* 2019;43(6):1683-1684.
- 6 Ullrich K, Malhotra R. How far we have come: a review of the evolution of posterior approach ptosis surgery. *Clin Exp Ophthalmol* 2019;47(8):1082-1087.
- 7 Ahn TJ, Kim JH, Lee EI, Lew DH, Kim NH, Park RH, Kim KT, Song SH. Nonincisional conjoint fascial sheath suspension: a novel technique for minimally invasive blepharoptosis correction. *Ann Plast Surg* 2017;79(4):334-340.
- 8 Li B, Yang JW, Wu WC, Chai C, Gu Z, He ZQ, Tan ZW, Cheng SH, Lu P, Zeng LZ. Anatomical and histological study of the conjoint fascial sheath of the levator and superior rectus for ptosis surgery. *Ophthalmic Plast Reconstr Surg* 2020;36(6):617-620.
- 9 Sang PF, Fang MS, Li X, Liu C, Xi QC. Treatment of severe ptosis by conjoint fascial sheath suspension. *Biomed Res Int* 2021;2021:1837458.
- 10 Hwang K, Shin YH, Kim DJ. Conjoint fascial sheath of the levator and superior rectus attached to the conjunctival fornix. *J Craniofac Surg* 2008;19(1):241-245.

- 11 Lukas JR, Priglinger S, Denk M, Mayr R. Two fibromuscular transverse ligaments related to the levator palpebrae superioris: Whitnall's ligament and an intermuscular transverse ligament. *Anat Rec* 1996;246(3):415-422.
- 12 Golbert MB, Garcia DM, Akaishi PMS, Cruz AAVE. Upper eyelid contour symmetry measurement with Bézier curves. *Arq Bras Ophthalmol* 2020;83(1):28-32.
- 13 Goldberg RA, Lew H. Cosmetic outcome of posterior approach ptosis surgery (an American Ophthalmological Society thesis). *Trans Am Ophthalmol Soc* 2011;109:157-167.
- 14 Hao DY, Cang ZQ, Cui JB, Chen YJ, Song BQ, Cao J, Liu CH, Peng P. Conjoint fascial sheath suspension for correction of recurrent blepharoptosis. *Aesthetic Plast Surg* 2022;46(2):744-751.
- 15 Ettl A, Priglinger S, Kramer J, Koornneef L. Functional anatomy of the levator palpebrae superioris muscle and its connective tissue system. *Br J Ophthalmol* 1996;80(8):702-707.
- 16 Zoumalan CI, Lisman RD. Evaluation and management of unilateral ptosis and avoiding contralateral ptosis. *Aesthet Surg J* 2010;30(3):320-328.
- 17 Nemet AY. The effect of hering's law on different ptosis repair methods. *Aesthet Surg J* 2015;35(7):774-781.
- 18 Cetinkaya A, Kersten RC. Surgical outcomes in patients with bilateral ptosis and Hering's dependence. *Ophthalmology* 2012;119(2):376-381.
- 19 Chen HJ, Wang CY, Huang YF, Wu YC, Wei LC. Effect of Muller's muscle-conjunctival resection on the upper eyelid crease position in Asian eyelids: a retrospective cohort study. *BMC Ophthalmol* 2022;22(1):377.
- 20 Fan X, Hao DY, Cao J, Cang ZQ, Cui JB, He YX, Liu CH, Peng P, Song BQ. Aesthetic changes of brow-eyelid continuum after correction of moderate-severe blepharoptosis with conjoint fascial sheath suspension. *Aesthetic Plast Surg* 2022;46(6):2825-2832.
- 21 Karlin JN, Rootman DB. Brow height asymmetry before and after eyelid ptosis surgery. *J Plast Reconstr Aesthet Surg* 2020;73(2):357-362.
- 22 Raveendran SS, Anthony DJ. Classification and morphological variation of the frontalis muscle and implications on the clinical practice. *Aesthetic Plast Surg* 2021;45(1):164-170.
- 23 Malbouisson JM, Baccega A, Cruz AA. The geometrical basis of the eyelid contour. *Ophthalmic Plast Reconstr Surg* 2000;16(6):427-431.
- 24 Milbratz GH, Garcia DM, Guimarães FC, Cruz AAV. Multiple radial midpupil lid distances: a simple method for lid contour analysis. *Ophthalmology* 2012;119(3):625-628.
- 25 Golbert M, Pereira FJ, Garcia DM, Cruz AAV. Contour symmetry of the upper eyelid following bilateral conjunctival-müller's muscle resection. *Aesthet Surg J* 2017;37(3):269-275.
- 26 Serefoglu Cabuk K, Asik Nacaroglu S, Ozturk Karabulut G, Fazil K, Arslan MS, Guler MG, Taskapili M. Muller muscle conjunctival resection or external levator advancement; a quantitative comparison of symmetry in unilateral ptosis. *Eur J Ophthalmol* 2022;32(4):2125-2132.
- 27 Aytogan H, Ayıntap E. Comparing the symmetry of upper eyelid following unilateral ptosis correction. *BMC Ophthalmol* 2021;21(1):438.
- 28 Cruz AA, Coelho RP, Baccega A, Lucchezi MC, Souza AD, Ruiz EE. Digital image processing measurement of the upper eyelid contour in Graves disease and congenital blepharoptosis. *Ophthalmology* 1998;105(5):913-918.