

# Silicone oil as a corneal lubricant to reduce corneal edema and improve visualization during vitrectomy

Dan-Yang Che<sup>1,2</sup>, Zhu-Lin Chan<sup>3</sup>, Ji-Bo Zhou<sup>1,2</sup>, Dong-Qing Zhu<sup>1,2</sup>

<sup>1</sup>Department of Ophthalmology, Ninth People's Hospital, Shanghai Jiao Tong University School of Medicine, Shanghai 200011, China

<sup>2</sup>College of Health Science and Technology, Shanghai Jiao Tong University School of Medicine, Shanghai 200011, China

<sup>3</sup>The PLA Navy Anqing Hospital, Anqing 246004, Anhui Province, China

**Co-first authors:** Dan-Yang Che and Zhu-Lin Chan

**Correspondence to:** Dong-Qing Zhu and Ji-Bo Zhou. No.639, Zhizaoju Road, Shanghai 200011, China. dqzeye@163.com; zhoujibo1000@aliyun.com

Received: 2023-07-12 Accepted: 2023-11-09

## Abstract

• **AIM:** To evaluate the efficacy and safety of silicone oil (SO) as a corneal lubricant to improve visualization during vitrectomy.

• **METHODS:** Patients who underwent vitreoretinal surgery were divided into two groups. Group 1 was operated on with initial SO (Oxane 5700) as a corneal lubricant. Group 2 was operated on with initial lactated ringer's solution (LRS) and then replaced with SO as required. Fundus clarity was scored during the surgery. Fluorescein staining was performed to determine the damage to corneal epithelium.

• **RESULTS:** Totally 114 eyes of 114 patients were included. Single SO use maintained a clear cornea and provided excellent visualization of surgical image. In group 1, the fundus clarity was grade 3 in 41/45 eyes and grade 2 in 4/45 eyes. In group 2, corneal edema frequently occurred after initial LRS use. The fundus clarity was grade 3 in 19/69 eyes, 2 in 37/69 eyes and 1 in 13/69 eyes ( $P < 0.05$ ). SO was applied in 29 eyes of initial LRS use with subsequent corneal edema, which eliminated the corneal edema in 26 eyes. Corneal fluorescein staining score in group 1 was 0 in 28 eyes, 1 in 11 eyes and 2 in 6 eyes, and 40, 20 and 9, respectively, in group 2 (all  $P > 0.05$ ).

• **CONCLUSION:** The use of SO as a corneal lubricant is effective and safe for preserving and improving corneal clarity and providing clear surgical field during vitrectomy.

• **KEYWORDS:** silicone oil; corneal lubricant; corneal edema; vitrectomy

DOI:10.18240/ijo.2024.01.12

**Citation:** Che DY, Chan ZL, Zhou JB, Zhu DQ. Silicone oil as a corneal lubricant to reduce corneal edema and improve visualization during vitrectomy. *Int J Ophthalmol* 2024;17(1):92-96

## INTRODUCTION

In addition to retinal-related complications<sup>[1-5]</sup> vitreoretinal surgery can also cause corneal complications<sup>[6]</sup>, including persistent corneal epithelial defects<sup>[7-9]</sup>, diabetic keratopathy<sup>[10-13]</sup>, etc., which are caused by prolonged duration of surgery and intraoperative epithelial debridement. It is well known that corneal edema often occurs during vitreoretinal surgery. If the edema is significant enough to preclude adequate visualization, the intraoperative epithelial debridement may be performed. In a survey to determine the debridement rate during vitrectomy for diabetic patients, the average debridement rate was 17.4% with a range of 0 to 90%<sup>[14]</sup>. This procedure may result in postoperatively ocular discomfort, increased incidence of persistent corneal defect or haze formation, particularly in diabetic patients<sup>[11,13]</sup>.

Recently, with the popular use of a noncontact wide-angle viewing system, various viscoelastic corneal lubricants or antidrying contact lenses were developed to avoid drying<sup>[4,15-23]</sup>. However, they seem powerless to prevent occurrence of corneal edema.

Silicone oils (SO) are synthetic polymers of polydimethylsiloxane, which was first used as an intravitreal implant in the treatment of retinal detachment by Cibis *et al*<sup>[24]</sup>. SO is irreplaceable in treating complicated vitreoretinal diseases<sup>[4,25-27]</sup>, however it has more potential applications. Here we describe the usefulness of SO as a corneal lubricant, which was able to not only maintain a clear cornea, but also reduce corneal edema and thus provide high quality images of surgical field during vitrectomy.

## SUBJECTS AND METHODS

**Ethical Approval** The study followed the tenets of the Declaration of Helsinki and was approved by the hospital Institutional Review Board (SH9H-2022-T33-1). Written informed consent was obtained from all patients before inclusion in the study.

Patients who underwent primary vitreoretinal surgery for epiretinal membrane (ERM), idiopathic macular hole (IMH), rhegmatogenous retinal detachment (RRD) or proliferative diabetic retinopathy (PDR) in Shanghai Ninth People's Hospital, Shanghai Jiao Tong University School of Medicine by same surgeon (Zhu DQ) were included. Cases with preexisting corneal diseases, trauma, glaucoma, uveitis were excluded. These patients were divided into two groups according to the type of corneal lubricant initially used before vitrectomy. Group 1 was operated on with initial SO as a corneal lubricant. Group 2 was operated on with initial lactated ringer's solution (LRS) and then replaced with SO as required. Whether or not the SO was initially used as the corneal lubricant was determined according to surgeon preference. Surgeries were carried out under retrobulbar anesthesia. After a conventional phacoemulsification through a clear corneal incision with or without an intraocular lens implantation into the capsular bag and injection of viscoelastics into the anterior chamber in combined surgery, SO (Oxane 5700; Bausch & Lomb, Rochester, NY, USA) was applied to the corneal surface in group 1 or irrigation with LRS was used in group 2. A standard 23 or 25-gauge pars plana vitrectomy was performed with Constellation<sup>®</sup> Vision System (Alcon Laboratories Inc, Fort Worth, TX, USA) and a noncontact wide-angle viewing system (Resight 500; Carl Zeiss Meditec, Jena, Germany). The infusion solution was LRS. The surgeon advocated complete vitrectomy including vitreous base shaving and removal of vitreous around the internal sclerotomies in each patient. Peripheral vitreous shaving was accomplished with scleral indentation by the surgeon under coaxial illumination of the operating microscope. In PDR, photocoagulation was extended up to the ora serrata. Fundus clarity was subjectively scored during the surgery by the surgeon into 3 grades: grade 3 was sharp or clear. This satisfied easy ERM or internal limiting membrane (ILM) peeling without staining, identification of small holes, direct pressure to control bleeding from retinal neovascularization, or delicate peripheral vitreous shaving and laser burns; grade 2 was unclear but acceptable. In this condition, ILM peeling with staining or identification of small holes with diathermy was required, or difficult dissection of fibrovascular membrane from retina or rough peripheral vitreous shaving and laser treatment was performed; grade 1 was severe hazy as to require removal of the corneal epithelium by scraping or replacement of LRS with SO to accomplish these procedures. For some patients even with grade 2 of fundus clarity, LRS was converted to SO because of difficult and complicated surgical procedures, which was determined at the surgeon's discretion in light of the circumstances.

On the first postoperative day, corneal fluorescein staining (CFS) was performed to determine the damage to corneal

epithelium in both groups. By the Oxford grading scheme developed by Bron *et al*<sup>[28]</sup>, the number of dots stained with fluorescein was counted and scored. If there was no dot the score was 0. If 1-5 dots were seen, the corneal score was 1; 6-30 dots were scored as 2; and >30 dots were scored as 3.

**Statistical Analysis** To compare the patient characteristics between two groups, *t*-test or Mann-Whitney test was used for continuous variables (age and operative time), Chi-square test was used for categorical variables (sex, surgical indications and combined surgery), and Mann-Whitney test was used for ordinal categorical variables (clarity and CFS). Wilcoxon signed-rank test was used to compare the clarity before and after the change of LRS for SO. Statistical software version of SPSS 25.0 was used for all the statistical analyses. A value of  $P < 0.05$  was considered as statistically significant.

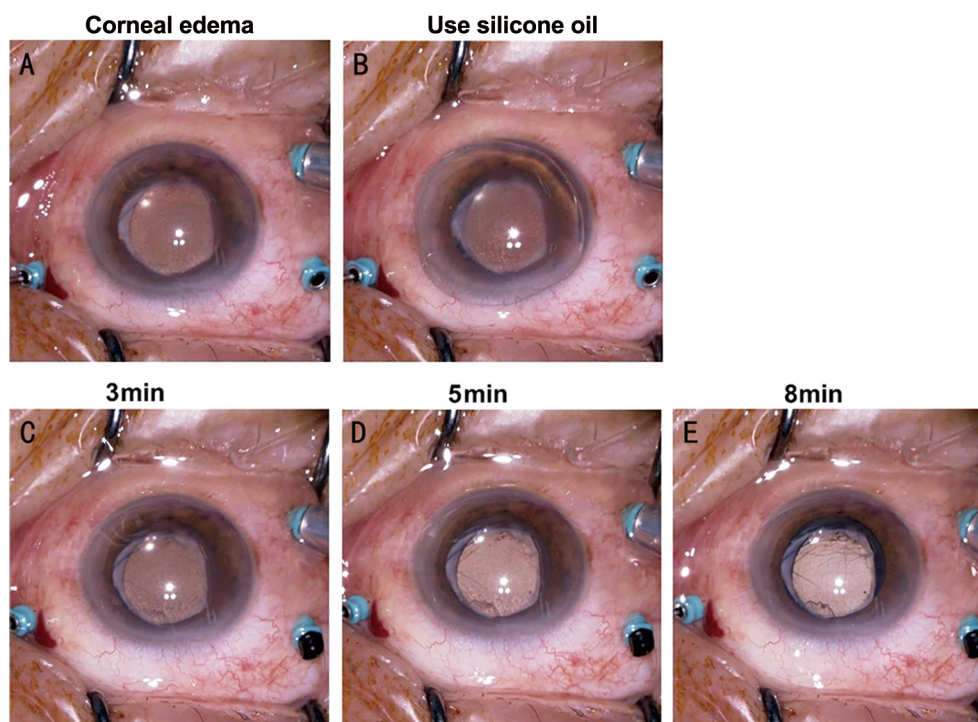
## RESULTS

A total of 114 eyes of 114 consecutive patients were included from April 2020 to September 2020. Patient characteristics are shown in Table 1. The demographic data, surgical indications, and combined surgery were not statistically different between the two groups. Operative time between the two groups was statistically significant.

In the group 1, single application of SO at the beginning of vitrectomy maintained a clear cornea and provided the excellent visualization of the surgical image during the vitrectomy in most eyes. The fundus clarity was grade 3 in 41/45 (91.1%) eyes and grade 2 in 4/45 (8.9%) eyes. However, in the group 2, corneal edema frequently occurred after initial LRS use. The fundus clarity was grade 3 in 19/69 (27.5%) eyes, grade 2 in 37/69 (53.6%) eyes and grade 1 in 13/69 (18.8%) eyes. This difference between the two groups was statistically significant (Table 2). Of particular interest is the replacement of LRS with SO. In some initial LRS eyes (group 2), poor fundus clarity subsequently developed as a result of the corneal edema and SO was then applied in 29 eyes (13 eyes with RRD, 11 eyes with PDR, 5 eyes with ERM/IMH). Several minutes after the application of SO, the edematous and hazy cornea gradually became transparent in 26 eyes and improved in 2 eyes, shown in Figure 1. In the other 1 eye, we removed the edematous epithelium because of irreversible haze and continued to use SO which provided the clear fundus image throughout the subsequent operation. CFS score on the first postoperative day in the group 1 was 0 in 28 (62.2%) eyes, 1 in 11 (24.4%) eyes and 2 in 6 (13.3%) eyes, and 40 (58.0%), 20 (29.0%) and 9 (13.0%), respectively, in the group 2. This difference between the two groups was not statistically significant (Table 2).

## DISCUSSION

Reasons for the development of corneal edema during vitrectomy are multiple<sup>[6-9]</sup>. Despite the current advances in



**Figure 1** Changes in corneal clarity before and after use of SO. Cornea edema occurred during the operation (A). After the application of SO (B), the edema gradually disappeared and the cornea became clear at 3 (C), 5 (D), and 8min (E). SO: Silicone oil.

**Table 1** Characteristics of patients undergoing vitrectomy

Characteristics	Total	Initial SO	Initial LRS	Statistic value	<i>P</i>
Age	114	57.31±14.458	57.86±12.755	-0.211 <sup>a</sup>	0.833
Gender, <i>n</i> (%)				0.945 <sup>b</sup>	0.331
Female	62	27 (43.5)	35 (56.5)		
Male	52	18 (34.6)	34 (65.4)		
Surgical indications, <i>n</i> (%)				0.164 <sup>b</sup>	0.921
RRD	41	17 (41.5)	24 (58.5)		
PDR	43	16 (37.2)	27 (62.8)		
ERM/IMH	30	12 (40)	18 (60)		
Combined surgery, <i>n</i> (%)				3.141 <sup>b</sup>	0.076
Yes	47	14 (29.8)	33 (70.2)		
No	67	31 (46.3)	36 (53.7)		
Operative time (h)	114	1.2 (1.1, 1.4)	1.1 (1.0, 1.2)	953 <sup>c</sup>	<0.001

SO: Silicone oil; LRS: Lactated ringer’s solution; RRD: Rhegmatogenous retinal detachment; PDR: Proliferative diabetic retinopathy; ERM/IMH: Epiretinal membrane/Idiopathic macular hole; <sup>a</sup>*t*-test; <sup>b</sup>Chi-square test; <sup>c</sup>Mann-Whitney test.

**Table 2** Comparison of fundus clarity and CFS scores between group SO and group LRS *n* (%)

Items	Initial SO	Initial LRS	Mann-Whitney <i>U</i>	<i>P</i> <sup>a</sup>
Fundus clarity (scores)			539.5	<0.001
1	0	13 (18.8)		
2	4 (8.9)	37 (53.6)		
3	41 (91.1)	19 (27.5)		
Fluorescein staining (scores)			1497	0.713
0	28 (62.2)	40 (58)		
1	11 (24.4)	20 (29)		
2	6 (13.3)	9 (13)		

CFS: Corneal fluorescein staining; SO: Silicone oil; LRS: Lactated ringer’s solution. <sup>a</sup>Mann-Whitney test between two groups.

microincision vitrectomy systems provide many benefits which include less tissue damage, decreased surgical times, well controlled intraocular pressure and improved visualization, the occurrence of intraoperative corneal edema and opacity is still a challenging problem for retinal surgeons, particularly for novel hands.

The popular use of non contact wide-angle viewing system makes the application of wetting agents necessary. Frequent irrigation with saline solution by an assistant takes effort and proficiency. The viscoelastic corneal lubricants available have the drawbacks of irregular surface, short duration of action and potential toxicity of preservatives. Furthermore, the high cost limits their widely use. The antidrying lenses are not yet commercially available<sup>[17]</sup>. All of them can't prevent the occurrence of corneal edema.

In this study, we found SO had a strong ability to preserve corneal clarity. Not only could the initial use of SO before vitrectomy safely maintain the perfect visibility during the whole procedure, but it also improved the corneal clarity even when used after the occurrence of corneal edema. In most of the cases with initial LRS that developed corneal edema subsequently, the cornea gradually became clear after replacement with SO. However, if the corneal haze was severe enough, SO couldn't reverse the cloudy visibility. This suggests using SO as early as possible, at least before severe corneal edema develops. It should be noted that the operative time was longer in group 1. Considering that the surgical eyes were more severe and more likely to require SO filling, they were chosen to be in group SO. On the other hand, longer operative time did not aggravate the induction of corneal edema, which further proved the preventive effect of SO on corneal edema.

The mechanisms of SO improving corneal clarity are unknown but might be associated with certain properties of SO as follows. First, SO would smooth the irregular corneal surface and decrease light scattering and lead to consequent corneal transparency. Second, SO can dissolve about seven times more oxygen than saline<sup>[29]</sup>. The high oxygen transmissibility and the consequent reservoir of oxygen might help to eliminate the corneal edema. Third, the waterproof property of SO could cause a possible dehydration of the corneal epithelium, which is naturally covered by a hydrophilic tear film.

LRS is widely used for corneal wetting in undeveloped countries to avoid the additional expense of commercial corneal lubricant. SO is commonly used in vitreoretinal surgery and is easily available. It can be repeatedly sterilized and thus cost effective. Single use of SO could lubricate the corneal surface during the entire surgical procedure without relying on the continuous and proficient irrigation by a skilled assistant. The surgeon can independently perform the

unassisted vitrectomy, which is particularly beneficial to some settings where trained assistants aren't readily available, and also helps to save the expense. In addition, SO can rescue the occurrence of corneal edema and improve corneal clarity. The clear surgical field resulting from SO application may enable safer and more efficient surgery, reduce the risk of intraoperative and postoperative complications, enhance the surgeon's satisfaction, and thereby possibly promote a better visual prognosis.

Another advantage of the SO is its potential use for irregular corneal surface. Trauma to the eye, corneal dystrophy, and corneal surgery including refractive surgery can result in irregular corneas, which causes a blurred fundus view. SO can provide unparalleled visibility because SO creates a smooth and regular surface.

In summary, our study demonstrates that the use of SO as a corneal lubricant is quite effective and safe for preserving corneal clarity and providing clear surgical field during vitrectomy, and may make vitrectomy easier and more efficient without an assistant.

#### ACKNOWLEDGEMENTS

**Foundations:** Supported by the Shanghai Key Clinical Specialty, Shanghai Eye Disease Research Center (No.2022ZZ01003); the Science and Technology Commission of Shanghai (No.20DZ2270800).

**Conflicts of Interest:** Che DY, None; Chan ZL, None; Zhou JB, None; Zhu DQ, None.

#### REFERENCES

- 1 Belin PJ, Parke DW 3rd. Complications of vitreoretinal surgery. *Curr Opin Ophthalmol* 2020;31(3):167-173.
- 2 Yoganathan A, Sandinha T, Shamdas M, Diafas A, Steel D. Patient-reported outcome measures in vitreoretinal surgery: a systematic review. *Eye (Lond)* 2023;37(3):391-401.
- 3 Hu YJ, Tang SB. Major challenges in vitreoretinal surgery. *Taiwan J Ophthalmol* 2015;5(1):9-14.
- 4 Sonmez K. Outcomes and predictors of vitrectomy and silicone oil tamponade in retinal detachments complicated by proliferative vitreoretinopathy. *Int J Ophthalmol* 2022;15(8):1279-1289.
- 5 Ribeiro L, Oliveira J, Kuroiwa D, Kolko M, Fernandes R, Junior O, Moraes N, Vasconcelos H, Oliveira T, Maia M. Advances in vitreoretinal surgery. *J Clin Med* 2022;11(21):6428.
- 6 Sepulveda-Beltran PA, Levine H, Chang VS, Gibbons A, Martinez JD. Complications in retinal surgery: a review of corneal changes following vitreoretinal procedures. *Int Ophthalmol Clin* 2022;62(3):65-77.
- 7 Sarici K, Martin A, Yuan A, Goshe JM, Srivastava SK, Reese JL, Ehlers JP. Corneal epithelial defects following vitreoretinal surgery: incidence and outcomes from the DISCOVER study. *Int J Ophthalmol* 2022;15(1):83-88.
- 8 Chiang WY, Lee JJ, Kuo HK, Chen YH, Chen CH, Chen YJ, Wu PC, Chen YW. Factors associated with corneal epithelial defects after pars

- plana vitrectomy. *Int Ophthalmol* 2018;38(1):105-110.
- 9 Chen HF, Yeung L, Yang KJ, Sun CC. Persistent corneal epithelial defect after pars Plana vitrectomy. *Retina* 2016;36(1):148-155.
- 10 Han SB, Yang HK, Hyon JY. Influence of diabetes mellitus on anterior segment of the eye. *Clin Interv Aging* 2018;14:53-63.
- 11 Guzel B, Oshitari T, Baba T, Mukharram B, Yamamoto S. Diabetic corneal neuropathy: clinical perspectives. *Clin Ophthalmol* 2018;12:981-987.
- 12 Barsegian A, Kotlyar B, Lee J, Salifu MO, McFarlane SI. Diabetic retinopathy: focus on minority populations. *Int J Clin Endocrinol Metab* 2017;3(1):034-045.
- 13 Hiraoka M, Amano S, Oshika T, Kato S, Hori S. Factors contributing to corneal complications after vitrectomy in diabetic patients. *Jpn J Ophthalmol* 2001;45(5):492-495.
- 14 Friberg TR, Ohji M, Scherer JJ, Tano Y. Frequency of epithelial debridement during diabetic vitrectomy. *Am J Ophthalmol* 2003;135(4):553-554.
- 15 Garcia-Valenzuela E, Abdelsalam A, Elliott D, Pons M, Iezzi R, Puklin JE, McDermott ML, Abrams GW. Reduced need for corneal epithelial debridement during vitreo-retinal surgery using two different viscous surface lubricants. *Am J Ophthalmol* 2003;136(6):1062-1066.
- 16 Siegel DT, Hubbard GB, Yan J, Cribbs B, Jain N, Yeh S, Bui D, Smith J, Barb S, Pearce W, Ward L, Hendrick AM. Effect of lubricants on corneal thickness after vitrectomy. *Retina* 2020;40(8):1616-1622.
- 17 Ohno H, Inoue K. An antidrying corneal contact lens for a noncontact wide-angle viewing system. *Retina* 2011;31(7):1435-1436.
- 18 Pan QT, Gao ZQ, Chen XH, Yang ZW, Huang SH, Hu XT, Zheng JW, Zhang ZD. Outcomes of a novel bubble ultra-wide field viewing system for vitreoretinal surgery. *Acta Ophthalmol* 2022;100(4):e1024-e1030.
- 19 Chihara T, Kita M. New type of antidrying lens for vitreous surgery with a noncontact wide-angle viewing system. *Clin Ophthalmol* 2013;7:353-355.
- 20 Hu ZZ, Ding YZ, Zheng XH, Yuan ST, Li J, Xie P, Liu QH. Thin rigid contact lens used in vitreous-retinal surgery for corneal protection: a randomized controlled trial. *Eye Contact Lens* 2018;44(Suppl 2):S355-S360.
- 21 Kita M, Fujii Y, Hama S. A new lens for observing fundus with a noncontact wide-angle viewing system. *Clin Ophthalmol* 2017;11:1239-1244.
- 22 Sadeghi E, Mohan S, Iannetta D, Chhablani J. Recent developments in imaging and surgical vision technologies currently available for improving vitreoretinal surgery: a narrative review. *Expert Rev Med Devices* 2023;20(8):651-672.
- 23 Weschta M, Klaas JE, Feucht N, Lohmann CP, Maier M. Microstructural morphology and visual acuity outcome in eyes with epiretinal membrane before, during, and after membrane peeling in intraoperative optical coherence tomography assisted macular surgery. *Int J Ophthalmol* 2023;16(5):748-754.
- 24 Cibis PA, Becker B, Okun E, Canaan S. The use of liquid silicone in retinal detachment surgery. *Arch Ophthalmol* 1962;68(5):590-599.
- 25 Chen Y, Kearns VR, Zhou LY, Sandinha T, Lam WC, Steel DH, Chan YK. Silicone oil in vitreoretinal surgery: indications, complications, new developments and alternative long-term tamponade agents. *Acta Ophthalmol* 2021;99(3):240-250.
- 26 Ferrara M, Coco G, Sorrentino T, et al. Retinal and corneal changes associated with intraocular silicone oil tamponade. *J Clin Med* 2022;11(17):5234.
- 27 Yin L, Jin X, Jia LA, Wang FX. Comparison of outcomes of idiopathic macular holes treated by vitrectomy with air or silicone oil tamponade based on the hole size. *Int J Ophthalmol* 2022;15(8):1305-1309.
- 28 Bron AJ, Evans VE, Smith JA. Grading of corneal and conjunctival staining in the context of other dry eye tests. *Cornea* 2003;22(7):640-650.
- 29 Refojo MF, Roldan M, Leong FL, Henriquez AS. Effect of silicone oil on the cornea. *J Biomed Mater Res* 1985;19(6):643-652.