

Intravitreal conbercept injection with panretinal photocoagulation for high-risk proliferative diabetic retinopathy with vitreous hemorrhage

Yao Xu¹, Qing Ye², Wei Shen³

¹Department of Ophthalmology, the Fourth Affiliated Hospital of Soochow University, Suzhou 215000, Jiangsu Province, China

²Department of Ophthalmology, Suzhou Kowloon Hospital, Shanghai Jiao Tong University School of Medicine, Suzhou 215000, Jiangsu Province, China

³Department of Ophthalmology, the First Affiliated Hospital of Soochow University, Suzhou 215000, Jiangsu Province, China
Correspondence to: Qing Ye. No.118, Wansheng Street, Suzhou 215000, Jiangsu Province, China. 39005294@qq.com; Wei Shen. No.188, Shizi Street, Suzhou 215000, Jiangsu Province, China. guderian@suda.edu.cn

Received: 2023-11-26 Accepted: 2023-12-28

Abstract

• **AIM:** To assess the clinical efficacy and safety of combining panretinal photocoagulation (PRP) with intravitreal conbercept (IVC) injections for patients with high-risk proliferative diabetic retinopathy (HR-PDR) complicated by mild or moderate vitreous hemorrhage (VH), with or without diabetic macular edema (DME).

• **METHODS:** Patients diagnosed with VH with/without DME secondary to HR-PDR and received PRP combined with IVC injections were recruited in this retrospective study. Upon establishing the patient's diagnosis, an initial IVC was performed, followed by prompt administration of PRP. In cases who significant bleeding persisted and impeded the laser operation, IVC was sustained before supplementing with PRP. Following the completion of PRP, patients were meticulously monitored for a minimum of six months. Laser therapy and IVC injections were judiciously adjusted based on fundus fluorescein angiography (FFA) results. Therapeutic effect and the incidence of adverse events were observed.

• **RESULTS:** Out of 42 patients (74 eyes), 29 were male and 13 were female, with a mean age of 59.17±12.74y (33-84y). The diabetic history was between 1wk and 26y, and the interval between the onset of visual symptoms and diagnosis of HR-PDR was 1wk-1y. The affected eye received 2.59±1.87 (1-10) IVC injections and underwent 5.5±1.02

(4-8) sessions of PRP. Of these, 68 eyes received PRP following 1 IVC injection, 5 eyes after 2 IVC injections, and 1 eye after 3 IVC injections. Complete absorption of VH was observed in all 74 eyes 5-50wk after initial treatment, with resolution of DME in 51 eyes 3-48wk after initial treatment. A newly developed epiretinal membrane was noted in one eye. Visual acuity significantly improved in 25 eyes. No complications such as glaucoma, retinal detachment, or endophthalmitis were reported.

• **CONCLUSION:** The study suggests that the combination of PRP with IVC injections is an effective and safe modality for treating diabetic VH in patients with HR-PDR.

• **KEYWORDS:** conbercept; panretinal photocoagulation; high-risk proliferative diabetic retinopathy; vitreous hemorrhage

DOI:10.18240/ijo.2024.06.11

Citation: Xu Y, Ye Q, Shen W. Intravitreal conbercept injection with panretinal photocoagulation for high-risk proliferative diabetic retinopathy with vitreous hemorrhage. *Int J Ophthalmol* 2024;17(6):1066-1072

INTRODUCTION

Contemporarily, diabetic retinopathy (DR) has been the primary cause of preventable blindness among middle-aged adults^[1-5]. The global prevalence of DR is estimated at 22.27% within the diabetic population^[6-10]. Timely diagnosis and intervention in DR, coupled with efforts to mitigate the incidence and advancement of high-risk proliferative diabetic retinopathy (HR-PDR), are pivotal in reducing the prevalence of blindness^[11-14]. Key modalities for DR treatment encompass laser photocoagulation, pharmaceutical interventions, and pars plana vitrectomy (PPV)^[5,15-16].

Nowadays, panretinal photocoagulation (PRP) is still the standard treatment for PDR^[17-19]. PRP exerts its therapeutic effect by reducing oxygen demand in the retina, thus preventing the development of neovascularization (NV). Additionally, it diminishes the level of vascular endothelial growth factor (VEGF), inducing the regression of retinal

NV, alleviating retinal edema, and subsequently impeding the progression of vision loss^[20]. Concurrently, the advent of anti-VEGF drugs has revolutionized the management of DR by directly targeting its pathogenic mechanisms. At present, intravitreal injection of anti-VEGF agents is predominantly employed to enhance patients' visual outcomes and establish conditions conducive to delaying disease progression^[21-23]. A notable advancement in this domain is conbercept, a new generation of anti-VEGF drug independently developed in China^[24-26]. This multi-target VEGF receptor, generated through the hamster ovary cell expression system, effectively inhibits the proliferation, angiogenesis, and vascular endothelial cell leakage by blocking the signaling pathway of VEGF family receptors. Consequently, conbercept has garnered widespread usage in the treatment of DR in China.

At present, doctors tend to lean towards PPV as the preferred option for HR-PDR patients presenting with vitreous hemorrhage (VH)^[16,27-28]. Although PPV can preserve some degree of vision, it is accompanied by risks, being a procedure that is both invasive and costly. Moreover, there remains a possibility of post-operative complications, including recurrent VH, the formation of proliferative membranes, and retinal detachment. The choice of tamponade, whether silicone oil or gas, can give rise to further complexities, potentially leading to complications such as cataract, secondary glaucoma, and endophthalmitis. Additionally, following PPV, alterations to the original structure of the vitreous cavity may heighten the complexity and risk associated with subsequent surgeries involving adjacent tissues, such as cataract surgery^[29-32]. For patients navigating these considerations, the question arises: can we achieve the objective of halting the disease's progression through the combined approach of PRP and intravitreal conbercept (IVC) injections?

Currently, there are numerous studies on the combination of PRP with intravitreal injections of anti-VEGF for treating PDR. However, the majority of research focuses on patients with severe non-proliferative DR, early-stage PDR, or diabetic macular edema (DME)^[33-36]. HR-PDR patients, particularly those with VH who meet the criteria for PPV surgery, have been seldom explored in the literature^[27,37-38]. To address this gap, we conducted a retrospective study to assess the therapeutic efficacy of combining PRP with IVC in HR-PDR patients experiencing VH.

SUBJECTS AND METHODS

Ethical Approval This retrospective study was conducted in accordance with the Tenets of the Helsinki Declaration and was approved by the Ethics Committee of the First Affiliated Hospital of Soochow University [No.(2022)436]. Written informed consent was obtained from all patients included in the study.

Study Design and Participants Participants in this study were treatment-naïve HR-PDR patients complicated by mild or moderate VH with or without DME, who were diagnosed and treated at the Department of Ophthalmology, the First Affiliated Hospital of Soochow University, between January 2021 and June 2022.

According to its severity, PDR can be divided into early-stage PDR and HR-PDR. High-risk characteristics, as per the standard formulated by the Diabetic Retinopathy Study Group in the United States^[39], include: 1) presence of moderate to severe NV on the disc (NVDs) with 1/4-1/3 disc area in size or larger; 2) less extensive NVD, if vitreous or pre-retinal hemorrhage is present; 3) NV of elsewhere (NVE) $\geq 1/2$ disc area, if vitreous or pre-retinal hemorrhage is present. In this study, we utilized a semi-quantitative classification of VH: mild amount, the bleeding is limited to 55° in fundus photography with mydriasis mode; moderate amount-the bleeding is more than one 55° but less than two 55° .

Inclusion criteria: 1) Patients with type 2 diabetes mellitus (DM) under stable treatment during the study, aged 18y or older, with no significant underlying systemic diseases (such as impaired renal function, severe cardiac disease, *etc.*); 2) fluorescein angiography (FFA) confirming HR-PDR, combined with mild or moderate VH as mentioned earlier, with or without DME, and sufficient media clarity to perform laser treatment; 3) absence of severe media opacities; 4) individuals who are unwilling to undergo PPV.

Exclusion criteria: 1) presence of retinal vascular occlusion, age-related macular degeneration, retinal angioma, uveitis, glaucoma, optic neuropathy, or other ocular diseases that can lead to VH and/or affect vision; 2) previous treatment with PRP, anti-VEGF agents, or corticosteroids before this visit; 3) presence of vitreous macular traction; 4) presence of patients with severe or extensive VH, and traction retinal detachment need to be performed with vitrectomy.

Methods All participants in the study had undergone a complete ophthalmological examination before treatment, which included measurements of best-corrected visual acuity (BCVA) with logMAR chart, intraocular pressure, biomicroscopy, dilated funduscopy, optical coherence tomography (OCT), fundus photography, B-scan, and FFA. Systemic investigation included a history of DM, fasting blood sugar, glycated hemoglobin (HbA1c), blood pressure, serum lipid profile, and renal function tests.

As soon as the patient's diagnosis was established, one IVC injection was administered, followed by PRP as promptly as possible. If significant bleeding still affected the laser operation, IVC was continued, and then supplemented with PRP. Following the completion of PRP, patients were followed up for at least 6mo. BCVA, fundus photography, and OCT

were reviewed at each follow-up. FFA was reviewed 3mo after the initial IVC, and subsequently during follow-ups based on retinal conditions. Laser therapy was timely administered based on FFA results. The observation period ranged from 0.5 to 1.5y. The treatment endpoint was defined as stable condition, absorption of VH, and absence of new non-perfusion areas (NPAs) and NV as indicated in FFA. Criteria for evaluating changes in vision were as follows: 1) Vision improvement: an increase in vision by 2 lines or more. 2) Vision unchanged: maintenance or minimal change in visual acuity. 3) Vision loss: a decrease in vision by more than 2 lines. At the end of treatment, an improvement in BCVA of 2 lines or more was considered the criterion for effective treatment.

Intravitreal Conbercept Injection Levofloxacin eye drops (Yangzijiang Pharmaceutical Group Co., Ltd., China, approval number: H20203092) were administered to both eyes four times a day, commencing three days prior to the IVC injection. During the procedure, the patient was positioned supine and fully anesthetized using proparacaine hydrochloride eye drops (s.a.ALCON-COUVREUR n.v, USA; approval number: HJ20160133). The conjunctival sac was cleansed with 5% povidone iodine, and the needle was inserted vertically at a distance of 3.50 to 4.0 mm from the limbus, avoiding the 3 and 9 o'clock positions. Subsequently, 0.05 mL (0.5 mg) of conbercept (Chengdu Kanghong Biotechnology Co., Ltd., China, approval number: S20130012) was gently injected into the vitreous cavity. At the conclusion of the procedure, light sensation was detected in the operative eye. Levofloxacin eye drops were then administered for an additional five days.

Panretinal Photocoagulation After the IVC injection, patients received their initial session of PRP one week later. Prior to the procedure, compound tropicamide eye drops (Santen Pharmaceutical Co., Ltd., Japan; approval number: J20180051) were administered to fully dilate pupils, and topical anesthesia was achieved using proparacaine hydrochloride eye drops. The Zeiss multi-wavelength ophthalmic laser therapeutic instrument (VISULAS Trion, Germany) was selected for the laser treatment, primarily employing a 561 nm wavelength. In cases of severe VH, cataract, or preretinal hemorrhage, the wavelength was adjusted to 659 nm. PRP settings were as follows: exposure time ranged from 180-220ms, energy parameter was set between 180-300 mW, spot diameter varied from 200-300 μ m, and a spacing between spots was maintained. A total of 1500-2500 laser spots were applied with the objective of achieving gray-white lesions. The photocoagulation range encompassed the upper and lower sides delimited by the vascular arch. The nasal side extended 1 optic disc diameter (PD) away from the optic disc, while the temporal side reached 2 PD away from the fovea macula, extending forward beyond the equator towards the far peripheral region. Photocoagulation commenced in

the unobstructed segment of the VH, with a preference for photocoagulation around the retinal proliferative lesions. Focal photocoagulation was applied in the NPAs identified by FFA. PRP was concluded in four or more sessions, with an interval of at least one week between sessions. All procedures were conducted by a skilled ophthalmologist. FFA was reviewed three months post laser photocoagulation, and if NPAs or NVs were detected, retreatment was initiated.

RESULTS

In this study, 42 patients (74 eyes) with HR-PDR complicated by mild or moderate VH, with or without DME, were recruited (Table 1). Among them, there were 29 males with 53 affected eyes, 13 females with 21 affected eyes, 10 patients with one eye affected, and 32 patients with both eyes affected, with a mean age of 59.17 ± 12.74 y (ranging from 33 to 84y). The diabetic history was between 1wk and 26y, and the interval between the onset of visual symptoms and the diagnosis of HR-PDR was 1wk to 1y. Among the participants, 15 patients had stable blood glucose control before the study, while 27 patients had unstable blood glucose control, including 28 patients with hypertension and/or hyperlipidemia. During the first visit, VH with DME was observed in 71 eyes, and VH with epiretinal membrane (ERM) was observed in 30 eyes. The logMAR BCVA at the initial visit ranged from 2.3 to 0.2 for those with DME and from 0.2 to 1.0 for those without DME.

Throughout the entire study period, none of the patients encountered significant complications such as glaucoma, retinal detachment, or endophthalmitis. Each affected eye received 2.59 ± 1.87 (1 to 10) IVC injections and underwent 5.5 ± 1.02 (4 to 8) sessions of laser photocoagulation (Table 1). Sixty-eight eyes were treated with laser photocoagulation after receiving 1 injection of IVC, 5 eyes were treated with laser after receiving 2 injections of IVC, and 1 eye was treated with laser after receiving 3 injections of conbercept.

By the end of the follow-up, VH was absorbed in all 74 eyes (post-initial treatment for 5 to 50wk), DME subsided in 51 eyes (post-initial treatment for 3 to 48wk), and new ERM was found in 1 eye, the BCVA ranged from 2.3 to 0 for patients with DME and from 0.5 to 0.1 for patients without DME (Table 1). Most of the patients' BCVA showed improvement, including 19 patients (25 eyes) whose BCVA significantly improved, and 41 eyes whose BCVA remained unchanged. A typical case is shown in Figure 1.

During the study, 7 patients (7 eyes) experienced either cataract aggravation or developed post-cataract conditions. Additionally, one patient (1 eye) experienced a new instance of VH after undergoing retinal laser photocoagulation. However, the patient's visual acuity gradually improved after receiving supplemental IVC injections and subsequent retinal laser photocoagulation.

Table 1 Baseline parameters, treatment frequency, and outcomes of the 42 patients enrolled in the study

Characteristics	Data
Age (mean±SD), y	59.17±12.74
Gender	
Male	29
Female	13
Eyes	
Right eye	38
Left eye	36
Diagnosis of DM (range)	1wk-26y
HbA1c (%)	
<8	15
≥8	27
Initial BCVA (logMAR)	
With DME	2.3-0.2
Without DME	1.0-0.2
VH Grading	
Mild	34
Moderate	40
Eyes with DME	71
Eyes with ERM	30
Lens status	
Phakic	71
Pseudophakic	3
Presence of hypertension and/or hyperlipidemia	28
IVC injections (n, mean±SD)	2.59±1.87
Laser photocoagulation sessions (n, mean±SD)	5.5±1.02
VH absorption	74
DME resolution	51
New ERM onset	1
Final BCVA (logMAR)	
With DME	2.3-0
Without DME	0.5-0.1
Cataract aggravation or post-cataract	7

DM: Diabetes mellitus; HbA1c: Glycated hemoglobin; BCVA: Best-corrected visual acuity; VH: Vitreous hemorrhage; DME: Diabetic macular edema; ERM: Epiretinal membrane; IVC: Intravitreal conbercept.

DISCUSSION

As the advanced stage of DR with poor treatment efficacy and high rates of blindness, HR-PDR poses a significant challenge to ophthalmologists. Therefore, the treatment for HR-PDR requires extreme caution. It is necessary to comprehensively consider the patient's systemic and ocular situation, the patient's compliance and willingness, and the strength of the medical institutions and ophthalmology specialty.

Current treatment strategies for DR include laser photocoagulation, anti-VEGF therapy and surgery. PPV for HR-PDR patients with VH is widely recognized. However, a few patients are

reluctant to undergo surgery due to factors like tomophobia and religious beliefs. Simultaneously, doctors in primary hospitals in low-income countries may lack the necessary resources for PPV surgery. We conducted a retrospective evaluation of the therapeutic outcomes of combining PRP with IVC injections for HR-PDR patients, providing a positive directive for clinical practice.

The HR-PDR patients with ERM enrolled in this study, characterized by their minor proliferation, demonstrated no discernible influence on the outcomes of laser photocoagulation and intravitreal injection^[40-42]. Additionally, our choice of conbercept was deliberate. This therapeutic agent not only mirrors the effects of conventional anti-VEGF drugs in targeting VEGF-A and VEGF-B, but also boasts a distinctive anti-placental growth factor (PLGF) function. This dual-mode of action equips conbercept to proficiently impede the proliferation and migration of endothelial cells, curtail inflammatory cell infiltration, and protract the formation of fibrous proliferative membranes in patients with PDR^[43-47].

In this study, middle-aged and elderly HR-PDR patients with VH, often with unstable blood sugar history and systemic complications, highlight the need for vigilant ocular monitoring in those with prolonged disease, advanced age, and suboptimal glucose control. VH severity doesn't strongly relate to visual outcomes; rather, the timing of treatment holds more importance. Initial macular edema diagnosis associates with poorer visual acuity, but post-treatment, significant visual improvement occurs, potentially due to enhanced vision post-edema resolution.

We initiate laser treatment in unobstructed areas, proceeding to complete PRP as the hemorrhage is absorbed. The complexity of performing PRP remains unaffected. It is important to note that one of the included patients experienced a new occurrence of ERM during the treatment period. This may be indicative of a progression in the course of PDR itself or potentially linked to our therapeutic regimen. Further prospective research is warranted to validate this observation^[48-50].

Throughout the course of treatment, potential occurrences such as new VH, exacerbation of pre-existing cataracts, and post-cataract development may contribute to a decline in the patient's visual acuity. Hence, maintaining open and thorough communication between healthcare providers and patients is imperative in order to mitigate potential conflicts. It is pertinent to note that none of our patients encountered severe complications, a circumstance likely attributed to the retrospective nature of the study itself. Nonetheless, in active clinical practice, it remains essential to remain vigilant regarding the potential for serious complications.

In our study, we tailored the timing and sequence of treatment based on individual ocular conditions, affording flexibility,

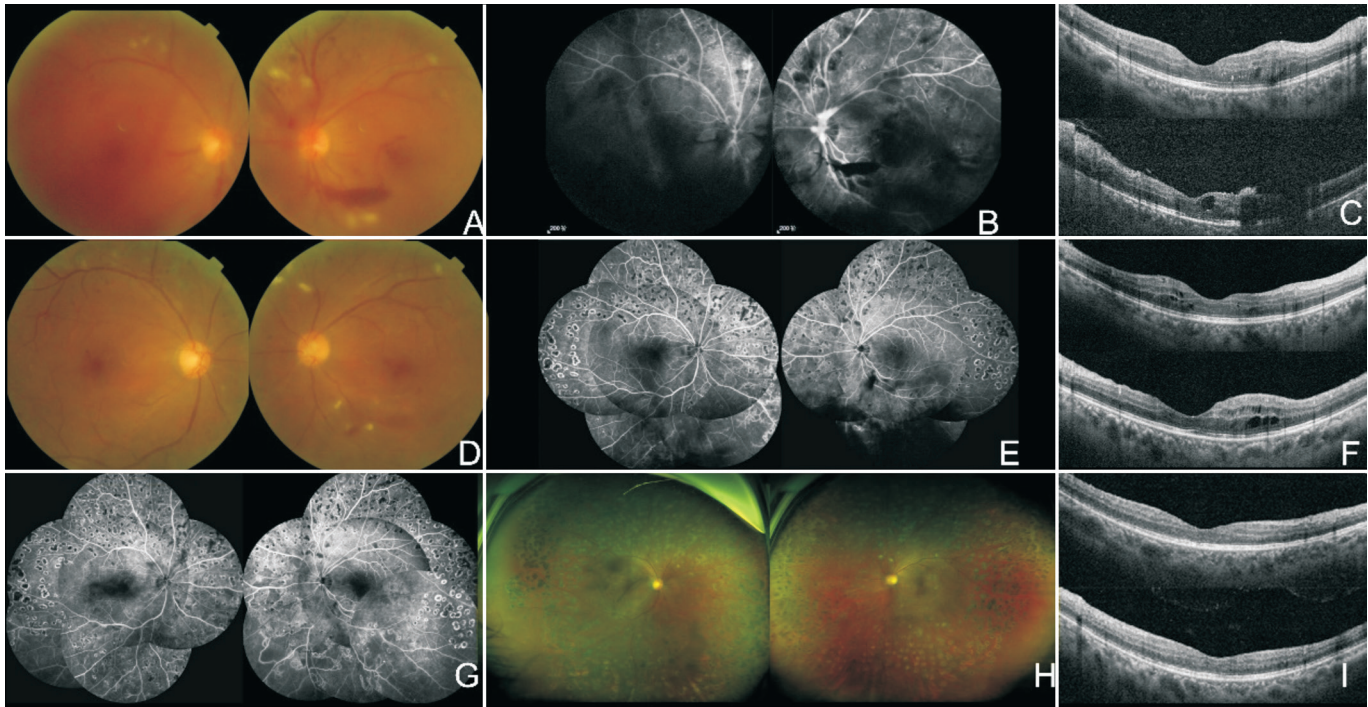


Figure 1 A 34-year-old male patient and HR-PDR with VH received PRP combined with IVC treatment A: At the first visit, logMAR BCVA was 1.1 in the right eye and 1.2 in the left eye. Color fundus images showed opacities in both eyes with VH and cotton wool spots. B: FFA revealed fluorescent shading due to VH, with numerous microaneurysms, NPAs, and fluorescence leakage observed in the retina. C: OCT showed intraretinal fluid in both eyes. D-E: Three months after the initial visit, both eyes received three IVC injections and PRP. Fundus imaging showed that most of the VH had been absorbed, with a small amount of bleeding and exudation observed in the retina. FFA showed bleeding and retinal NPAs without NV. F: Eight months later, new macular edema was observed in both eyes, and three IVC injections were administered in both eyes over six months. G: Sixteen months later, logMAR BCVA was 0 in the right eye and 0.3 in the left eye. FFA showed NPAs in the inferior part of the left eye. H-I: Eighteen months later, ultra-wide-field scanning laser ophthalmoscopic images revealed no VH, or exudation. OCT showed normal macula in both eyes. BCVA: Best-corrected visual acuity; FFA: Fundus fluorescein angiography; VH: Vitreous hemorrhage; NPAs: Non-perfusion areas; OCT: Optical coherence tomography; IVC: Intravitreal conbercept; PRP: Panretinal photocoagulation; NV: Neovascularization; HR-PDR: High-risk proliferative diabetic retinopathy.

efficiency, and cost-effectiveness. This was particularly beneficial for PDR patients who met the criteria for PPV but opted not to undergo surgery. This approach resulted in a high level of patient satisfaction and yielded commendable social benefits.

Limitations of this study include its retrospective design. All patients expressed reluctance to undergo vitrectomy and proceeded only after extensive discussions and obtaining informed consent, which could potentially introduce bias. Furthermore, there was a lack of baseline matching for patients undergoing PPV, serving as a control group. The duration of follow-up in this study was relatively short, emphasizing the necessity for a long-term, prospective, controlled study to more conclusively validate the safety and efficacy of this treatment approach.

In summary, the combination of PRP with IVC injections effectively facilitates the absorption of VH, alleviates macular edema, enhances patients' vision, and potentially allows certain PDR patients to circumvent the necessity of vitrectomy.

ACKNOWLEDGEMENTS

Authors' contributions: Shen W, Ye Q, and Xu Y had full access to all the data in the study and take responsibility for the integrity of the data and the accuracy of the data analysis. Concept and design: Ye Q and Xu Y. Acquisition, analysis, or interpretation of data: Shen W and Xu Y.

Foundation: Supported by Research Grants from the fund of Suzhou Kowloon Hospital (No.SZJL202106).

Conflicts of Interest: Xu Y, None; Ye Q, None; Shen W, None.

REFERENCES

- Cheung N, Mitchell P, Wong TY. Diabetic retinopathy. *Lancet* 2010;376(9735):124-136.
- Eisma JH, Dulle JE, Fort PE. Current knowledge on diabetic retinopathy from human donor tissues. *World J Diabetes* 2015;6(2):312-320.
- Flaxman SR, Bourne RRA, Resnikoff S, Ackland P, Braithwaite T, Cicinelli MV, Das A, Jonas JB, Keeffe J, Kempen JH, Leasher J, Limburg H, Naidoo K, Pesudovs K, Silvester A, Stevens GA, Tahhan N, Wong TY, Taylor HR, Vision Loss Expert Group of the Global

- Burden of Disease Study. Global causes of blindness and distance vision impairment 1990-2020: a systematic review and meta-analysis. *Lancet Glob Health* 2017;5(12):e1221-e1234.
- 4 Song PG, Yu JY, Chan KY, Theodoratou E, Rudan I. Prevalence, risk factors and burden of diabetic retinopathy in China: a systematic review and meta-analysis. *J Glob Health* 2018;8(1):010803.
- 5 Pandit S, Ho AC, Yonekawa Y. Recent advances in the management of proliferative diabetic retinopathy. *Curr Opin Ophthalmol* 2023;34(3):232-236.
- 6 Raman R, Gupta A, Krishna S, Kulothungan V, Sharma T. Prevalence and risk factors for diabetic microvascular complications in newly diagnosed type II diabetes mellitus. Sankara Nethralaya Diabetic Retinopathy Epidemiology and Molecular Genetic Study (SN-DREAMS, report 27). *J Diabetes Complications* 2012;26(2):123-128.
- 7 Jee D, Lee WK, Kang S. Prevalence and risk factors for diabetic retinopathy: the Korea National Health and Nutrition Examination Survey 2008-2011. *Invest Ophthalmol Vis Sci* 2013;54(10):6827-6833.
- 8 Kostev K, Rathmann W. Diabetic retinopathy at diagnosis of type 2 diabetes in the UK: a database analysis. *Diabetologia* 2013;56(1):109-111.
- 9 Dehghan MH, Katibeh M, Ahmadi H, Nourinia R, Yaseri M. Prevalence and risk factors for diabetic retinopathy in the 40 to 80 year-old population in Yazd, Iran: the Yazd Eye Study. *J Diabetes* 2015;7(1):139-141.
- 10 Teo ZL, Tham YC, Yu M, Chee ML, Rim TH, Cheung N, Bikbov MM, Wang YX, Tang YT, Lu Y, Wong IY, Ting DSW, Tan GSW, Jonas JB, Sabanayagam C, Wong TY, Cheng CY. Global prevalence of diabetic retinopathy and projection of burden through 2045: systematic review and meta-analysis. *Ophthalmology* 2021;128(11):1580-1591.
- 11 Jin PY, Peng JJ, Zou HD, Wang WW, Fu J, Shen BJ, Bai XL, Xu X, Zhang X. A five-year prospective study of diabetic retinopathy progression in Chinese type 2 diabetes patients with "well-controlled" blood glucose. *PLoS One* 2015;10(4):e0123449.
- 12 Wong TY, Sabanayagam C. The war on diabetic retinopathy: where are we now? *Asia Pac J Ophthalmol (Phila)* 2019;8(6):448-456.
- 13 Perais J, Agarwal R, Evans JR, Loveman E, Colquitt JL, Owens D, Hogg RE, Lawrenson JG, Takwoingi Y, Lois N. Prognostic factors for the development and progression of proliferative diabetic retinopathy in people with diabetic retinopathy. *Cochrane Database Syst Rev* 2023;2(2):CD013775.
- 14 Fu P, Huang YL, Wan XB, Zuo HY, Yang Y, Shi RS, Huang ML. Efficacy and safety of pan retinal photocoagulation combined with intravitreal anti-VEGF agents for high-risk proliferative diabetic retinopathy: a systematic review and meta-analysis. *Medicine (Baltimore)* 2023;102(39):e34856.
- 15 Wang W, Lo ACY. Diabetic retinopathy: pathophysiology and treatments. *Int J Mol Sci* 2018;19(6):1816.
- 16 Berrocal MH, Acaba-Berrocal L. Early pars Plana vitrectomy for proliferative diabetic retinopathy: update and review of current literature. *Curr Opin Ophthalmol* 2021;32(3):203-208.
- 17 Ghanchi F, Diabetic Retinopathy Guidelines Working Group. The Royal College of Ophthalmologists' clinical guidelines for diabetic retinopathy: a summary. *Eye (Lond)* 2013;27(2):285-287.
- 18 Wong TY, Sun J, Kawasaki R, Ruamviboonsuk P, Gupta N, Lansingh VC, Maia M, Mathenge W, Moreker S, Muqit MMK, Resnikoff S, Verdager J, Zhao PQ, Ferris F, Aiello LP, Taylor HR. Guidelines on diabetic eye care the international council of ophthalmology recommendations for screening, follow-up, referral, and treatment based on resource settings. *Ophthalmology* 2018;125(10):1608-1622.
- 19 Flaxel CJ, Adelman RA, Bailey ST, Fawzi A, Lim JI, Vemulakonda GA, Ying GS. Diabetic retinopathy preferred practice pattern®. *Ophthalmology* 2020;127(1):P66-P145.
- 20 Ting DSW, Wong TY. Proliferative diabetic retinopathy: laser or eye injection? *Lancet* 2017;389(10085):2165-2166.
- 21 Fogli S, del Re M, Rofi E, Posarelli C, Figus M, Danesi R. Clinical pharmacology of intravitreal anti-VEGF drugs. *Eye (Lond)* 2018;32(6):1010-1020.
- 22 Xu Y, Xie C, Fang Y, Yu Y, Qiu C. Optimal timing of preoperative intravitreal anti-VEGF injection for proliferative diabetic retinopathy patients. *Int J Ophthalmol* 2022;15(10):1619-1626.
- 23 Zehden JA, Mortensen XM, Reddy A, Zhang AY. Systemic and ocular adverse events with intravitreal anti-VEGF therapy used in the treatment of diabetic retinopathy: a review. *Curr Diab Rep* 2022;22(10):525-536.
- 24 Li XX, Xu GZ, Wang YS, Xu X, Liu XL, Tang SB, Zhang F, Zhang JJ, Tang LS, Wu Q, Luo DL, Ke X, AURORA Study Group. Safety and efficacy of conbercept in neovascular age-related macular degeneration: results from a 12-month randomized phase 2 study: AURORA study. *Ophthalmology* 2014;121(9):1740-1747.
- 25 Nguyen TT, Guymer R. conbercept (KH-902) for the treatment of neovascular age-related macular degeneration. *Expert Rev Clin Pharmacol* 2015;8(5):541-548.
- 26 Zhang X, Wu C, Zhou LJ, Dai RP. Observation of optic disc neovascularization using OCT angiography in proliferative diabetic retinopathy after intravitreal conbercept injections. *Sci Rep* 2018;8(1):3972.
- 27 Figueira J, Fletcher E, Massin P, Silva R, Bandello F, Midena E, Varano M, Sivaprasad S, Eleftheriadis H, Menon G, Amaro M, Ayello Scheer S, Creuzot-Garcher C, Nascimento J, Alves D, Nunes S, Lobo C, Cunha-Vaz J. Ranibizumab plus panretinal photocoagulation versus panretinal photocoagulation alone for high-risk proliferative diabetic retinopathy (PROTEUS study). *Ophthalmology* 2018;125(5):691-700.
- 28 Lin TZ, Kong Y, Shi C, Eric Pazo E, Dai GZ, Wu XW, Xu L, Shen LJ. Prognosis value of Chinese Ocular Fundus Diseases Society classification for proliferative diabetic retinopathy on postoperative visual acuity after pars Plana vitrectomy in type 2 diabetes. *Int J Ophthalmol* 2022;15(10):1627-1633.
- 29 Bopp S, Kellner U. Pars plana vitrectomy. *Klin Monbl Augenheilkd* 2019;236(5):705-722.
- 30 Pollack JS, Sabherwal N. Small gauge vitrectomy: operative techniques. *Curr Opin Ophthalmol* 2019;30(3):159-164.

- 31 Belin PJ, Parke DW 3rd. Complications of vitreoretinal surgery. *Curr Opin Ophthalmol* 2020;31(3):167-173.
- 32 Haritoglou C. Complications after vitreomacular and vitreoretinal surgery. *Ophthalmologie* 2022;119(8):769-770.
- 33 Lang GE, Liakopoulos S, Vögeler J, Weiß C, Spital G, Gamulescu MA, Lohmann C, Wiedemann P. The RELATION study: efficacy and safety of ranibizumab combined with laser photocoagulation treatment versus laser monotherapy in NPDR and PDR patients with diabetic macular oedema. *Acta Ophthalmol* 2018;96(3):e377-e385.
- 34 Chatziralli I, Dimitriou E, Theodosiadis G, Kazantzis D, Theodosiadis P. Intravitreal ranibizumab alone or in combination with panretinal photocoagulation for the treatment of proliferative diabetic retinopathy with coexistent macular edema: long-term outcomes of a prospective study. *Acta Diabetol* 2020;57(10):1219-1225.
- 35 Lang GE, Stahl A, Voegeler J, Quiering C, Lorenz K, Spital G, Liakopoulos S. Efficacy and safety of ranibizumab with or without panretinal laser photocoagulation versus laser photocoagulation alone in proliferative diabetic retinopathy - the PRIDE study. *Acta Ophthalmol* 2020;98(5):e530-e539.
- 36 Huang C, Ji HQ, Han XG. The effectiveness of conbercept combined with panretinal photocoagulation vs. panretinal photocoagulation in the treatment of diabetic retinopathy: a meta-analysis. *J Ophthalmol* 2021;2021:5591719.
- 37 Tao Y, Jiang PF, Zhao Y, Song LH, Ma YT, Li YX, Wang H. Retrospective study of aflibercept in combination therapy for high-risk proliferative diabetic retinopathy and diabetic maculopathy. *Int Ophthalmol* 2021;41(6):2157-2165.
- 38 Sun YY, Qi HJ. A comparison between the therapeutic effects of conbercept combined with panretinal photocoagulation and panretinal photocoagulation monotherapy for high-risk proliferative diabetic retinopathy. *Front Endocrinol* 2022;13:1038757.
- 39 Photocoagulation treatment of proliferative diabetic retinopathy. Clinical application of Diabetic Retinopathy Study (DRS) findings, DRS Report Number 8. The Diabetic Retinopathy Study Research Group. *Ophthalmology* 1981;88(7):583-600.
- 40 Green-Simms AE, Fechtel BM, Agarwal Z, Bakri SJ. Visual and anatomical outcomes of anti-vascular endothelial growth factor therapy in exudative age-related macular degeneration and vitreomacular interface disease. *Retina* 2013;33(7):1359-1364.
- 41 Mayr-Sponer U, Waldstein SM, Kundi M, Ritter M, Golbaz I, Heiling U, Papp A, Simader C, Schmidt-Erfurth U. Influence of the vitreomacular interface on outcomes of ranibizumab therapy in neovascular age-related macular degeneration. *Ophthalmology* 2013;120(12):2620-2629.
- 42 Ciulla TA, Ying GS, Maguire MG, Martin DF, Jaffe GJ, Grunwald JE, Daniel E, Toth CA, Comparison of Age-Related Macular Degeneration Treatments Trials Research Group. Influence of the vitreomacular interface on treatment outcomes in the comparison of age-related macular degeneration treatments trials. *Ophthalmology* 2015;122(6):1203-1211.
- 43 Mesquita J, Castro-de-Sousa JP, Vaz-Pereira S, Neves A, Passarinha LA, Tomaz CT. Vascular endothelial growth factors and placenta growth factor in retinal vasculopathies: Current research and future perspectives. *Cytokine Growth Factor Rev* 2018;39:102-115.
- 44 Nguyen QD, de Falco S, Behar-Cohen F, Lam WC, Li XR, Reichhart N, Ricci F, Pluim J, Li WW. Placental growth factor and its potential role in diabetic retinopathy and other ocular neovascular diseases. *Acta Ophthalmol* 2018;96(1):e1-e9.
- 45 van Bergen T, Etienne I, Cunningham F, Moons L, Schlingemann RO, Feyen JHM, Stitt AW. The role of placental growth factor (PlGF) and its receptor system in retinal vascular diseases. *Prog Retin Eye Res* 2019;69:116-136.
- 46 Hu ZZ, Cao X, Chen L, Su Y, Ji JD, Yuan ST, Fransisca S, Mugisha A, Zou WJ, Xie P, Liu QH. Monitoring intraocular proangiogenic and profibrotic cytokines within 7d after adjunctive anti-vascular endothelial growth factor therapy for proliferative diabetic retinopathy. *Acta Ophthalmol* 2022;100(3):e726-e736.
- 47 Chen XD, Li C, Ding GL, Suo Y, Zhu YS, Lu HQ. Clinical efficacy and changes of serum VEGF-A, VEGF-B, and PlGF after conbercept treating neovascular age-related macular degeneration. *Int J Ophthalmol* 2023;16(9):1489-1495.
- 48 Taniguchi H, Yoshida I, Sakamoto M, Maeno T. Epiretinal membrane appearance or progression after intravitreal injection in age-related macular degeneration. *BMC Ophthalmol* 2021;21(1):190.
- 49 Han FY, Chen XW, Zhao RY, Jin X, Tan W, Zhang Y. The effect of vitreomacular interface in neovascular age-related macular degeneration treated with intravitreal injection of anti-VEGF. *BMC Ophthalmol* 2022;22(1):419.
- 50 Hama Y, Miyata M, Ooto S, Tamura H, Ueda-Arakawa N, Muraoka Y, Miyake M, Takahashi A, Wakazono T, Uji A, Yamashiro K, Tsujikawa A. Seven-year outcome after 1-year fixed regimen of intravitreal aflibercept injections followed by pro re nata treatment for neovascular age-related macular degeneration. *Graefes Arch Clin Exp Ophthalmol* 2023;261(7):1871-1881.