

Malignant glaucoma treated by low-dose laser cycloplasty: a 1-year multicenter prospective non-comparative study

Hai-Shuang Lin¹, Xiao-Ping Xu², Xuan-Li Zheng¹, Ji-Bing Wang³, Su-Jie Fan⁴, Zuo-Hong Wu⁵, Su-Mian Cheng⁶, Li-Jun Zhao⁷, Qin-Hua Cai⁸, Shao-Dan Zhang^{9,10}, Shan-Shan Liu³, Ai-Guo Lyu⁴, Ying Zhang⁵, Hong Chen⁶, Dan-Ni Jiang⁷, Wu-Liang Li², Nathan Congdon^{11,12}, Clement C Tham¹³, Ming-Guang He¹⁴, Yuan-Bo Liang^{9,10}, the Malignant Glaucoma Treatment Trial Study (MGTT) Group

¹Wenzhou Medical University, Wenzhou 325027, Zhejiang Province, China

²Ningbo Eye Hospital, Ningbo 315100, Zhejiang Province, China

³Weifang Eye Hospital, Weifang 261000, Shandong Province, China

⁴Handan Eye Hospital, Handan 056000, Hebei Province, China

⁵Aier Eye Hospital (Wuhan), Wuhan 430061, Hubei Province, China

⁶Hebei Eye Hospital, Xingtai 054001, Hebei Province, China

⁷The Third People's Hospital of Dalian, Dalian 116033, Liaoning Province, China

⁸First Affiliated Hospital of Suzhou University, Suzhou 215031, Jiangsu Province, China

⁹National Clinical Research Center for Ocular Diseases, Eye Hospital, Wenzhou Medical University, Wenzhou 325027, Zhejiang Province, China

¹⁰Glaucoma Research Institute, Wenzhou Medical University, Wenzhou 325027, Zhejiang Province, China

¹¹Centre for Public Health, Queen's University Belfast, Belfast BT7 1NN, UK

¹²Orbis International, New York, USA

¹³Department of Ophthalmology and Visual Sciences, the Chinese University of Hong Kong, Hong Kong SAR 999077, China

¹⁴Centre for Eye Research Australia, University of Melbourne, Royal Victorian Eye and Ear Hospital, East Melbourne 3000, VIC, Australia

Co-first authors: Hai-Shuang Lin and Xiao-Ping Xu

Correspondence to: Yuan-Bo Liang. National Clinical Research Center for Ocular Diseases, Eye Hospital, Wenzhou Medical University, Wenzhou 325027, Zhejiang Province, China. yuanboliang@wmu.edu.cn

Received: 2023-10-30 Accepted: 2024-01-09

Abstract

• **AIM:** To report a one-year clinical outcomes of low-dose laser cycloplasty (LCP) among malignant glaucoma patients.

• **METHODS:** In this prospective, multicenter, non-comparative clinical study, participants with malignant glaucoma were recruited and underwent LCP at eight ophthalmic centers in China. Patients were followed up at 1wk, 1, 3, 6, and 12mo. Intraocular pressure (IOP), number of glaucoma medications, anterior chamber depth (ACD), and complications were recorded. Anatomical success was defined as the reformation of the anterior chamber based on slit-lamp biomicroscopy. Recurrence was defined by the presence of a shallow or flat anterior chamber after initial recovery from treatment.

• **RESULTS:** A total of 34 eyes received LCP. Mean IOP and medications decreased from 36.1±11.5 mm Hg with 3.3±1.5 glaucoma medications pre-treatment to 20.9±9.8 mm Hg ($P<0.001$) with 2.9±1.6 medications ($P=0.046$) at 1d, and 17.4±6.7 mm Hg ($P<0.001$) with 1.3±1.7 medications ($P<0.001$) at 12mo. The ACD increased from 1.1±0.8 mm at baseline to 1.7±1.0 mm and to 2.0±0.5 mm at 1d and 12mo, respectively. A total of 32 (94.1%) eyes achieved initial anatomical success. During follow-up, 2 (5.9%) eyes failed and 8 (23.5%) eyes relapsed, yielding a 12-month anatomical success rate of 64.3%. Complications including anterior synechia (8.82%), choroidal/ciliary detachment (5.88%) and hypopyon (2.94%) were observed within 1wk.

• **CONCLUSION:** LCP is simple, safe, and effective in reforming the anterior chamber in malignant glaucoma.

• **KEYWORDS:** anterior chamber reformation; intraocular pressure; low-dose laser cycloplasty; malignant glaucoma; anatomical success

DOI:10.18240/ijo.2024.07.08

Citation: Lin HS, Xu XP, Zheng XL, Wang JB, Fan SJ, Wu ZH, Cheng SM, Zhao LJ, Cai QH, Zhang SD, Liu SS, Lyu AG, Zhang Y, Chen H, Jiang DN, Li WL, Congdon N, Tham CC, He MG, Liang YB, the Malignant Glaucoma Treatment Trial Study (MGTT) Group. Malignant glaucoma treated by low-dose laser cycloplasty: a 1-year multicenter prospective non-comparative study. *Int J Ophthalmol* 2024;17(7):1248-1254

INTRODUCTION

Malignant glaucoma is a serious complication of intraocular surgery, most commonly among patients with primary angle-closure glaucoma (PACG) who undergo filtering surgery^[1]. The typical clinical features of malignant glaucoma are uniform shallowing or flattening of the central and peripheral anterior chamber, even in the presence of a patent iridotomy, with the absence of suprachoroidal effusion or hemorrhage^[2]. Aqueous misdirection or posterior aqueous diversion from ciliary block is thought to be the pathophysiology^[2]. The incidence of malignant glaucoma after intraocular surgery is 0.06% to 4%^[3-4], and 2.7% in PACG patients undergoing phacotrabeculectomy^[5]. Chinese researchers have reported an incidence of malignant glaucoma of 2%-2.6% after glaucoma surgery^[6].

China bears great burden of visual impairment related with PACG^[7]. Surgical treatment is an important therapeutic option, and in poorly compliant patients or those with severe disease, it may sometimes be offered as first-line therapy^[8]. In China, long-term use of antiglaucoma drugs for PACG is not recommended, and ophthalmologists often prefer trabeculectomy as first-line treatment^[9]. As a common subtype of glaucoma in Asian populations^[7], PACG occupied 54.8%-60.2% of inpatients undergoing glaucoma surgeries^[10-12]. Malignant glaucoma was a serious postoperative complication in PACG patients that should be concerned about.

Malignant glaucoma may worsen despite conventional therapy, and multiple procedures are often necessary. We hypothesized that a laser-induced shrinkage of the ciliary processes could reduce or eliminate the area of ciliolenticular touch and reestablish a patent communication between the retro-lenticular space and the anterior chamber, deepening the latter. According to this theory, transscleral cyclophotocoagulation (TSCPC) with a small number of laser spots (≤ 15) and little total energy (≤ 60 J) applied to the ciliary body would be sufficient to shrink it and deepen the anterior chamber^[13]. We refer to this procedure, aimed at morphological remodeling of the ciliary body, as "low-dose laser cycloplasty (LCP)". LCP applies a smaller number of spots and much smaller area (60 degree in total) compared to standard TSCPC (18-40 spots, 180-360 degree). This reduced number of spots and area can decrease substantial risks of hypotony or bulbi phthisis. LCP has been

reported as successful in a patient with capsular tension ring-related ciliolenticular blockage^[13]. Moreover, we have also reported in a preliminary study^[14-15] that LCP can significantly deepen the central and peripheral anterior chamber in PACG, rapidly reducing the intraocular pressure (IOP).

In order to prospectively examine the effectiveness and safety of LCP in treating patients with malignant glaucoma, we designed the multi-center Malignant Glaucoma Treatment Trial Study (MGTT)^[16]. In the current manuscript, we report 12-month clinical outcomes of the procedure.

SUBJECTS AND METHODS

Ethical Approval This prospective, multicentered, non-comparative interventional study was approved by the Ethics Committee of the Eye Hospital of Wenzhou Medical University (Approval number: YX2018-015). This study was carried out in accordance with the tenets of the Declaration of Helsinki and was registered at the Chinese Clinical Trial Registry (registration number: ChiCTR1800017960). Written informed consent was obtained from all participants prior to treatment.

Study Design and Participants The design and methods of the MGTT have been described elsewhere^[16]. Malignant glaucoma patients were recruited from eight ophthalmic centers in China, commencing in September 2018. Participants aged >18 y with a clinical diagnosis of malignant glaucoma inadequately controlled on topical cycloplegics for at least one day or with recurrence after topical cycloplegic withdrawal were enrolled. Exclusion criteria included the unwillingness to undergo LCP and contraindications to TSCPC due to ocular or systemic diseases. LCP treatments were performed by the same researchers (Liang YB, Wang JB, Fan SJ, Wu ZH, Xu XP, Cai QH, Zhao LJ and Cheng SM) at each clinical center, using the same protocol.

Examination Procedures Prior to treatment, baseline participant information, such as age, gender, ocular history, and use of oral and topical glaucoma medications was recorded. Follow-up visits were scheduled for 1d, 1wk, 1, 3, 6, and 12mo after treatment. All participants underwent a comprehensive ophthalmic evaluation at baseline and each follow-up visit, which included: visual acuity (VA), using a Snellen VA chart which was converted to logarithm of the minimum angle of resolution (logMAR) for statistical analysis; IOP measured by noncontact tonometer; slit-lamp biomicroscopy and slit-lamp imaging of the anterior segment; and assessment of anterior chamber depth (ACD) by ultrasound biomicroscopy (UBM) with water bath. Post-operative complications, need for retreatment with laser or surgery, and recurrences of malignant glaucoma were all recorded during follow-up visits. A shallow anterior chamber was graded using the Spaeth classification, with Grade I defined as peripheral anterior iris-corneal

endothelial touch, Grade II iris-corneal endothelial touch extending from the angle to the pupillary margin, and Grade III involving a totally flat anterior chamber with lenticular (or vitreous)-corneal endothelial touch^[17].

Anatomical success after treatment was defined by reformation of the anterior chamber to Grade 0 or 1 according to the Spaeth classification on slit-lamp biomicroscopic examination. Clinical success was defined as anatomical success and IOP ≤ 21 mm Hg with or without glaucoma medications. Recurrence was defined by the presence of a shallow or flat anterior chamber after initial recovery from the LCP treatment with or without IOP elevation. Failure was defined by the absence of visible improvement of a shallow or flat anterior chamber.

Procedures for Low-Dose Laser Cycloplasty A transscleral diode 810-nm laser and contact G-probe were used to deliver the treatment at standard settings of 2000ms duration and 1000-2000 mW power. After administration of retrobulbar or sub-tenon anesthesia with a 1:1 mixture of lidocaine and bupivacaine, the ciliary body was identified by transillumination. The G-probe was placed over the anterior aspect of the ciliary body, approximately 2.0 mm posterior to the limbus, on the conjunctival surface. Laser power was initially 1200 mW, and increased at 100 mW intervals if no “pop” was heard, or reduced by 100 mW if pigment dispersion or air bubbles were observed. Full treatment consisted of ≤15 applications from 4 to 6 o’clock or 6 to 8 o’clock (60 degrees in total), which was much smaller than TSCPC (18-40 spots, 180-360 degree).

Statistical Analysis Categorical data, including gender, lens status, initial diagnosis, history of previous intraocular surgery, number of glaucoma medications and post-operative complications are presented as number and proportion. Continuous data, including age, VA, IOP and axial length are presented as means and standard deviations. IOP and number of glaucoma medications at baseline and each follow-up were compared using repeated measured ANOVA. All statistical analyses were performed using SPSS (version 24.0 for Windows, SPSS, Inc., Chicago, IL, USA). A *P*-value <0.05 was considered statistically significant.

RESULTS

Among 32 patients enrolled at eight ophthalmic centers [mean age 58.1±15.2y (range 22-87y), 84.4% women], 34 eyes with malignant glaucoma underwent LCP treatment. At baseline, the mean medicated IOP was 36.1±11.5 mm Hg (range, 16.1-60.0 mm Hg). The majority of eyes (*n*=32, 94.1%) had an underlying diagnosis of PACG, and 26 (76.5%) had primary chronic angle-closure glaucoma (CACG), while 25 eyes (73.5%) had a history of filtration surgery. Malignant glaucoma developed in seven eyes (20.6%) after phacoemulsification and

Table 1 Baseline demographics and clinical features of eyes with malignant glaucoma at initial presentation (n=34 eyes of 32 patients)

Characteristics	Value	<i>n</i> (%)
Age (y), mean±SD	58.1±15.2	
Gender: female	27 (84.4)	
Eye: right	14 (41.2)	
Medicated IOP (mm Hg), mean±SD	36.1±11.5	
Glaucoma medications, mean±SD	3.3±1.5	
VA at presentation (logMAR), mean±SD	1.6±1.1	
Axial length (mm), mean±SD	21.3±0.7	
Lens status		
Phakic	17 (50.0)	
Pseudophakic	17 (50.0)	
Initial diagnosis		
Primary acute angle-closure glaucoma	6 (17.6)	
Primary chronic angle-closure glaucoma	26 (76.5)	
Cataract	2 (5.9)	
Previous ocular surgery		
Trab	12 (35.3)	
PCP	3 (8.8)	
Combined phaco and trab/tube	2 (5.9)	
Trab followed by phaco	4 (11.8)	
Phaco followed by trab	4 (11.8)	
Phaco	7 (20.6)	
LPI	2 (5.9)	

IOP: Intraocular pressure; VA: Visual acuity; SD: Standard deviation; Trab: Trabeculectomy; PCP: Penetrating canaloplasty; Phaco: Phacoemulsification; LPI: Nd:YAG laser peripheral iridotomy.

in two eyes (5.9%) after Nd:YAG laser peripheral iridotomy (LPI; Table 1). The time interval between the most recent ocular surgery and occurrence of malignant glaucoma varied between 1d and 20y.

A total of 28 (82.4%) eyes completed the 12-month visit, while 6 (17.6%) were lost to follow-up. Mean IOP decreased from 36.1±11.5 mm Hg with 3.3±1.5 glaucoma medications pre-operatively to 20.9±9.8 mm Hg (*P*<0.001) with 2.9±1.6 medications (*P*=0.046) at 1d, and 17.4±6.7 mm Hg (*P*<0.001) with 1.3±1.7 medications (*P*<0.001) at 12mo (Table 2). Median uncorrected logMAR VA improved from 1.3 (Snellen equivalent 6/120) at baseline to 0.76 (Snellen equivalent 6/34) at 12mo. Vision improved in 15 eyes, remained unchanged in 11 and worsened in 2.

The ACD increased from 1.1±0.8 mm at baseline to 1.9±0.7 mm and to 2.0±0.5 mm at 1wk and 12mo post-treatment, respectively. The trabecular-ciliary process angle (TCA) of 16 eyes from main center increased from 20.3°±7.5° at baseline to 55.9°±10.2° at last follow-up, respectively. The number of eyes with Grade III, Grade II, and Grade I shallow anterior chamber prior to LCP was 5 (14.7%), 10 (29.4%), and

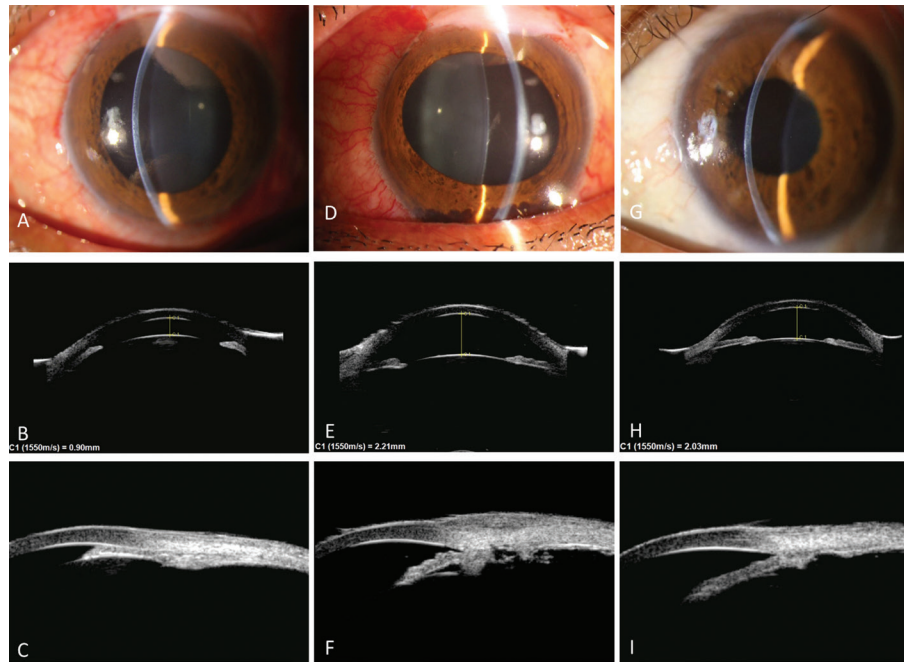


Figure 1 Pre- and post-treatment slit-lamp photograph and UBM images of a 41 years old woman with malignant glaucoma treated by LCP A: Shallow anterior chamber Grade II prior to LCP; B: The central ACD was 0.90 mm when malignant glaucoma occurred; C: Peripheral iridocorneal apposition presenting prior to LCP; D-F: Anterior chamber reformed and central anterior chamber deepened to 2.21 mm 1d after LCP; G-I: The central ACD was 2.03 mm two years after LCP. UBM: Ultrasound biomicroscopy; LCP: Low-dose laser cycloplasty; ACD: Anterior chamber depth.

Parameters	Pre-LCP	Day 1	Week 1	Month 1	Month 3	Month 6	Month 12	P	mean±SD Last follow-up
IOP (mm Hg) ^a	36.1±11.5	20.9±9.8	16.5±6.3	18.1±8.1	16.9±7.7	16.5±5.6	17.4±6.7	<0.001 ^b	16.8±6.7
No. of medications ^a	3.3±1.5	2.9±1.6	2.0±1.6	1.6±1.8	1.5±1.7	1.3±1.6	1.3±1.7	<0.001 ^b	1.3±1.6
Anatomical success			28/34 (82.4)	23/29 (79.3)	19/28 (67.9)	17/27 (63.0)	18/28 (64.3)		24/34 (70.6)
Clinical success			24/34 (70.6)	19/29 (65.5)	18/28 (64.3)	15/27 (55.6)	16/28 (57.4)		22/34 (64.7)

LCP: Low-dose laser cycloplasty; IOP: Intraocular pressure; SD: Standard deviation. ^aAfter patients who underwent malignant glaucoma-related secondary surgical intervention were excluded. ^bRepeated measured ANOVA.

Table 3 Complications in the 34 eyes from malignant glaucoma patients undergoing LCP

Complications	Occurance time and treatment	n (%)
Anterior synechia or pupillary block	1 and 3d, goniosynechialysis (2 eyes); 3d, LPI (1 eye)	3 (8.82)
Choroidal detachment and/or ciliary detachment	1wk, observation (2 eyes)	2 (5.88)
Hypopyon	1wk, systemic and topical anti-inflammatory treatment (1 eye)	1 (2.94)

LCP: Low-dose laser cycloplasty; LPI: Nd:YAG laser peripheral iridotomy.

19 (55.9%), respectively. Thirty-two eyes (94.1%) achieved an initial anatomical success after LCP. Among them, 20 (58.8%) eyes achieved anatomical success at 1d (Figure 1), 10 (29.4%) eyes between 2 and 7d, and 2 (5.9%) eyes between 1wk and 1mo. During follow-up, 2 eyes (5.9%, 2/34) failed within 1wk and 8 (23.5%, 8/34) eyes relapsed within 6mo, yielding a one-year anatomical success of 64.3% (18/28), and clinical success of 57.4% (16/28; Table 2). Retreatments included combined cataract and anterior vitrectomy with hyaloidotomy and iridectomy ($n=3$, 10.7%), anterior vitrectomy with hyaloidotomy and iridectomy ($n=5$ eyes, 17.9%) and repeat LCP (2 eyes, 7.1%).

Regarding complications, three (8.8%) eyes demonstrated anterior synechia or pupillary block, two of which underwent goniosynechialysis, and one was treated with LPI. Choroidal detachment and/or ciliary detachment was found in two eyes (5.9%), which spontaneously resolved within the first month. Hypopyon was observed in one eye (2.9%), which was treated successfully with systemic and topical anti-inflammatory medications (Table 3). Serious complications, including scleral burn, gross hyphema, sympathetic ophthalmia, hypotony, macular edema or phthisis were not observed.

DISCUSSION

Malignant glaucoma is a difficult clinical challenge for

ophthalmologists. In this study, we reported results suggesting that LCP may reverse aqueous misdirection by providing a communication between the vitreous cavity and anterior chamber. Thirty-two eyes (94.1%) achieved an initial anatomical success after LCP. Despite the possibility of recurrence, LCP offers a new treatment option for malignant glaucoma that is inadequately controlled on medical therapy or relapses after withdrawal of cycloplegia.

The baseline clinical features of the patients in this study were typical of malignant glaucoma. The most common diagnosis before developing malignant glaucoma was PACG (32 eyes, 94.1%), similar to previous study^[1]. Moreover, 60%-80% of eyes had CACG^[18-19]. Two eyes with age-related cataract (5.9%) developed malignant glaucoma after phacoemulsification in this study. The axial length of these two eyes were very short at 20.47 and 21.05 mm. Zhou *et al*^[20] analyzed 50 Chinese patients (57 eyes) with malignant glaucoma and found that 3 (5.3%) eyes had an initial diagnosis of age-related cataract. Similar to previous study^[20], the average axial length in this study was very short at 21.3±0.7 mm. The large majority (73.5%) of eyes in our cohort had a history of filtration surgery, which is consistent with previous reports^[21-22]. Malignant glaucoma has also been reported in patients after LPI^[23] or with spontaneous onset^[24]. In the current study, malignant glaucoma developed in 5.9% eyes after LPI. However, the time interval between the last ocular surgery and onset of malignant glaucoma ranged from 1d to 20y, indicating that the last surgery was not necessarily a directly predisposing factor.

The pathophysiology of malignant glaucoma is thought to involve aqueous misdirection or posterior aqueous diversion from the ciliary block^[2,17]. The aims of malignant glaucoma management are clear: to relieve the ciliary block, restore the normal aqueous flow, and re-establish the anterior chamber. LCP, as well as TSCPC, are hypothesized to cause shrinkage of the ciliary processes, reducing the area of ciliolenticular touch, and reestablishing a communication between the anterior chamber and the retro-lenticular space^[25]. As the pressure across the lens becomes balanced, it naturally tends to move backward^[26]. In 1980, it was reported that transpupillary argon laser photocoagulation of the ciliary processes was successful in treating aphakic patients (5/6, 83.3%) with malignant glaucoma^[27]. Retrospective cases of successful use of TSCPC in malignant glaucoma were reported subsequently^[25]. In a retrospective case series, Dave *et al*^[1] noted that four of 6 (66.7%) eyes with malignant glaucoma undergoing initial TSCPC achieved resolution. In the current study, thirty-two eyes with malignant glaucoma (94.1%) achieved an initial anatomical success after LCP. The anatomical success rate of malignant glaucoma treated by LCP was 82.4% at 1wk and

64.3% 12mo. This rate is higher than that reported in previous studies using laser capsulohyaloidotomy^[1,21].

The most common and difficult problem in the management of malignant glaucoma treatment is recurrence^[22,28]. Debrouwere *et al*^[21] reported 100% recurrence with medical treatment and 75% recurrence with laser hyaloidotomy. Dave *et al*^[1] reported a recurrence rate of 30% after laser hyaloidotomy. Recurrence of malignant glaucoma was noted in 40%-66% after successful anterior vitrectomy in combination with an iridectomy-zonulectomy on long-term follow-up^[21,29-30]. However, some studies have reported no recurrences in phakic malignant glaucoma after phacoemulsification combined with posterior capsulorhexis and anterior vitrectomy^[18,31]. Eyes with malignant glaucoma treated with par plana vitrectomy (PPV) combined with iridectomy/hyaloidectomy/zonulectomy (and phacoemulsification if the patient was phakic) have lower recurrence rates (0-11%) compared to those treated with anterior vitrectomy combined with iridectomy/hyaloidectomy/zonulectomy (and phacoemulsification if the patient was phakic)^[21,32]. In our study, recurrence of malignant glaucoma was observed in 8 (28.6%, 8/28) eyes after LCP over 12mo follow-up. These recurrences were ultimately resolved following a second LCP, or anterior vitrectomy combined with hyaloidotomy and iridectomy with/without phacoemulsification.

Long-term iris-corneal endothelial touch and high IOP in malignant glaucoma can result in progressive corneal endothelial cell loss leading to corneal decompensation^[31]. Thus, malignant glaucoma with shallow anterior chamber Grade III should be treated with urgent surgery. As a non-incisional procedure, LCP can be performed in an office setting rather than an operating room, greatly easing access to urgent care. In our study, 94.1% (32/34) of eyes achieved initial anatomical success. Since LCP can deepen the ACD and reduce the IOP quickly, it can be considered as a first line treatment for malignant glaucoma with shallow anterior chamber Grade III to protect the endothelium urgently. Advantages such as technical ease and low cost also allow LCP to serve as a viable primary treatment in patients with poor health or low income.

Notably, the key feature of LCP is creation of a communication between the retro-lenticular space and the anterior chamber, reforming the anterior chamber. It cannot restore outflow from the anterior chamber to Schlemm's canal or a subconjunctival bleb in the setting of extensive peripheral anterior synechia or scarred conjunctiva. Thus, glaucoma medications or filtering bleb management may still be necessary to control IOP after anatomic success in reforming the anterior chamber with LCP. Since malignant glaucoma often has history of prior filtration surgery (73.5% of eyes in our series, 25/34), it is important to pay attention to filtering bleb management.

As a management option for malignant glaucoma, LCP decreases the IOP by reshaping the anterior chamber and partially reopening the closed angle, rather than by decreasing aqueous production^[26]. This should significantly reduce the incidence of post-operative hypotony and phthisis, which are encountered unpredictably after TSCPC^[33]. In the current study, neither hypotony nor phthisis was observed during 12mo follow-up after LCP. Anterior synechia or pupillary block (8.8%, 3/34) resulting from iris-corneal endothelial touch was the most common complication, which responded to goniosynechialysis or LPI. LCP appears to have a different mix of complications in comparison to vitrectomy combined with iridectomy/hyaloidectomy/zonulectomy. Complications that have been reported after vitrectomy combined with iridectomy/hyaloidectomy/zonulectomy^[32] such as retinal detachment, vitreous hemorrhage, endophthalmitis and hyphema, were not observed in our study.

Limitations of the MGTT should be mentioned. First, it had a relatively small sample size of 34 eyes and a relatively short follow-up duration of 12mo. However, this was sufficient to demonstrate the early to medium-term effectiveness and safety of LCP. Second, IOP measurements in this study were performed using a contact tonometer due to its ease of use and comfort for patients. The use of a contact tonometer may be a limitation. However, several studies have shown that using contact tonometer values would not significantly alter the results^[34-35]. To reduce measurement bias, three repeated IOP measurements were taken. Third, this non-comparative study did not have either a control group or an alternative comparison treatment. Further clinical trials are required to compare the safety and effectiveness of LCP and vitrectomy combined with iridectomy and zonulectomy.

In conclusion, LCP is a safe and effective treatment for malignant glaucoma, with promising results in terms of anterior chamber reformation. As a simple, non-invasive laser therapeutic option, LCP can be considered as an early treatment for patients with malignant glaucoma. The management of aqueous humor outflow should be emphasized for IOP control after treatment with LCP.

ACKNOWLEDGEMENTS

The authors wish to thank Jing-Wei Zheng for statistical consultation.

Authors' contributions: Lin HS was involved in investigation, data collection, data curation, formal analysis and the original draft writing. Xu XP was involved in project administration, validation and original draft writing. Zheng XL was involved in investigation, data collection, data curation and formal analysis. Wang JB, Fan SJ, Wu ZH, Xu XP, Cheng SM, Zhao LJ and Cai QH were involved in conceptualization, methodology, investigation and resources. Zhang SD was

involved in methodology, review and the draft revising. Liu SS, Lyu AG, Zhang Y, Chen H, Jiang DN, and Li WL were involved in investigation, and data collection. Congdon N, Tham CC and He MG were involved in review and editing. Liang YB was involved in supervision, conceptualization, methodology, funding acquisition, and the draft revising.

Foundations: Supported by the Program for Zhejiang Leading Talent of S&T Innovation (No.2021R52012); Development Projects of Zhejiang Province (No.2022C03112); Innovation Team Program of Wenzhou.

Conflicts of Interest: Lin HS, None; Xu XP, None; Zheng XL, None; Wang JB, None; Fan SJ, None; Wu ZH, None; Cheng SM, None; Zhao LJ, None; Cai QH, None; Zhang SD, None; Liu SS, None; Lyu AG, None; Zhang Y, None; Chen H, None; Jiang DN, None; Li WL, None; Congdon N, None; Tham CC, None; He MG, None; Liang YB, None.

REFERENCES

- 1 Dave P, Senthil S, Rao HL, Garudadri CS. Treatment outcomes in malignant glaucoma. *Ophthalmology* 2013;120(5):984-990.
- 2 Sharma A, Sii F, Shah P, Kirkby GR. Vitrectomy-phacoemulsification-vitrectomy for the management of aqueous misdirection syndromes in phakic eyes. *Ophthalmology* 2006;113(11):1968-1973.
- 3 Chandler PA. Malignant glaucoma. *Trans Am Ophthalmol Soc* 1950;48:128-143.
- 4 Little BC, Hitchings RA. Pseudophakic malignant glaucoma: Nd:YAG capsulotomy as a primary treatment. *Eye (Lond)* 1993;7(Pt 1): 102-104.
- 5 Senthil S, Rao HL, Choudhari N, Garudadri C. Phacoemulsification versus phacotrabeculectomy in medically controlled primary angle closure glaucoma with cataract in an Indian cohort: a randomized controlled trial. *Int Ophthalmol* 2022;42(1):35-45.
- 6 Wang M, Tan Q, Jiang H, Xia X, Wang P, Jiang J, Liu D. Clinical analysis of malignant glaucoma after glaucoma surgery. *Zhong Nan Da Xue Xue Bao Yi Xue Ban* 2015;40(5):543-548.
- 7 Li C, Zhu B, Zhang J, Guan P, Zhang GS, Yu HH, Yang XH, Liu L. Epidemiology, health policy and public health implications of visual impairment and age-related eye diseases in mainland China. *Front Public Health* 2022;10:966006.
- 8 Lim R. The surgical management of glaucoma: a review. *Clin Exp Ophthalmol* 2022;50(2):213-231.
- 9 Liang YB, Wang NL, Rong SS, Thomas R. Initial treatment for primary angle-closure glaucoma in China. *J Glaucoma* 2015;24(6):469-473.
- 10 Yang J, Qu Y, Li BA, Zhong ZL, Shi LK, Tian XF, Wang R, Xu D, Liu YF. Epidemiological characteristics of inpatients undergoing surgery for glaucoma at Tianjin eye hospital from 2013 to 2017. *J Ophthalmol* 2021;2021:3628481.
- 11 Hu C, Xu J, Liang YB, Ye C, Wu HX, Feng KM, Xie YQ, Fang AW, Qu J. Changing patterns of surgical treatment for glaucoma in the Eye Hospital of Wenzhou Medical University during the past ten years. *Zhonghua Yan Ke Za Zhi* 2018;54(3):184-188.

- 12 Cao Y, Lin HS, Mao HY, Zhao Y, Xie YQ, Zhang SD, Zhang Q, Wang PJ, Li GX, Fang AW, Liang YB. Trend of glaucoma internal filtration surgeries in a tertiary hospital in China. *Int J Ophthalmol* 2023;16(2):251-259.
- 13 Lin HS, Zhou GM, Zhang SD, Huang F, Liang YB. One-year outcome of low dose laser cyclophotocoagulation for capsular tension ring-induced malignant glaucoma: a case report. *Medicine (Baltimore)* 2020;99(6):e18836.
- 14 Lin H, Ye C, Huang Q, Wang X, Zhou W, Zhang S, Xie Y, Xu S, Le R, Liang Y. Preliminary reports of low dose trans-scleral cycloplasty in acute angle closure glaucoma. *Ophthalmology in China* 2021;30(1):30-35.
- 15 Zheng XL, Lin HS, Wang XJ, Li JQ, Xie YQ, Zhang SD, Liang YB. Effect of low dose laser cycloplasty on deepening anterior chamber in chronic angle-closure glaucoma. *Int J Ophthalmol* 2023;16(12):2011-2017.
- 16 Lin HS, Wang JB, Fan SJ, Wu ZH, Xu XP, Cai QH, Zhao LJ, Cheng SM, Zhang SD, Liang YB, Malignant Glaucoma Treatment Trial Study Group. Design and methodology of a multi-centre clinical trial of low dose laser cycloplasty for the treatment of malignant glaucoma in China. *Ophthalmic Epidemiol* 2022;29(5):523-530.
- 17 Schacknow PN, Samples JR. *The glaucoma book: a practical, evidence-based approach to patient care*. Springer: New York 2010;1-1043.
- 18 Liu X, Li M, Cheng B, Mao Z, Zhong YM, Wang DD, Cao D, Yu FF, Congdon NG. Phacoemulsification combined with posterior capsulorhexis and anterior vitrectomy in the management of malignant glaucoma in phakic eyes. *Acta Ophthalmol* 2013;91(7):660-665.
- 19 Lin HS, Li JQ, Zheng XL, Wan R, Zhou MT, Ding YT, Ji YT, Xie YQ, Tham CC, Zhang SD, Liang YB. Incidence and characteristics of aqueous misdirection after glaucoma surgery in Chinese patients with primary angle-closure glaucoma. *Eye Vis (Lond)* 2023;10(1):28.
- 20 Zhou C, Qian S, Yao J, Tang Y, Qian J, Lu Y, Xu G, Sun X. Clinical analysis of 50 Chinese patients with aqueous misdirection syndrome: a retrospective hospital-based study. *J Int Med Res* 2012;40(4):1568-1579.
- 21 Debrouwere V, Stalmans P, van Calster J, Spileers W, Zeyen T, Stalmans I. Outcomes of different management options for malignant glaucoma: a retrospective study. *Graefes Arch Clin Exp Ophthalmol* 2012;250(1):131-141.
- 22 AlQahtani RD, Al Owaifeer AM, AlShahwan S, AlZaben K, AlMansour R. Outcomes of medical and surgical management in aqueous misdirection syndrome. *Clin Ophthalmol* 2023;17:797-806.
- 23 Greenfield JA, Smiddy WE, Greenfield DS. Malignant glaucoma after laser peripheral iridotomy. *J Glaucoma* 2019;28(3):e44-e45.
- 24 Thomas M, Boese EA, Lieu P, Shah M. Slit-lamp pars Plana needle hyaloidotomy-zonulotomy-iridotomy for the treatment of spontaneous malignant glaucoma. *J Glaucoma* 2020;29(5):e31-e32.
- 25 Stumpf TH, Austin M, Bloom PA, McNaught A, Morgan JE. Transscleral cyclodiode laser photocoagulation in the treatment of aqueous misdirection syndrome. *Ophthalmology* 2008;115(11):2058-2061.
- 26 Liang Y, Lin H, Zhang S, Liu C, Xu S, Le R, Xie Y, Li G. Trans-lens pressure difference and ciliary block-A new concept for the mechanism of angle closure glaucoma. *Ophthalmology in China* 2021;30(02):89-96.
- 27 Herschler J. Laser shrinkage of the ciliary processes A treatment for malignant (ciliary block) glaucoma. *Ophthalmology* 1980;87(11):1155-1159.
- 28 Sadeghi R, Momeni A, Fakhraie G, Eslami Y, Zarei R, Vahedian Z, Safizadeh M, Tabatabaei SM. Management of malignant glaucoma. *J Curr Ophthalmol* 2022;34(4):389-397.
- 29 Raj S, Thattaruthody F, Joshi G, Seth NG, Kaushik S, Pandav SS. Treatment outcomes and efficacy of pars Plana vitrectomy-hyaloidotomy-zonulectomy-iridotomy in malignant glaucoma. *Eur J Ophthalmol* 2021;31(1):234-239.
- 30 Schmidt DC, Kessel L, Pedersen KB, Villumsen JE, Bach-Holm D. Pars Plana vitrectomy combined with hyaloido-zonula-iridectomy in treatment of patients with chronic aqueous misdirection: a systematic literature review and case series. *Acta Ophthalmol* 2021;99(3):251-259.
- 31 Wang QW, Zuo CG, Li J, Lin XS, Chen W, Zhu QL, Zhou FQ, Lin HT, Chen WR. Effectiveness of surgical management of malignant glaucoma in phakic eyes. *Int J Ophthalmol* 2022;15(1):65-70.
- 32 Al Bin Ali GY, Al-Mahmood AM, Khandekar R, Abboud EB, Edward DP, Kozak I. Outcomes of pars plana vitrectomy in the management of refractory aqueous misdirection syndrome. *Retina* 2017;37(10):1916-1922.
- 33 Zemba M, Dumitrescu OM, Vaida F, Dimirache EA, Pistolea I, Stamate AC, Burcea M, Branisteanu DC, Balta F, Barac IR. Micropulse vs. continuous wave transscleral cyclophotocoagulation in neovascular glaucoma. *Exp Ther Med* 2022;23(4):278.
- 34 Cook JA, Botello AP, Elders A, Fathi Ali A, Azuara-Blanco A, Fraser C, McCormack K, Margaret Burr J, Surveillance of Ocular Hypertension Study Group. Systematic review of the agreement of tonometers with Goldmann applanation tonometry. *Ophthalmology* 2012;119(8):1552-1557.
- 35 Kato Y, Nakakura S, Matsuo N, Yoshitomi K, Handa M, Tabuchi H, Kiuchi Y. Agreement among Goldmann applanation tonometer, iCare, and Icare PRO rebound tonometers; non-contact tonometer; and Tonopen XL in healthy elderly subjects. *Int Ophthalmol* 2018;38(2):687-696.