

Z-shaped incision without epithelial resection in pterygium surgery

Satoru Kase, Shinki Chin, Susumu Ishida

Department of Ophthalmology, Faculty of Medicine and Graduate School of Medicine, Hokkaido University, Sapporo 060-8638, Japan

Correspondence to: Satoru Kase. Department of Ophthalmology, Faculty of Medicine and Graduate School of Medicine, Hokkaido University, Nishi 7, Kita 15, Kita-ku, Sapporo 060-8638, Japan. kaseron@med.hokudai.ac.jp

Received: 2023-11-21 Accepted: 2024-03-27

Abstract

• **AIM:** To introduce a novel surgical technique using a Z-shaped incision without epithelial resection in ophthalmic pterygia.

• **METHODS:** This was a prospective study. During pterygium surgery, all proliferative tissues were separated from the cornea and conjunctiva without resection of the tissues. The unaffected conjunctiva was incised in a Z-shape. The upper (or lower) conjunctival flap was sutured to the lower (or upper) normal conjunctiva on the limbal sclera, while the proliferative tissue was sutured to the upper conjunctiva (or lower) near the fornix.

• **RESULTS:** Ten patients with pterygia were eligible for this study. Eight patients with primary pterygia and 2 with recurrent pterygia were included. The age of patients at surgery ranged from 47 to 90y (average: 71.9y). Five patients each showed right and left-sided pterygia. The postoperative follow-up periods were from 8 to 78mo (average: 25.0mo). The surgery was successfully conducted and wounds were favorably reconstructed in all patients. The proliferative tissues sutured to the normal conjunctiva showed palor and attenuated neovessles, and never showed re-growth after surgery. Nine patients did not show recurrence. Recurrent pterygium was noted in 1 patient, but additional treatments were not required.

• **CONCLUSION:** The procedure involves the reconstruction of pterygial tissue and normal conjunctiva using a Z-shaped incision. The scleral limbal wound can be covered with non-affected conjunctiva without any excision of conjunctival epithelia in patients with primary or recurrent pterygia.

• **KEYWORDS:** pterygium surgery; Z-shape; non-resection

DOI:10.18240/ijo.2024.07.10

Citation: Kase S, Chin S, Ishida S. Z-shaped incision without epithelial resection in pterygium surgery. *Int J Ophthalmol* 2024;17(7):1262-1266

INTRODUCTION

A pterygium is proliferative fibrovascular tissue growth which is attached firmly by its head to the cornea. It is one of the common ocular surface disorders, and it is highly prevalent in a variety of areas worldwide. Although surgical resection of proliferative tissues has been considered essential, resection of pterygial tissues including the epithelia leads to postoperative inflammation and (epi)scleral circulation disorder, which causes recurrence and scleral melting^[1], unless extensive conjunctival reconstructions are conducted, or topical mitomycin C (MMC) is appropriately used during surgery^[2]. Limbal-conjunctival autograft transplantation (LCAT) or the pedunculated conjunctival flap technique is a standard treatment to allow for rapid epithelial wound healing and prevent pterygium recurrence^[3]. However, these procedures require wide conjunctival incision, which may cause further damage and excess traction of the adjacent normal conjunctiva. Moreover, ophthalmologists should consider sparing normal conjunctiva as much as possible, because of potential ophthalmic surgeries for recurrent pterygia or glaucoma in their lives. It was previously demonstrated that conjunctival pedunculated reconstruction with Z formation for pterygia following pterygium head resections was effective^[4], in which pterygial body tissues could be replaced by normal conjunctiva while avoiding excess traction of the conjunctival flap. However, no additional clinical studies regarding the Z formation method have subsequently been conducted according to the literature.

Histopathological sections of pterygial tissues, surgically removed, have contributed to the progression of clinicopathological research on human pterygium pathogenesis^[5-7]. We have shown that pterygial tissues include columnar epithelial cells with squamous metaplasia, and that epithelial cells located in the head and body show marginally high proliferation activity compared with those in normal conjunctiva, where no cellular atypia was noted^[7]. Ohara *et al*^[8] demonstrated that proliferation activity was significantly lower in pterygial

tissues than conjunctival malignancies in Japanese populations. These histological findings enable us to avoid unnecessary dissection of conjunctival tissues and utilize pterygial tissues as reconstructive materials. The purpose of this study was to demonstrate a novel surgical technique, termed “Z-shaped incision without epithelial resection”, in pterygium surgery, and describe the clinical outcomes.

SUBJECTS AND METHODS

Ethical Approval The institutional review board of Hokkaido University Hospital approved the study protocol (IRB number: 015-0308). This study adhered to the tenets of the Declaration of Helsinki. All patients understood the surgical procedures and consented to enrollment in this study, and written informed consent was obtained.

This was a prospective observational study. Patients were enrolled with primary or recurrent pterygia who underwent Z-shaped incision without epithelial resection between February 2017 and December 2018. All patients underwent ophthalmic tests such as autorefractor, best-corrected visual acuity, intraocular pressure, slit-lamp examination, and fundus. Corneal topography (CASIA, Tomey Corporation, Japan) was employed before surgery, as well as after surgery in selected patients.

The exclusion criteria were patients treated with pterygium surgery combined with free conjunctival flap reconstruction or amniotic membrane transplantation due to wide proliferative tissues, or treated with other procedures employed due to secondary pterygium followed by resection of corneal dermoid^[9]. Pterygium surgeries together with MMC addition were also excluded from this study. In order to eliminate other stimuli of the ocular surface, patients who underwent intraocular surgeries including cataract surgery together with pterygium surgery, and those within 3mo after pterygium surgery were excluded.

Surgical Procedure Figure 1 shows a schematic illustration of this procedure. Local anesthesia using lidocaine was used in all patients. The pterygium head was gently detached from the cornea (Figure 1A), and then the proliferative tissue was radially incised and separated from the sclera without resection. After the separation, remaining fibrous tissues on the cornea were scraped off with a spatula. The normal upper (or lower) conjunctiva was incised in a Z shape including the proliferative tissue (Figure 1B). The conjunctival flap was sutured to the lower (or upper) unaffected conjunctiva on the limbal sclera (Figure 1C). Finally, the proliferative tissue was sutured to the upper conjunctiva near the fornix with 8-0 virgin silk (Figure 1D). Topical MMC was never used in this method. Dexamethasone sodium phosphate (1.65 mg) was injected beneath the conjunctiva following suture. After surgery, topical antibiotics and 0.1% fluorometholone eye drops were given for 1mo and 3 to 6mo, respectively.

RESULTS

Ten patients with pterygia were eligible for this study. Eight patients with primary pterygia and 2 with recurrent pterygia were included. All the pterygia showed invasion beyond the corneal limbus; however, there was no large pterygium invading beyond the pupil in this series. The age of patients at surgery ranged from 47 to 90y (average: 71.9y). Five patients each showed right and left-sided pterygia. The postoperative follow-up periods were from 8 to 78mo (average: 25.0mo). The surgery was successfully conducted, well-tolerated, and wounds were favorably reconstructed in all patients including those with primary pterygium (Figure 2A, 2B) and recurrent pterygium (Figure 2C, 2D). One patient presented with nasal and temporal pterygium with common pterygial vessel configurations (Figure 2E) in the left eye, which could be favorably treated as well (Figure 2F). Postoperative inflammation was noted until 1wk or 1mo after surgery, which resolved thereafter. The proliferative tissues sutured to the normal conjunctiva showed palor and became atrophic, with decreased thickness, and reduced neovessels, which never showed re-growth after the surgery (Figure 2A; arrows). Nine patients did not show recurrence during the follow-up periods, but recurrent pterygium was noted in 1 patient.

A Representative Case: Recurrent Pterygium A 47-year-old male suffered from blurred vision in the left eye (OS). His visual acuity was 0.7 with strong astigmatism (sphere, +3.25 D; cylinder, -5.25 D Ax 10°) OS. Slit-lamp examination revealed a primary nasal pterygium showing a thickened, proliferating tissue with neovessel formation growing towards the central cornea (Figure 3A). Corneal topography revealed marked irregular astigmatism (Figure 3B). He had a medical history of radiation therapy (60 Gy/30 Fr) due to olfactory neuroblastoma about 2 months ago. No vascular abnormality was observed in the conjunctiva except for the proliferative tissue. He underwent Z-shaped incision in pterygium surgery; however, thin Tenon tissues remained around the corneal limbus afterwards. His visual acuity increased to 1.0 (sphere, +0.75 D; cylinder -3.50 D Ax 90°) 24mo after the surgery. Slit-lamp examination showed a clear limbal wound covered with normal conjunctiva. There still existed thin vascularized tissues in the nasal corneal limbus (Figure 3C), which could be considered recurrent pterygium. Corneal tomography revealed direct astigmatism (Figure 3D). The recurrent pterygium, however, did not require additional surgeries 78mo after the initial surgery, because the recurrent tissue did not impair his vision and he was not willing to receive additional postoperative treatments.

DISCUSSION

It has been considered that the principal of pterygium surgery is the resection of proliferative tissues and reconstruction of the corneal limbus. Various procedures have been proposed

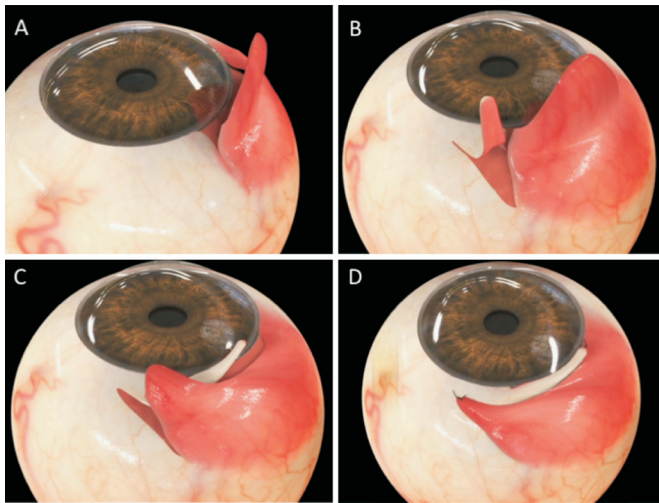


Figure 1 A schematic illustration of the surgical technique in Z-shaped incision without epithelial resection A: The pterygium head was gently detached from the cornea; B: The normal upper conjunctiva was incised in a Z-shape including the proliferative tissue; C: The conjunctival flap was sutured to the lower conjunctiva on the limbal sclera; D: The proliferative tissue was sutured to the upper conjunctiva near the fornix with 8-0 virgin silk.

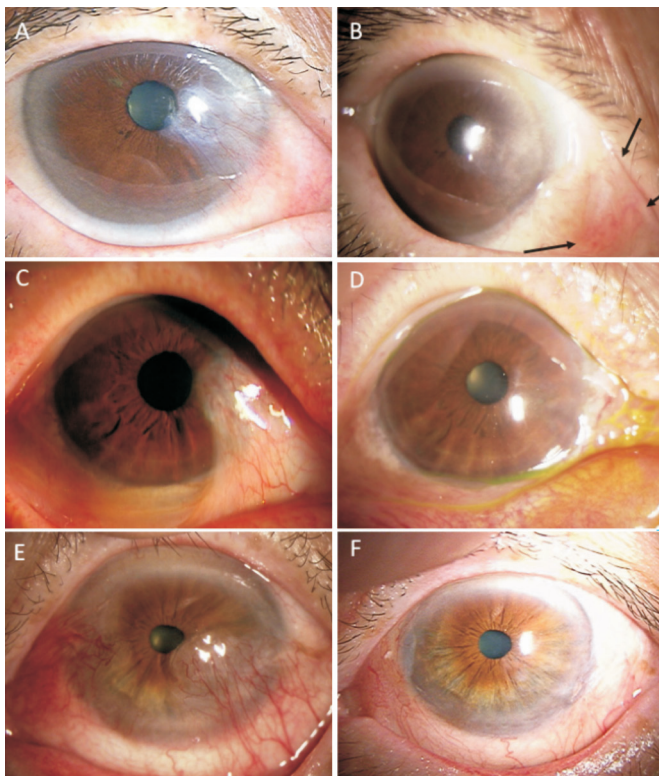


Figure 2 Slit-lamp examination of a primary pterygium (A, B), recurrent pterygium (C, D), and nasal and temporal pterygium (E, F) before (A, C, E) and after (B, D, F) Z-shaped incision without epithelial resection Before surgery, pterygia presented with proliferating tissues with neovessel formation towards the cornea (A, C, E). After the surgery, slit-lamp examination showed a clear limbal wound covered with unaffected conjunctiva (B, D, F). The proliferative tissues sutured to the normal conjunctiva showed paler and became atrophic, with a decreased thickness, and never showed re-growth after surgery (A; arrows).

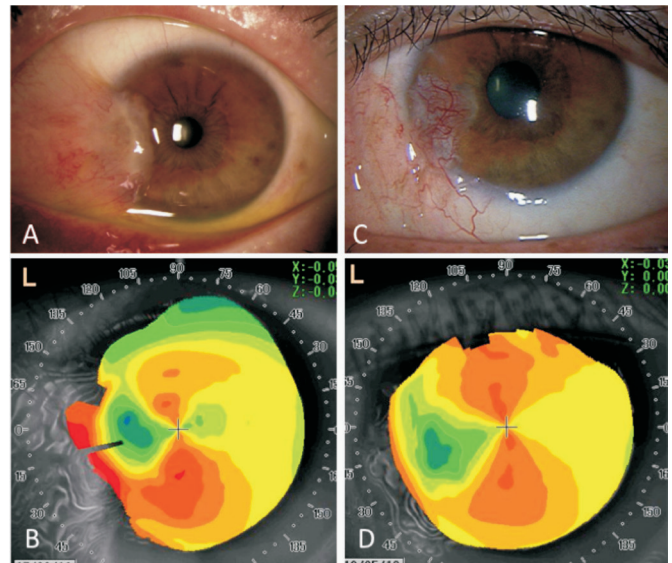


Figure 3 A case of recurrent pterygium undergoing slit-lamp examination (A, C) and corneal topography (B, D) A: Slit-lamp examination revealed a primary nasal pterygium showing proliferating tissue with neovessel formation growing towards the central cornea; B: Corneal topography revealed marked irregular astigmatism; C: There still existed vascularized tissues in the nasal corneal limbus; D: Corneal topography revealed direct astigmatism after surgery.

to address these, including conjunctival flaps, conjunctival or limbal autografts, and amniotic membrane transplantation^[10-13]. In the LCAT procedure, after excision of the pterygium from the cornea, a limbal-conjunctival autograft from the superior bulbar conjunctiva was obtained^[11]. This graft was placed over the bare sclera and sutured. However, in LCAT, the upper conjunctiva is associated with postoperative inflammation and adhesion to Tenon's capsule and the sclera because of the initial excision. These factors subsequently make it difficult to conduct glaucoma filtering surgery when the patient needs to receive such surgery in the future. Also, if management of the upper conjunctiva obtained is in error, the conjunctival free flap might be sutured to the corneal limbus upside down.

Amniotic membrane transplantation is a useful procedure, but it may be difficult to prepare the amniotic membrane and perform the surgery in many private ophthalmology clinics, although the prevalence of pterygia is not rare worldwide. Conjunctival pedunculated flap surgery combined with wide resection of proliferative tissues is straightforward^[14]; however, because the conjunctiva is mechanically pulled to the corneal limbus to fully close the defects, excess tension and traction may occur when the flap is sutured. This mechanical tension may cause not only damage of the conjunctiva but also recurrence and/or symblepharon formation involving the bulbar conjunctiva. Taken together, preoperative preparations without effort and easier procedures with minor stress

to the conjunctiva in pterygium surgery are required for ophthalmologists working in public and private clinics.

The characteristics of the current Z-shaped incision are as follows: the first feature of this procedure is that there is no resection/removal of any ocular surface epithelia in the proliferative tissue or normal conjunctiva. Resection of the pterygial proliferative tissues including epithelia might induce simultaneous hemorrhage and postoperative inflammation, which potentially causes recurrence. This study employed the design of Z-shaped incision including the proliferative tissue, modified from Z-shaped incision by Wilson and Bourne^[4]. The current Z-shaped incision can reduce postoperative inflammation to a minimum. Also, since the unaffected conjunctiva is not excised either, the conjunctiva in the limbus is easily sutured with no excess mechanical tension.

The second feature is the suture of proliferative pterygial tissue to the upper normal conjunctiva near the fornix. Indeed, a single feeder vessel from the anterior conjunctival circulation branches out to form radial vessels in the pterygium^[15]. In this procedure, it is possible to change the direction of a feeder vessel to the upper fornix, not to the corneal center. Moreover, the proliferative tissue is no longer able to attach to the cornea. This alteration contributes to preventing any re-growth of the initial proliferative tissues on the cornea after surgery.

The third is that the sutured pterygium head proliferative tissues near the fornix become pale and show reduced neovessels. Limbal stem cells are vital for normal corneal epithelial regeneration, preventing growth of the conjunctival epithelium onto the cornea through contact inhibition^[16-17]. Moreover, it is possible to suppress pterygium growth based on the principal of contact inhibition after pterygium surgery^[17]. In fact, angiogenic factors such as vascular endothelial growth factor (VEGF) were highly expressed in the pterygial epithelia compared with normal conjunctiva^[18-20]. Pterygial tissues treated with intralesional anti-VEGF injection showed reductions of the vessel count and recurrence rates^[20-21]. Muluk *et al*^[22] demonstrated that contact inhibition reduced VEGF expression and the volume of proliferative tissues like nasal polyps. Therefore, the mechanisms underlying the pallor and attenuation of vessel formation in the proliferative tissue might be due to down-regulation of angiogenic factors and endothelial cell death, caused by contact inhibition through the attachment with the normal conjunctiva.

We sutured the proliferative tissue to upper conjunctiva near the fornix but not to the lower conjunctiva in this study. Generally, the proliferative tissue is likely to come from the inferior-nasal site with/without symblepharon involving the lower palpebral conjunctiva in ophthalmic pterygia. If the proliferative tissue is sutured to the lower conjunctiva, mechanical stress during the suturing of the normal conjunctiva on the corneal limbus

is considered to take place. Therefore, we can choose between incision of the upper or lower bulbar conjunctivae depending on the location of proliferative tissues. As mentioned above, in any case, even if patients who undergo this surgery need glaucoma filtering surgery later, it will be possible because the upper temporal limbus-conjunctiva remains intact with this method, unlike in conventional conjunctival pedunculated flap surgery or LCAT.

The current procedure is characterized by the non-resection of epithelial tissue; this means that the proliferative tissue remains on the ocular surface after surgery. The origin of this “non-resection” concept is derived from histological findings in pterygial tissues, proving the presence of epithelial cells with no cellular atypia in Japanese populations^[5-6,8]. On the other hand, it has been reported that pterygium epithelia may histologically contain atypical squamous cells with malignant potential^[23]. Molecular biological research has demonstrated that pterygium epithelial cells utilize cancer-related molecular pathways, which could be a target for novel therapies to induce apoptosis and inhibit fibrosis^[24-25]. We previously reported a rare case of inflammatory carcinoma *in situ* arising from the primary pterygium^[26]. Therefore, since the possibility of malignant transformation and/or squamous cell carcinoma arising from the pterygial tissue cannot be completely excluded, the safety of this procedure in cases of atypical or temporal pterygia cannot be ensured. It is indisputable that preoperative ocular surface conditions based on slit-lamp examinations must be carefully evaluated in order to exclude comorbidities involving pterygial tissues. In this case series, one patient showed nasal and inferotemporal pterygial tissues with common pterygial vessel configurations, which could be successfully treated with this procedure (Figure 2E, 2F). Long-term follow-up is required after this pterygium surgery despite localization of the preoperative pterygium.

There were limitations of this study. First, although it was set as a prospective observation study, the number of patients eligible was small during the study period. Therefore, as the next step, we plan to conduct a retrospective study with long-term periods of enrollment to expand the sample size, dividing patients into subgroups depending on the size, thickness, and location of the pterygium. Moreover, a prospective study with longer study periods is needed. Second, since this procedure is characterized by the fact that there is no resection of any ocular surface epithelia, it is impossible to analyze pathological sections, especially in sutured proliferative tissues. In fact, since this case series confirmed the lack of re-growth of sutured proliferative tissues during the follow-up, which is likely to be based on the principal of contact inhibition, the authors had no opportunity to obtain pathological materials. Therefore, if sutured tissues show re-growth following this

surgery, histological examinations following surgical removal should be conducted. Finally, the study protocol was not based on head-to-head clinical trials compared with other procedures such as LCAT and/or amniotic membrane techniques; therefore, further studies are needed to resolve those issues and compare postoperative clinical outcomes such as recurrence rates. In conclusion, Z-shaped incision without epithelial resection is safe and well-tolerated by patients with primary or recurrent pterygia.

ACKNOWLEDGEMENTS

Conflicts of Interest: Kase S, None; Chin S, None; Ishida S, None.

REFERENCES

- 1 Alsagoff Z, Tan DT, Chee SP. Necrotising scleritis after bare sclera excision of pterygium. *Br J Ophthalmol* 2000;84(9):1050-1052.
- 2 Aziza Y, Inatomi T, Sotozono C, Kinoshita S. Pterygium excision with modified bare sclera technique combined with mitomycin C. *Jpn J Ophthalmol* 2021;65(1):89-96.
- 3 Chang J, Cao Q, Yong J, Ling X, Zhang X, Kang Z, Xue C. The effect of different pterygium surgery techniques on the ocular surface parameters in different durations: a systematic review and meta-analysis. *Graefes Arch Clin Exp Ophthalmol* 2024;262(5):1383-1396.
- 4 Wilson SE, Bourne WM. Conjunctival Z-plasty in the treatment of pterygium. *Am J Ophthalmol* 1988;106(3):355-357.
- 5 Kase S, Kitaichi N, Furudate N, Yoshida K, Ohno S. Increased expression of mucinous glycoprotein KL-6 in human pterygium. *Br J Ophthalmol* 2006;90(9):1208-1209.
- 6 Kase S, Osaki M, Sato I, Takahashi S, Nakanishi K, Yoshida K, Ito H, Ohno S. Immunolocalisation of E-cadherin and beta-catenin in human pterygium. *Br J Ophthalmol* 2007;91(9):1209-1212.
- 7 Kase S, Takahashi S, Sato I, Nakanishi K, Yoshida K, Ohno S. Expression of p27(KIP1) and cyclin D1, and cell proliferation in human pterygium. *Br J Ophthalmol* 2007;91(7):958-961.
- 8 Ohara M, Sotozono C, Tsuchihashi Y, Kinoshita S. Ki-67 labeling index as a marker of malignancy in ocular surface neoplasms. *Jpn J Ophthalmol* 2004;48(6):524-529.
- 9 Mitamura M, Kase S, Ohguchi T, Ishida S. A case of pterygium-like proliferation containing postoperative limbal dermoid remnants: a clinicopathological study. *BMC Ophthalmol* 2021;21(1):12.
- 10 Gera P, Kasturi N, Behera G, Jayasri P, Jayaseelan J. Preparation and uses of amniotic membrane for ocular surface reconstruction. *Indian J Ophthalmol* 2023;71(8):3119.
- 11 Keshet Y, Polat A, Gal-Or O, Ben Ishai M, Keshet Y, Fradkin M, Schaap Fogler M, Megiddo Barnir E. Limbal-conjunctival autograft healing process-early postoperative OCT angiography study. *Eye (Lond)* 2022;36(11):2151-2156.
- 12 Sanders FWB, Huang JH, Alió Del Barrio JL, Hamada S, McAlinden C. Amniotic membrane transplantation: structural and biological properties, tissue preparation, application and clinical indications. *Eye (Lond)* 2024;38(4):668-679.
- 13 Pedrotti E, Bertolin M, Fasolo A, Bonacci E, Bosello F, Ponzin D, Marchini G. Autologous simple conjunctival epithelial transplantation for primary pterygium. *Int Ophthalmol* 2022;42(12):3673-3680.
- 14 Lee JS, Choi YS, Jo YJ, Lee JE. Pterygium surgery by double-sliding flaps procedure: comparison between primary and recurrent pterygia. *Indian J Ophthalmol* 2021;69(9):2406-2411.
- 15 Chan CM, Chew PT, Alsagoff Z, Wong JS, Tan DT. Vascular patterns in pterygium and conjunctival autografting: a pilot study using indocyanine green anterior segment angiography. *Br J Ophthalmol* 2001;85(3):350-353.
- 16 Tayanc E, Akova Y, Yilmaz G, Aydin P. Anterior segment indocyanine green angiography in pterygium surgery with conjunctival autograft transplantation. *Am J Ophthalmol* 2003;135(1):71-75.
- 17 Hara T, Shoji E, Hara T, Obara Y. Pterygium surgery using the principle of contact inhibition and a limbal transplanted pedicle conjunctival strip. *Ophthalmic Surg* 1994;25(2):95-98.
- 18 Turan M, Turan G, Can HY. The role of cyclophilin A and VEGF in the pathogenesis and recurrence of pterygium. *Eur J Ophthalmol* 2022;11206721221128664.
- 19 Mastronikolis S, Adamopoulou M, Tsiambas E, Makri OE, Pagkalou M, Thomopoulou VK, Georgakopoulos CD. Vascular endothelial growth factor expression patterns in non-human papillomavirus-related pterygia: an experimental study on cell spot arrays digital analysis. *Curr Eye Res* 2022;47(7):1003-1008.
- 20 Mohamed TA, Soliman W, Fathalla AM, El Refaie A. Effect of single subconjunctival injection of bevacizumab on primary pterygium: clinical, histopathological and immunohistochemical study. *Int J Ophthalmol* 2018;11(5):797-801.
- 21 Zhang BW, Dong XM, Sun Y. Efficacy and safety of anti-vascular endothelial growth factor agents in the treatment of primary pterygium. *Front Med* 2023;10:1166957.
- 22 Muluk NB, Atasoy P, Arikan OK, Koc C. Role of vascular endothelial growth factor in the pathogenesis of nasal polyps. *J Otolaryngol* 2007;36(6):357-366.
- 23 Chui J, Coroneo MT, Tat LT, Crouch R, Wakefield D, di Girolamo N. Ophthalmic pterygium: a stem cell disorder with premalignant features. *Am J Pathol* 2011;178(2):817-827.
- 24 Wang YC, Zhao FK, Liu Q, Yu ZY, Wang J, Zhang JS. Bibliometric analysis and mapping knowledge domain of pterygium: 2000-2019. *Int J Ophthalmol* 2021;14(6):903-914.
- 25 Gong Y, Liao YH, Yi QY, Li M, Chen LS, Wang YY. Nintedanib induces apoptosis in human pterygium cells through the FGFR2-ERK signalling pathway. *Int J Ophthalmol* 2023;16(4):505-513.
- 26 Endo H, Kase S, Suzuki Y, Kase M. Coincidence of inflamed conjunctival carcinoma *in situ* and primary pterygium. *Case Rep Ophthalmol* 2016;7(3):208-212.