

Surgical approaches to correct corneal astigmatism at time of cataract surgery: a mini-review

Xiao-Lei Yin¹, Zhi-Yang Ji², Xiu-Xin Li¹, Xue-Mei Liang³, Shu-Xing Ji²

¹Department of Ophthalmology, the 305 Hospital of PLA, Beijing 100017, China

²Department of Ophthalmology, Daping Hospital, Army Medical University, Chongqing 400042, China

³Department of Medical Administration, the 305 Hospital of PLA, Beijing 100017, China

Co-first authors: Xiao-Lei Yin, Zhi-Yang Ji, and Xiu-Xin Li

Correspondence to: Xiao-Lei Yin. Department of Ophthalmology, the 305 Hospital of PLA, Beijing 100017, China. yinxiaolei971221@163.com; Xue-Mei Liang. Department of Medical Administration, the 305 Hospital of PLA, Beijing 100017, China. liangxm07@126.com; Shu-Xing Ji. Department of Ophthalmology, Daping Hospital, Army Medical University, Chongqing 400042, China. jishuxinger@126.com

Received: 2023-10-27 Accepted: 2024-04-01

Abstract

• Among refractive errors, astigmatism is the most common optical aberration, where refraction changes in different meridians of the eye. It causes blurred vision at any distance and includes corneal, lenticular, and retinal astigmatism. Cataract surgery used to cause a progressive increase in the pre-existing corneal astigmatism because of creating a surgically induced astigmatism, for example, a large size surgery incision. The development of surgical techniques during last decades has made cataract surgery interchange to treat preoperative corneal astigmatism at time of surgery. Nowadays, three surgical approaches can be used. By placing a sutureless clear corneal incision on the steep meridian of the cornea, a preoperative corneal astigmatism less than 1.0 D can be corrected. Single or paired peripheral corneal relaxing incisions (PCRIs) provide 1.0-3.0 D corneal astigmatism correction. PCRIs are typically used for treating 1.0-1.5 D of regular corneal astigmatism, if more than 2.0 D, the risk of overcorrection and irregular astigmatism is increased. When toric intraocular lenses (IOLs) are unavailable in markets, PCRIs are still a reasonable option for patients with up to 3.0 D of pre-existing corneal astigmatism. Toric IOLs implantation can correct 1.0-4.5 D of corneal astigmatism. Several IOLs are

approved to correct a high degree of corneal astigmatism with cylinder power up to 12.0 D. These approaches can be used alone or in combination.

• **KEYWORDS:** cornea; astigmatism; cataract surgery; peripheral corneal relaxing incisions; toric intraocular lens

DOI:10.18240/ijo.2024.07.23

Citation: Yin XL, Ji ZY, Li XX, Liang XM, Ji SX. Surgical approaches to correct corneal astigmatism at time of cataract surgery: a mini-review. *Int J Ophthalmol* 2024;17(7):1370-1374

INTRODUCTION

Among refractive errors, astigmatism is the most common optical aberration, where refraction changes in different meridians of the eye. The light rays passing through the eye cannot converge at a particular focal point on the retina but form focal lines and was first reported by Thomas Young in the 18th century^[1]. It causes blurred vision at any distance and includes corneal, lenticular, and retinal astigmatism^[2]. Cataract surgery used to cause a progressive increase in the preexisting corneal astigmatism because of creating a surgically induced astigmatism (SIA), for example, a large size surgery incision. The development of surgical techniques during last decades has made cataract surgery interchange to treat preoperative corneal astigmatism at time of surgery. Nowadays, three surgical approaches can be used. One option is by placing a clear corneal incision (CCI) on the steep meridian of the cornea. The other two surgical approaches, single or paired peripheral corneal relaxing incisions (PCRIs) and toric intraocular lenses (IOLs) implantation can also be used to correct corneal astigmatism. In this review paper, we describe the three surgical methods used to correct corneal astigmatism during cataract surgery and focus on the degrees of corneal astigmatism that can be treated with different methods.

CATARACT SURGERY INCISION

The size of incision is a confirmed factor that causes astigmatism during cataract surgery^[3]. Corneal SIA is proportional to the incision size, and the severity of SIA depends on the length, width, and location of the incision, a larger incision usually causes larger changes in astigmatism^[4].

In the developing world, manual small incision cataract surgery (SICS) is a more popular choice for ophthalmologists because of its low cost^[5]. In conventional SICS, the incision size is 6.0 mm width. SIA associated with SICS with a straight superior scleral incision was observed nearly 2.0 D at 3mo postoperatively by Reddy *et al*^[5]. Interestingly, for SICS with a 6.0 mm superior frown incision, only 0.5 D corneal astigmatism was observed at 90d postoperatively^[6]. In a study by Roman *et al*^[7], cataract surgery with a sutureless 3-step tunnel and 4.0 mm superior corneal incision, SIA was approximately 1.5 D one year postoperatively. Similarly, Barequet *et al*^[8] reported a 1.41 D SIA for a 3.5 mm horizontal nasal CCI 12mo after cataract surgery. But 0.71 D SIA in the same research surgery with 3.5 horizontal temporal incision. However, there was no significant difference in SIA between superior incisions and temporal incisions in conventional SICS with a straight scleral 6.0 mm incision. At 90d after SICS, the superior incisions showed 1.92 D against the temporal incisions 1.57 D of rule astigmatism^[5].

Advances in cataract surgery techniques significantly assist in reducing the size of surgical incisions. Nowadays, typically sutureless CCI is about 3.0 mm wide, which leads to an approximately 0.50 D change in astigmatism, and a 5.0 mm width leads to a 1.0 D change^[9-10]. Another study indicated that a 0.5 mm increase in the incision width is associated with a 0.25 D change in the corneal curvature^[11]. In some cases, as the corneal incision size decreases to 2.0 mm, the SIA can still reach approximately 0.50 D^[12]. However, 1.8 and 2.2 mm incisions make no difference in astigmatism^[3]. Piao and Joo^[4] compared SIA after steep meridian 3.2 mm CCIs in cataract surgery at temporal, superotemporal, superonasal, and superior locations. At 2mo, there was a statistically significant reduction in astigmatism with superior incisions. According to other studies, the superior incisions are associated with more SIA than temporal incisions are^[13-14]. The distance from cornea to limbus is shorter in the horizontal direction than in the vertical direction, and the corneal fibers are much stronger at short distances from the central cornea^[15].

SIA in cataract surgery is not always a side effect, it can be used for reducing and eliminating preexisting corneal astigmatism. Corneal astigmatism of 0.75 D or greater after surgery may reduce uncorrected visual acuity and induce symptomatic blur, ghosting of images, and halos^[16]. Placement of the main incision on the steep meridian of corneal astigmatism is the ideal approach for patients with less than 1.0 D of preoperative corneal astigmatism^[17]. The cornea can be flattened by a full thickness corneal incision in meridian of the incision and thus can reduce preexisting astigmatism. Postoperative astigmatism less than or equal to 0.50 D allows most cataract patients to be spectacle-independent^[18].

PERIPHERAL CORNEAL RELAXING INCISION

Eyes with >1.0 D of corneal astigmatism can be treated by placing additional incisions in the peripheral cornea during cataract surgery^[19]. Single or paired PCRI provide 1.0-3.0 D corneal astigmatism correction^[18]. In some literature, PCRI are called limbal relaxing incisions, which are inaccurate because the limbus is not incised^[20]. These incisions are made in the peripheral clear cornea^[18].

The PCRI are usually made initially of surgery when the epithelium is still well-maintained and the ocular pressure is predictable. Traditionally, the incisions are made at a depth of 90% minimum corneal pachymetry. If the corneal topography and slit lamp examination are normal, the incision depth is, as usual, 450-550 μ m. Amesbury and Miller^[20] suggested that a 450 μ m depth of PCRI was safe and effective through their nomogram of the age related cataract population. They also found that symmetric paired incisions were made in the steep meridian of peripheral cornea, and each 1.8 clock hours in length was used to correct 1.8 D of regular corneal astigmatism. If the astigmatism is irregular, PCRI can be made asymmetrically in different meridians, placing a longer incision on the steeper side of the cornea. The correction of the astigmatism diopter is half of the sum length of the incisions. A number of PCRI nomograms have been published to guide the location and size of peripheral corneal incisions to the intended magnitude of astigmatism correction, such as the Modified Gills nomogram (Table 1)^[21], the Donnenfeld nomogram^[22] and the Nichamin nomogram^[23] (both can be used by an online calculator, www.lricalculator.com, Latest Version 4.2.0; Figure 1). PCRI should be created with a special diamond or metal astigmatic keratotomy blade. In femtosecond laser-assisted cataract surgery, PCRI can be placed by using the femtosecond laser, namely femtosecond laser-assisted arcuate keratotomy (FAK). It is classified into two types, penetrating FAK (pFAK) and intrastromal FAK (iFAK). Most studies have shown good correction with pFAK^[24]. pFAK can be single-arc incision or double-arc and separate incision, at 80% or 85% corneal depth with a 90° side cut angle. The arc diameter for these arcuate keratotomies was kept at 8.0 mm and they were limbal centred^[25-26]. An online calculator (www.lricalculator.com) based on the Donnenfeld nomogram or Nichamin nomogram was used to calculate the angular arc length of the incision, number of incisions, and axis of placement of the incision after considering both SIA and preexisting keratometric astigmatism. Compared to manually performed PCRI, FAK may be more effective, reliable, and reproducible. To avoid the negative effects of intersecting incisions, two caveats should be noted^[18]. If the PCRI coincides with the clear corneal cataract incision, it should not exceed the length of the cataract incision and should only lengthen after IOL

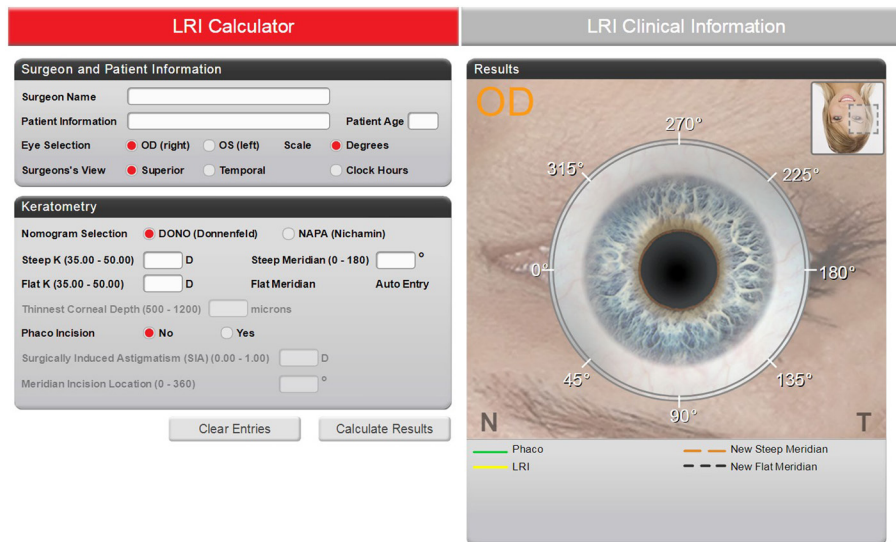


Figure 1 The online calculator to calculate the size of peripheral corneal relaxing incision.

Table 1 Modified Gills nomogram for PCRIs to correct keratometric astigmatism during cataract surgery

Preoperative cylinder (D)	Length (degrees) of arc						
	30-40y	41-50y	51-60y	61-70y	71-80y	81-90y	≥90y
WTR astigmatism							
1.50 to 2.25	60	55	50	45	40	35	30
1.50 to 2.25	70	65	60	55	50	45	40
≥3.25	80	75	70	65	60	55	45
ATR astigmatism							
1.50 to 2.00	70	65	60	55	45	30	30
2.25 to 2.75	90	80	70	60	50	45	40
≥3.00	90	90	85	70	60	50	45

PCRIs: Peripheral corneal relaxing incisions; WTR: With the rule; ATR: Against the rule.

implantation. If the PCRI is close to the paracentesis incision, the paracentesis should be performed peripherally to the PCRI to avoid intersecting the incisions. Usually, a cataract incision is placed inside the PCRI, if the cataract incision is created 90° away from the PCRI axis to avoid a prominent brow or other obstacle, the lengths of the PCRIs should be added to compensate^[20].

PCRIs are typically used for treating 1.0-1.5 D of regular corneal astigmatism, more than 2.0 D, the risk of overcorrection and irregular astigmatism is increased^[27]. When toric IOLs are unavailable in markets, PCRIs are still a reasonable option for patients with up to 3.0 D of pre-existing corneal astigmatism^[27]. This procedure should not be performed on corneas suspected of having ectasia based on abnormal topography, or those with obvious thinning on slit lamp examination.

TORIC INTRAOCULAR LENSES IMPLANTATION

Toric IOLs implantation are often used in patients who have corneal astigmatism greater than 0.75 D^[19,28]. Compared with PCRIs, this is the prime method for treating higher orders of regular corneal astigmatism in patients at the time of cataract surgery^[29].

The first use of toric IOL in cataract surgery was reported by Shimizu *et al*^[30] in Japan in 1994. In the United States, the first toric IOL approved by the FDA in 1998 was the STAAR toric IOL (Staar Surgical, Monrovia, CA)^[18]. Currently, a wide variety of toric IOLs can be found in the market. They can correct 1.0-4.5 D of corneal astigmatism, and several IOLs have been approved to correct a high degree of corneal astigmatism with cylinder power up to 12.0 D (Table 2).

To surgeons, before implanting toric IOLs as an astigmatism correction strategy in cataract surgery, identifying corneal astigmatism is much more important than total astigmatism which includes both lens and corneal astigmatism. Because lens astigmatism is eliminated with the removal of the cataractous lens, only correction of the preoperative corneal astigmatism is needed. Many types of instruments can be used to measure corneal astigmatism and can successfully determine the corneal astigmatism value and steep axis during toric IOL implantation. Some widely used methods are based on keratometry and measure the corneal curvature and astigmatism by analyzing a constant-sized image of mires and include manual keratometry, automated keratometry, the Lenstar LS900 (Haag-Streit AG, Switzerland)^[31], and the IOLMaster (Carl Zeiss Meditec AG, Germany)^[32]. Other approaches, such as the Pentacam (Oculus GmbH, Germany)^[33], the Orbscan II (Bausch & Lomb, USA)^[34], and the iTrace (Tracey Technologies, USA)^[35] are based on corneal topography.

To correctly align the toric IOL, the surgeon should mark 6 o'clock and/or 3 and 9 o'clock positions on the cornea of the patient in the upright seated position looking straight ahead and with both eyes open to avoid cyclotorsion. The reference mark could compensate for ocular torsion when the patient lies flat. In addition to manual marking, there are also some image guided systems can be used, such as the Callisto eye image-guided markerless system (Carl Zeiss Meditec AG, Germany),

Table 2 Toric IOLs are currently available

Toric IOL	Manufacturer	Material	Overall diameter	Spherical power, D	Cylinder power (correct astigmatism), D	Addition power, D
Monofocal lenses						
AcrySof Toric IOL	Alcon Labs	Hydrophobic acrylic lens	13 mm	6.0-30	1.5-6.0 (0.75-4.11)	
Hoya Vivinex Toric IOL	Hoya Surgical Optics	Hydrophobic acrylic lens	12.5 mm	10-30	1.0-6.0	
AT Torbi IOL	Zeiss	Hydrophilic acrylic lens with hydrophobic surface	11 mm	-10 to 32	1.0-12	
EnVista Toric IOL	Bausch+Lomb	Hydrophobic acrylic lens	12.5 mm	6.0-30	1.25-5.75 (0.90-4.03)	
LuxSmart Toric IOL	Bausch+Lomb	Hydrophobic acrylic lens	11 mm	6.0-34	0.75-6.0	
Tecnis Toric IOL	Johnson	Hydrophobic acrylic lens	13 mm	5.0-34	1.5-6.0 (0.75-3.62)	
Ankoris Toric IOL	PhysIOL	Hydrophilic acrylic lens	11.4 mm	6.0-30	1.5-6.0 (0.90-4.36)	
Precizon Toric IOL	Ophtec	Hydrophilic acrylic lens	12.5 mm	1.0-34	1.0-10	
Multifocal lenses						
AcrySof IQ ReSTOR IOL	Alcon	Hydrophobic acrylic lens	13 mm	6.0-34	1.0-3.0	2.5 and 3.0
AT LISA Tri Toric 939MP IOL	Zeiss	Hydrophilic acrylic lens with hydrophobic surface	11 mm	10-28	1.0-4.0	1.66 and 3.33
FineVision Toric IOL	Physiol	Hydrophilic acrylic lens	11.4 mm	6.0-35	1.0-6.0	1.75 and 3.5
TECNIS Symphony Toric IOL	Johnson	Hydrophobic acrylic lens	13 mm	5.0-34	1.5-3.75	1.75
TECNIS multifocal Toric IOL	Johnson	Hydrophobic acrylic lens	13 mm	5.0-34	1.5, 2.25, 3.0, 4.0	4.0
Panoptix Toric IOL	Alcon	Hydrophobic acrylic lens	13 mm	6.0-34	1.0-3.75	2.17 and 3.25

IOL: Intraocular lens.

the Alcon Verion Image Guided System (Alcon Laboratories, Inc., USA) and the TrueVision 3-D system (TrueVision Systems, Inc., USA).

Accurate orientation of the toric IOLs intraoperatively is necessary, because each 1 degree of rotation will bring approximately 3.5% loss of the astigmatic correction of the lens. Therefore, if the IOL is bias axis by thirty degrees, the astigmatism will remain unchanged but will be aligned at an axis different from the original steep axis^[1]. Similarly, another study showed that every 1° a toric IOL is off axis, there is a 3.3% loss of astigmatic correction^[36]. The rotation may occur in several situations: such as eyes with axial lengths exceeding 24 mm, highly myopic eyes because of weaker zonules, and residual viscoelastic materials in the capsular bag especially behind the lens^[1,37]. However, it was found that if an IOL is malpositioned because of rotation, tilt or trauma, it can safely be repositioned in the operating room up to 2wk after implantation^[38].

In cataract surgery, toric IOLs can only be implanted in an intact capsular bag but not sulcus. Conversely, in the phakic eye, the Visian Toric Implantable Collamer Lens (Staar Surgical) can be implanted in the posterior chamber behind the iris and in front of the anterior capsule to correct corneal astigmatism^[1]. It should be noted that toric IOLs should not be used in patients with irregular astigmatism or defective lens capsule.

CONCLUSION

Nowadays, three surgical approaches can be used to treat preoperative corneal astigmatism at the time of cataract surgery. Sutureless CCI was placed on the steep meridian of the cornea, single or paired PCRI were made, and toric IOL implantation was performed. By placing sutureless CCI on

the steep corneal meridians, preoperative corneal astigmatism less than 1.0 D can be corrected. Single or paired PCRI provide 1.0-3.0 D corneal astigmatism correction. Toric IOLs implantation can correct 1.0-4.5 D of corneal astigmatism. These approaches can be used alone or in combination.

ACKNOWLEDGEMENTS

Foundation: Supported by Independent Research Foundation of the 305 Hospital of PLA (No.24ZZJLW-010).

Conflicts of Interest: Yin XL, None; Ji ZY, None; Li XX, None; Liang XM, None; Ji SX, None.

REFERENCES

- 1 Keshav V, Henderson BA. Astigmatism management with intraocular lens surgery. *Ophthalmology* 2021;128(11):e153-e163.
- 2 Sigireddi RR, Weikert MP. How much astigmatism to treat in cataract surgery. *Curr Opin Ophthalmol* 2020;31(1):10-14.
- 3 Hashemi H, Khabazkhoob M, Soroush S, Shariati R, Mirafteb M, Yekta A. The location of incision in cataract surgery and its impact on induced astigmatism. *Curr Opin Ophthalmol* 2016;27(1):58-64.
- 4 Piao JJ, Joo CK. Site of clear corneal incision in cataract surgery and its effects on surgically induced astigmatism. *Sci Rep* 2020;10(1):3955.
- 5 Reddy B, Raj A, Singh VP. Site of incision and corneal astigmatism in conventional SICS versus phacoemulsification. *Ann Ophthalmol* 2007;39(3):209-216.
- 6 Pattanayak S, Mathur S, Nanda AK, Subudhi BNR. Postoperative astigmatic considerations in manual small-incision cataract surgery - A review. *Indian J Ophthalmol* 2022;70(11):3785-3790.
- 7 Roman SJ, Auclin FX, Chong-Sit DA, Ullern MM. Surgically induced astigmatism with superior and temporal incisions in cases of with-the-rule preoperative astigmatism. *J Cataract Refract Surg* 1998;24(12):1636-1641.

- 8 Barequet IS, Yu E, Vitale S, Cassard S, Azar DT, Stark WJ. Astigmatism outcomes of horizontal temporal versus nasal clear corneal incision cataract surgery. *J Cataract Refract Surg* 2004;30(2):418-423.
- 9 Kohnen T, Dick B, Jacobi KW. Comparison of the induced astigmatism after temporal clear corneal tunnel incisions of different sizes. *J Cataract Refract Surg* 1995;21(4):417-424.
- 10 Gross RH, Miller KM. Corneal astigmatism after phacoemulsification and lens implantation through unsutured scleral and corneal tunnel incisions. *Am J Ophthalmol* 1996;121(1):57-64.
- 11 Rocha-de-Lossada C, Rodríguez-Vallejo M, Rodríguez-Calvo-de-Mora M, Ribeiro FJ, Fernández J. Managing low corneal astigmatism in patients with presbyopia correcting intraocular lenses: a narrative review. *BMC Ophthalmol* 2023;23(1):254.
- 12 Hayashi K, Yoshida M, Hayashi H. Postoperative corneal shape changes: microincision versus small-incision coaxial cataract surgery. *J Cataract Refract Surg* 2009;35(2):233-239.
- 13 Lyhne N, Krogsager J, Corydon L, Kjeldgaard M. One year follow-up of astigmatism after 4.0 mm temporal clear corneal and superior scleral incisions. *J Cataract Refract Surg* 2000;26(1):83-87.
- 14 Mallik VK, Kumar S, Kamboj R, Jain C, Jain K, Kumar S. Comparison of astigmatism following manual small incision cataract surgery: superior versus temporal approach. *Nepal J Ophthalmol* 2012;4(1):54-58.
- 15 Liu ST, Liu JY, Lin F, Yu LH, Cheng CW, Wang T, Zhou XT. Efficacy comparison between steep-meridian incision and non-steep-meridian incision in implantable collamer lens surgery with low-to-moderate astigmatism. *Ophthalmol Ther* 2023;12(3):1711-1722.
- 16 Villegas EA, Alcón E, Artal P. Minimum amount of astigmatism that should be corrected. *J Cataract Refract Surg* 2014;40(1):13-19.
- 17 Abu-Ain MS, Al-Latayfeh MM, Khan MI. Do limbal relaxing incisions during cataract surgery still have a role? *BMC Ophthalmol* 2022;22(1):102.
- 18 Rubenstein JB, Raciti M. Approaches to corneal astigmatism in cataract surgery. *Curr Opin Ophthalmol* 2013;24(1):30-34.
- 19 Osawa R, Oshika T, Sano M, Yuguchi T, Kaiya T. Rotational stability of modified toric intraocular lens. *PLoS One* 2021;16(3):e0247844.
- 20 Amesbury EC, Miller KM. Correction of astigmatism at the time of cataract surgery. *Curr Opin Ophthalmol* 2009;20(1):19-24.
- 21 Kaufmann C, Peter J, Ooi K, Phipps S, Cooper P, Goggin M, Queen Elizabeth Astigmatism Study Group. Limbal relaxing incisions versus on-axis incisions to reduce corneal astigmatism at the time of cataract surgery. *J Cataract Refract Surg* 2005;31(12):2261-2265.
- 22 Truffer O, Abler D, Pajic B, Grabner G, Kraker H, Büchler P. Optimization of surgical parameters based on patient-specific models: Application to arcuate keratotomy. *J Cataract Refract Surg* 2019;45(8):1084-1091.
- 23 Viona V, Soebijantoro I, Gondhowiardjo TD. Combined femtosecond laser-assisted keratotomy and cataract surgery for enhancing refractive outcomes. An Indonesian case study. *Clin Ophthalmol* 2023;17:2983-2996.
- 24 Rani K, Grover AK, Singh AK, Grover T, Garg SP. Correction of preexisting astigmatism by penetrating arcuate keratotomy in femtosecond laser-assisted cataract surgery. *Indian J Ophthalmol* 2020;68(8):1569-1572.
- 25 Hu ZX, Sima J, Cao JG, Ke Y, Zhang YY, Guo QT, He YP, Liao HX, Tan X, Qin B, Li L. Symmetrical femtosecond laser arc incision in correcting corneal astigmatism in cataract patients. *Int J Ophthalmol* 2023;16(12):1996-2003.
- 26 Stanojic N, O'Brart D, Hull C, Wagh V, Azan E, Bhogal M, Robbie S, Li JO. Corneal astigmatic outcomes after femtosecond laser-assisted cataract surgery combined with surface penetrating arcuate keratotomies. *Int J Ophthalmol* 2023;16(7):1084-1092.
- 27 Poll JT, Wang L, Koch DD, Weikert MP. Correction of astigmatism during cataract surgery: toric intraocular lens compared to peripheral corneal relaxing incisions. *J Refract Surg* 2011;27(3):165-171.
- 28 Singh VM, Ramappa M, Murthy SI, Rostov AT. Toric intraocular lenses: Expanding indications and preoperative and surgical considerations to improve outcomes. *Indian J Ophthalmol* 2022;70(1):10-23.
- 29 Mukhija R, Fonseca A, Borkum S, Frattaroli P, Barbon E, Nanavaty MA. Toric intraocular lens versus peripheral corneal relaxing incisions for astigmatism between 0.75 and 2.5 diopters: 5-years outcomes. *Curr Eye Res* 2024;49(1):46-52.
- 30 Shimizu K, Misawa A, Suzuki Y. Toric intraocular lenses: correcting astigmatism while controlling axis shift. *J Cataract Refract Surg* 1994;20(5):523-526.
- 31 Bao T, Wang LF, Liu CH, Yang YJ, Pang YL. Analysis of biometric parameters of cataract eyes measured with optical biometer Lenstar LS900, IOL Master 700, and OPD-SCAN III. *Photodiagn Photodyn Ther* 2023;43:103646.
- 32 Jiang JH, Pan XJ, Zhou MM, Wang XY, Zhu H, Li DF. A comparison of IOLMaster 500 and IOLMaster 700 in the measurement of ocular biometric parameters in cataract patients. *Sci Rep* 2022;12:12770.
- 33 Zheng TY, Xu J, Lu Y. Comparison of the accuracy of four Pentacam corneal astigmatism values in non-toric pseudophakic eyes. *Graefes Arch Clin Exp Ophthalmol* 2020;258(4):795-803.
- 34 Tutchenko L, Patel S, Voytsekhivskyy O, Skovron M, Horak O. The influence of routine uncomplicated phacoemulsification on the orthogonality of the cornea. *Indian J Ophthalmol* 2021;69(5):1073-1079.
- 35 Niu YY, Lin HL, Qin YJ, Yang C, Chen YL, Zeng J, Zhang HY. Three-random-point marking method for toric intraocular lens alignment using the iTrace aberrometer. *J Ophthalmol* 2021;2021:6695454.
- 36 Viestenz A, Seitz B, Langenbacher A. Evaluating the eye's rotational stability during standard photography: effect on determining the axial orientation of toric intraocular lenses. *J Cataract Refract Surg* 2005;31(3):557-561.
- 37 Patnaik JL, Kahook MY, Berdahl JP, Hardten DR, Wagner BD, Seibold LK, Kramer BA. Association between axial length and toric intraocular lens rotation according to an online toric back-calculator. *Int J Ophthalmol* 2022;15(3):420-425.
- 38 Hu EH. Repositioning rates of toric IOLs implanted in cataract surgery patients: a retrospective chart review. *Clin Ophthalmol* 2023;17:4001-4007.