

Retinal displacement after surgery for idiopathic macular hole

He-Cong Qin, Fu-Qiang Li, Si-Yan Jin, Jin-Song Zhao

Department of Ophthalmology, the Second Hospital of Jilin University, Changchun 130000, Jilin Province, China

Correspondence to: Jin-Song Zhao. Department of Ophthalmology, the Second Hospital of Jilin University, Changchun 130000, Jilin Province, China. jinsong@jlu.edu.cn

Received: 2023-10-27 Accepted: 2024-03-29

Abstract

• **AIM:** To review and summarize the mechanism hypothesis, influencing factors and possible consequences of macular retinal displacement after idiopathic macular hole (IMH) surgery.

• **METHODS:** PubMed and Web of Science database was searched for studies published before April 2023 on “Retinal displacement”, “Idiopathic macular holes”, and “Macular displacement”.

• **RESULTS:** Recently, more academics have begun to focus on retinal displacement following idiopathic macular holes. They found that internal limiting membrane (ILM) peeling was the main cause of inducing postoperative position shift in the macular region. Moreover, several studies have revealed that the macular hole itself, as well as ILM peeling method, will have an impact on the result. In addition, this phenomenon is related to postoperative changes in macular retinal thickness, cone outer segment tips line recovery, the occurrence of dissociated optic nerve fiber layer (DONFL) and the degree of metamorphopsia.

• **CONCLUSION:** As a subclinical phenomenon, the clinical significance of postoperative macular displacement cannot be underestimated as it may affect the recovery of anatomy and function.

• **KEYWORDS:** idiopathic macular holes; internal limiting membrane peeling; retina displacement

DOI:10.18240/ijo.2024.08.21

Citation: Qin HC, Li FQ, Jin SY, Zhao JS. Retinal displacement after surgery for idiopathic macular hole. *Int J Ophthalmol* 2024;17(8):1545-1556

INTRODUCTION

The occurrence of macular holes (MHs) has been identified as being partially related to trauma, inflammation, and

high myopia according to research studies^[1-4]. Whereas, the majority of MHs with unidentified causes are classified as idiopathic macular holes (IMHs)^[5]. Vitrectomy in combination with internal limiting membrane (ILM) peeling is currently the primary surgical approach to manage MHs, given that it is caused by retinal interface adhesion in the vitreous macular region^[6]. In 2010, Shiragami *et al*^[7] identified 27 out of 43 patients with rhegmatogenous retinal detachment (RRD), who underwent vitrectomy, with unintentional downward retinal displacement, resulting in the introduction of the “retinal displacement” concept. Over the past decade, an increasing number of researchers have focused on macular displacement after MH surgery as shown in Table 1^[8-31]. Following IMH surgery, scholars have selected the same intersection points of retinal vessels on preoperative and postoperative optical coherence tomography (OCT), fundus autofluorescence (FAF), optical coherence tomography angiography (OCTA), and even color fundus images, as characteristic markers to measure the distance between intersection points and the macular center. This has allowed for the determination of the direction of displacement and the degree of macular migration after surgery^[8-15]. Reports indicate that macular displacement can be linked to the degree of metamorphopsia after surgery^[9,16]. Yet, the occurrence of displacement could be brought on by the natural hole-closure process that occurs after surgery or by the influence of other factors like the MH or the surgical procedure. Therefore, additional clinical and morphological evaluations are warranted to explore the principles and related factors of this phenomenon. Despite the emergence of the displacement concept in recent years, its mechanism, contributing factors, and potential implications remain unclear. This paper aims to review and summarize the current studies on the aforementioned aspects, to establish the foundation for future investigations regarding this particular appearance.

WHAT IS MACULAR DISPLACEMENT? DIRECTIONS AND MECHANISMS

As mentioned earlier, the concept of retinal displacement was first proposed in postoperative studies of RRD^[7]. However, this macular shift differs from the shift of the entire retina that occurs after retinal neuroepithelial detachment and reattachment in RRD eyes, which usually results in a regional

Postoperative macular displacement

Table 1 Summary of clinical studies on macular displacement

Author	Year	Study type	Total number of samples (eyes)	Imaging mode	Final follow-up time after surgery	Macular displacement phenomenon	Conclusion
Kim ^[17]	2012	Prospective study	(MH)31	OCT image	6mo	Asymmetric elongation of foveal tissue	After the postoperative hole closure, the foveal tissue elongates asymmetrically, and this phenomenon is related to metamorphopsia.
Kawano ^[14]	2013	Retrospective study	(MH)54	OCT image	>6mo	Retina around the MH moves centripetal and toward the optic disc	No significant change in the distance between the optic disc and macula was observed after the spontaneous closure of the MH. However, in the successful closure of the MH after ILM peeling, the macula shifted towards the optic disc.
Nakagomi ^[13]	2013	Retrospective study	(MH)27	Color fundus image	Average of 9mo (range, 6–18mo).	Macular slip toward the optic disc	Macular slippage is related to postoperative parafoveal asymmetry and the appearance of dissociated optic nerve fiber layer.
Itoh ^[18]	2014	Retrospective, interventional case series	(MH)35	OCT image	12mo	Displaced nasally	Temporal COST line recovery was delayed compared to nasal recovery possibly due to the displacement of the temporal retina from the nasal macula by stretching forces.
Ishida ^[15]	2014	Retrospective interventional observational case series study	(MH)21	FAF or near-infrared image.	12mo	Toward optic disc	The displacement of the temporal retina in the macular region displayed a stronger correlation with the diameter of the MH compared to the nasal retina.
Rodrigues ^[9]	2016	Prospective study	(ERM)21, (MH)12	FAF image	2mo	MH : retina of fovea contracting	After MH surgery, the retina in macular area moves centripetally .
Ohta ^[19]	2017	Retrospective case report	(MH)2	OCT image	6mo	Move nasally	After ILM peeling ,the macular moved nasally relative to the original position.
Lee ^[20]	2017	Retrospective controlled study	(MH)44	OCT image	6mo	Vascular displacement of the macula toward the horizontal raphe, the optic disc, and slightly inferiorly	No significant difference in retinal vascular displacement was found between the ILM flap inversion and the traditional ILM removal group for IMH.
Baba ^[21]	2017	Non randomized, retrospective series	(MH)16	OCTA image	3mo	The foveal tissue move centripetally	The removal of the ILM might be related to the postoperative centripetal movement of foveal tissue.
Cho ^[22]	2017	Retrospective case series	(MH)18	OCT, OCTA image	At least 12mo	Toward the optic disc, centripetal contraction	ILM peeling displaces the fovea to the optic disc, causing a stretch of the temporal retina. This leads to reduced centripetal movement of the fovea as there is less tissue redundancy.
Faria ^[11]	2018	Nonrandomized prospective interventional study	(MH)36	OCT image	6mo	Toward optic disc	ILM detachment is linked to alterations in the retina's inner structure and thickness, as well as a reduction in distance between the fovea and the optic disc.
Akahori ^[10]	2018	Retrospective, observational case series	(MH)20	OCTA and OCT image	2mo	Toward the optic disc, centripetal contraction and rotation downward	The macular retina shifted to the nasal side and partially upwards due to gas buoyancy post-surgery. This displacement can occur soon after surgery or during the closure of an MH.
Kumagai ^[23]	2018	Retrospective cross-sectional study	(ERM)56, (MH)46	OCTA image	The average interval from operation to FAZ measurement was 78mo	Centripetal movement	After ILM peeling, FAZ decreased was a significant negative correlation with fovea thickness. It is suspected that the decrease in FAZ is the result of the centripetal movement of the inner layer of the retina after ILM stripping.
Shiono ^[8]	2019	Retrospective controlled study	(MH)42	OCT image	1mo	Toward the optic disc	Half-temporal ILM peeling has less retinal displacement than 360° traditional ILM peeling.
Lee ^[24]	2019	Retrospective study	(MH)26	OCT image	6mo	Displaced nasally and slightly inferiorly	The displacement of the photoreceptor and inner retinal layers was concurrent after ILM movement.
Goto ^[25]	2019	Cross-sectional retrospective study	(MH)22	FAF, OCT, OCTA image	2mo	Displaced nasally, downwardly, and centripetally toward the center of the optic disc	The retina and choroid in the macular area were displaced nasally after MH surgery, but the degree of displacement was different.
Nair ^[12]	2020	Retrospective interventional case series	(MH)40	OCT image	2mo	Temporal movement was present in 25%, nasal movement was present in 75%.	The MH's displacement direction is influenced by the ratio of the temporal to nasal segments at its base, while the ratio of temporal arm to nasal arm of the hole has no impact on the displacement.
Ohta ^[26]	2020	Non-randomized retrospective study	(MH)40	OCT image	>6mo	Displaced nasally	The degree of postoperative macular displacement is not related to postoperative stereopsis.
Yilmaz ^[27]	2021	Retrospective, observational, research	(MH)57	Multi-color, SLO and B-scan SD-OCT image	12mo	Toward optic disc	Temporal ILM flap inversion has advantages over 360° ILM peeling including faster visual rehabilitation, lower incidence of visual metamorphosis, and reduced foveal displacement.
Liu ^[28]	2021	Retrospective controlled study	(MH)22	FAF image	6mo	Toward optic disc	The direction of ILM (nasal temporal or temporal nasal) peeling is not related to postoperative retinal displacement.
Park ^[16]	2021	Retrospective, interventional, consecutive case series	(MH)28	OCT image	6mo	Toward optic disc	The displacement of parafoveal tissue following ILM peeling led to perifoveal deformation and postoperative metamorphopsia.
Takeyama ^[29]	2022	Retrospective, consecutive, case series study	(MH)42	OCT image	6mo	Toward optic disc	The degree of macular displacement is related to the inner nuclear layer thickness change.
Kwak ^[30]	2023	Retrospective controlled case series	(MH)52	OCT image	12mo	Toward optic disc	The inverted ILM flap technique resulted in faster BCVA and outer retinal layer recovery, while effectively protecting against postoperative foveal thinning and displacement.
Takeyama ^[31]	2023	Retrospective, consecutive, case series study	(MH)41	OCT image	6mo	Toward optic disc	Macular retinal displacement does not affect postoperative metamorphopsia, as this is primarily caused by photoreceptor displacement and inner retinal change. The most accurate predictor is the diameter of the MH.

FAZ: Foveal avascular zone; COST: Cone outer segment tips; BCVA: Best-correct visual acuity; SLO: Simultaneous confocal scanning laser ophthalmoscopy; ERM: Epiretinal membrane; MH: Macular hole; FAF: Fundus autofluorescence; ILM: Internal limiting membrane; OCT: Optical coherence tomography; OCTA: Optical coherence tomography angiography; SD-OCT: Spectral domain optical coherence tomography; IMH: Idiopathic macular hole.

displacement of the macular area and surrounding retinal tissue after ILM detachment (Figure 1). In 2013, Kawano *et al*^[14] conducted a study which revealed that the tissue surrounding

the MH moves inward and the entire macular shifts toward the optic disc after IMH surgery. This was further confirmed by Nakagomi *et al*^[13] in the same year, who observed a shortening

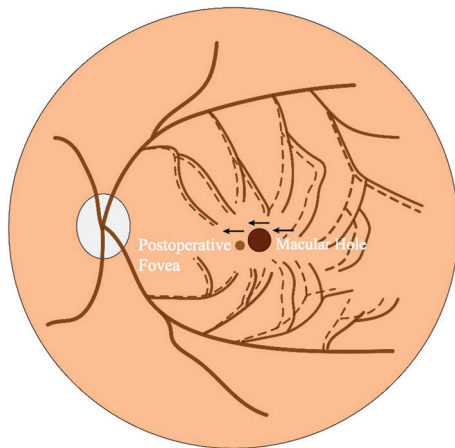


Figure 1 Macular displacement toward the optic disc after surgery
The fovea shift to the optic disc after ILM peeling, the dashed lines represent the retina and blood vessels near the macular area displace nasally after surgery, and the movement range of the temporal retina was larger. ILM: Internal limiting membrane.

of the distance between the optic disc and fovea after ILM peeling. This phenomenon was confirmed in subsequent studies^[10,13,22,25]. Additionally, after the closure of the MH, postoperative OCTA images have shown a significant reduction in the area of the foveal avascular zone (FAZ), indicating the hole edge's centripetal movement^[10,21,23,25]. This movement is thought to be related to the proliferative process of glial cells induced by ILM stripping^[32]. The ILM is composed of the foot processes of Müller cells, and its mechanical strength can be up to 1000 times that of the cell layer, providing stiffness support for the retina. This results in centrifugal traction being applied to the macular area^[33-34], causing both edges of the hole to close centripetally after ILM peeling. However, the mechanism of the macular retina towards the optic disc has not been confirmed by conclusive morphological studies. But Ishida *et al*^[15] found that the temporal retina in the macular region tends to toward the optic disc more than the nasal. This is due to the increased flexibility of the retina after ILM detachment, whereas in normal eyes, the temporal ILM has a stronger traction on the retina than the nasal retina because of the lack of ILM on the optic disc surface^[14]. While the nasal retina is close to the fixed optic disc, so the temporal retina is then more flexible after ILM forces are released, allowing for more extensive movement to facilitate coverage and closure of the basement^[15]. Thus, at the macroscopic level, the nasal displacement of the macula is the result of a rebalancing of forces on the nasal and temporal retinas after ILM stripping. On a microscopic level, ILM removal can disturb the inherent microenvironment on the macular area surface, leading to contact between exposed retinal nerve fibers and material in the vitreous cavity^[15], and lead to depolymerization of nerve fiber microtubules and axon contraction. Alternatively,

the movement of the macula to the side of the optic disc could be attributed to the contractile nature of myosin-actin interaction^[35-36]. In conclusion, the nasal retina of the macula is subjected to two opposing forces, namely the contraction of the RNFL due to the centripetal closure of the foramen and the fixation pull of the optic disc, but the temporal region of the macular is subjected to these two forces in the same direction. Therefore, the difference in the contraction force of the temporal retina leads to the movement of the temporal retina more than the nasal retina, and the macular is closer to the optic disc as a whole^[37]. Therefore, ILM peeling is a necessary step for nasal macular displacement after macular surgery. Interestingly, Akahori *et al*^[10] noted a slight downward displacement of the macular area after surgery, with the phenomenon potentially due to the buoyancy of inflation gas in the eye and the patient's poor prone position in the short term after surgery, besides the gravity factors^[20,25].

It is worth noting that Liu *et al*^[28] found that postoperative macular displacement toward the optic disc occurred in all eyes with ILM peeling. However, among the 21 cases of IMH observed by Ishida *et al*^[15], the characteristic vascular markers on the nasal retina of 2 cases and the temporal retina of 1 case moved away from the optic disc after surgery. Similarly, Nair *et al*^[12] reviewed 40 IMH eyes and found that up to 25% of those eyes experienced postoperative temporal displacement. However, in previous studies, this phenomenon could potentially be indicative of a small portion of the complete sample size. It did not significantly impact the results of the overall movement to the nasal side, leading it to be overlooked. The presence of temporal displacement in a limited number of patients warrants our attention. Future research will be necessary to explore any unknown factors that may contribute to this phenomenon.

START AND END TIME OF DISPLACEMENT

In the observation of macular displacement after IMH, the duration of the last follow-up varied from 1 to 12mo post-surgery. In most reports, the vitreous cavity is filled with inert gas after pars plana vitrectomy (PPV), which takes a relatively long time to absorb in the eye. Therefore, the initial fundus observation is conducted approximately 7-14d postoperatively^[15,18,29]. Studies have shown that the optic disc-macular distance during follow-up within 1-2wk after surgery is significantly shortened when compared to that before surgery^[14]. Akahori *et al*^[10] and Goto *et al*^[25] also found that the movement of the macular to the side of the optic disc can be observed 2wk after surgery, however, the degree of displacement after 2wk was no longer significant^[29]. Therefore, the researchers believe that the displacement and the closure of the hole occur in the same period, so the occurrence of the two is considered to be related^[10]. Kawano *et al*^[14] also speculated

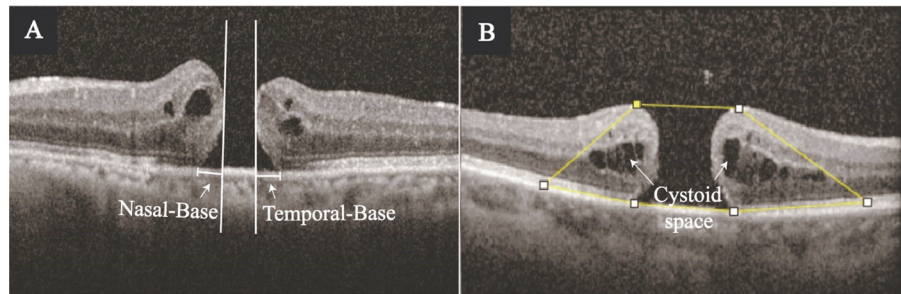


Figure 2 Horizontal cross-sectional SD-OCT images A: The white arrow indicates the nasal and temporal basal segments of the macular hole; B: The area selected by the wireframe indicates the area affected by traction around the hole, and the white arrow indicates the intraretinal cystoid cavities. SD-OCT: Spectral domain optical coherence tomography.

that displacement may be a favorable factor for the closure of MH. However, in some studies with longer follow-up time, Itoh *et al*'s^[18] conclusion is different from the above. They found that displacement movement can last for 12mo after surgery. but the degree of displacement between 6 and 12mo was far less obvious than that in the first 6mo after. Therefore, it is still controversial when the displacement should stop. However, regarding the onset time of displacement, more early postoperative observations are needed to determine in the future.

PREOPERATIVE RELATED FACTORS

The preoperative diameter is commonly utilized as a prognostic indicator for postoperative anatomic and functional recovery in MHs^[31,38-39]. Previous studies have noted that IMH frequently causes displacement of the macula towards the nasal direction^[10-11]. Specifically, Ishida *et al*'^[15] found that larger preoperative basal diameters were associated with greater degrees of nasal displacement after surgery. Akahori *et al*'^[10] and Takeyama *et al*'s^[29] conclusion is consistent with this. Because the nasal retina is relatively fixed due to the existence of the optic disc, the contribution of the temporal retina is greater in the process of displacement. Larger basal diameters typically require greater motion of the temporal retina to cover the base and promote healing of the hole^[15]. For minimal diameter, the research results of Takeyama *et al*'^[29] and Ishida *et al*'^[15] denied the correlation between it and the degree of displacement. In the study of other diameters, Nair *et al*'^[12] found no association between arm length and the length of basal nasal and temporal segments (Figure 2A, the image has been approved by the Second Hospital of Jilin University, No.2022-020, and obtain the informed consent of the patient), and displacement. However, as described above, they also observed a temporal shift of the fovea in some patients after surgery and found that eyes with a longer temporal basal segment were more likely to have a temporal shift than eyes with a longer nasal basal segment^[12]. This shift tended to occur more frequently in eyes with a longer temporal basal segment, indicating a greater detachment of the temporal retina from the

retinal pigment epithelium (RPE) layer and thus requiring more repair time at the temporal edge after surgery. Consequently, the nasal retina is more likely to move with the temporal retina in such instances, as it is relatively less detached from the RPE^[12].

Moreover, there has been a recent proposition among scholars that the use of the area parameter of the MH is a more reliable indicator in predicting postoperative closure compared to the traditional diameter parameter, and scholars contend that the area parameter is better suited to reflect the traction force surrounding the MH^[40-41], as evidenced by the presence of fluid cysts at the edge of the hole resulting from traction^[42] (Figure 2B, the image is derived from real patient data and has been approved by the Ethics Committee of the Second Hospital of Jilin University, No. 2022-020, with the informed consent of the patient). The area of these cysts has been found to be significantly associated with preoperative basal diameter, height of the edge on both sides of the hole, and preoperative best-corrected visual acuity^[43-45], which suggests that the affected area can accurately indicate the degree of preoperative vitreomacular traction. Further investigations by Venkatesh *et al*'^[40] have revealed that a greater range of mechanical traction before surgery could lead to more flexible edges of the hole after force release, and in turn, improve the chances of successful closure. In addition, Ishida *et al*'^[15] proposed that after IMH, the temporal retina of the macula is more flexible than the nasal side, thus causing the macula to slide to the nasal side. Previous studies on macular displacement have always been based on the successful closure of the hole after surgery, and the closure of the hole may be related to the occurrence of displacement^[10,14]. Therefore, it is worth exploring whether the release of a large traction force at the hole before surgery is conducive to the closure of the hole, and whether it will also result in a greater degree of nasal displacement. Moreover, the size of the cystic cavity area was significantly correlated with the preoperative basal diameter, and the displacement was confirmed to be correlated with the basal diameter, so it is worth exploring whether there is a

correlative link between cystic cavity area and displacement. In our recent study, we unexpectedly found that the temporal side of the macular hole was more affected traction than the nasal side preoperatively, leading to greater postoperative displacement^[46].

At present, literature contains a limited number of studies examining the influence of characteristics of the MH itself on displacement, and most of them are based on the basal diameter and the minimum diameter line. Since the observation of the displacement phenomenon is based on the successful closure of holes after surgery, all kinds of indicators affecting the closure of holes should be further included in the study in the future.

OPERATION FACTOR

Internal Limiting Membrane Peeling First, in 1997, Eckardt *et al*^[47] first reported ILM peeling for the treatment of IMH. PPV combined with ILM peeling has become a common method for the treatment of IMH. However, Kawano *et al*^[14] compared patients with spontaneous closure of MH with who underwent ILM peeling and found that there was no significant retinal displacement in the macular area after spontaneous closure of MH. Yoshikawa *et al*^[48] also found that even after ILM peeling for diabetic macular edema, the macular area also showed the same displacement in the same direction. In the previous study of Epiretinal membrane (ERM), patients underwent ERM and ILM peeling. They observed a nasal shift of the macular area after surgery^[49-50]. Rodrigues *et al*'s^[9] study did not perform ILM peeling in ERM patients, it was also observed that the postoperative macular area moved to the nasal side. However, this phenomenon can be explained by the fact that in most cases, there is more space in the temporal retina of the macular fovea to facilitate the coverage of the ERM, so the center of contraction force is usually located on the temporal retina of the macular fovea, dragging the fovea to the temporal side, so that the nasal position shift will occur after the traction force of the ERM is released^[49]. Furthermore, we speculate that during ERM peeling, the physician is unable to determine whether the ILM in the macular is removed at the same time because it is tightly adhered to the ERM. Therefore, the findings of this ERM study cannot deny the importance of ILM peeling for macular displacement. Then, Faria *et al*^[11] also found that ILM stripping is related to the change and displacement of the inner structure of the retina^[48]. The researchers believed that ILM peeling affects macular morphology not only through the release force of tangential traction mediated by the remaining cellular components in the anterior retina but also due to loss of structural support^[13-14]. The ILM helps to increase the strength of the retina^[33], and once it is stripped, retinal compliance increases, the temporal traction force disappears. Under the pulling force of the optic disc, the macular shifts nasally.

Additionally, the Müller cell foot processes form the ILM, it also runs through the whole thickness of the retina. After the ILM as the basement membrane is torn off, the structure of the Müller cells changes; damage to the foot processes at the end of Müller cells may especially cause displacement^[51]. Therefore, ILM peeling is vital for macular displacement^[14,51].

Internal Limiting Membrane Peeling Technique The traditional MH surgical treatment technique is vitrectomy with 360° ILM peeling near the fovea. In recent years, many scholars have continuously improved the ILM peeling technique, such as ILM packing, the inverted ILM technique, *etc.* In 2010, Michalewska *et al*^[32] proposed the inverted ILM technique, which was found to provide better results than traditional ILM peeling for treating MH larger than 400 μm. Subsequent studies confirmed that the inverted ILM flap technique is effective for improving the closure rate of large MH and improving visual acuity after surgery^[52-53]. Recent research has shown that the ILM flap covering technique can also provide better functional and morphological results in the treatment of small and medium full-thickness MH in the postoperative follow-up of up to one year^[54]. Since the flip technique was proposed, surgeons have made several improvements to it in recent years^[55-56]. The purpose of the ILM peeling technique is to form a compartment at the hole to some extent, which provides a relatively closed environment for the proliferation of glial cells^[56], and to retain the ILM flap as the basement membrane to improve the scaffold for the proliferation of glial cells to achieve the purpose of closure^[57-59]. In studies of postoperative macular displacement, Lee *et al*^[20] did not find any difference in postoperative macular displacement between the traditional ILM peeling group and the ILM peeling group. However, Yilmaz *et al*^[27] found that the foveal displacement of the former lasted for 6mo after surgery, the latter did not change significantly after 1mo. In terms of function, the postoperative visual acuity of the inverted ILM flap group recovered faster, and the portion of subjective visual distortion was lower. Kwak and Byeon^[30] also supports the conclusion that the ILM flap inversion group can reduce the degree of foveal displacement after surgery. Because the scope of ILM peeling is relatively small, this minimally invasive method does not damage the original structure of Müller cells and inner retina to a certain extent and reduces the postoperative position movement^[27]. Similarly, some researchers tried the method of simple peeling of the hemi-temporal ILM. After comparison, it was found that the hemi-temporal peeling method could ensure the closure rate while reducing the displacement of the macular to the nasal side. This suggests that the temporal retina plays an important role in the closure of the hole^[8]. ILM peeling relieved the tangential traction of the temporal side of the macular fovea^[33].

As the ILM provides 50% of the retina's stiffness, stripping it increases the compliance of the retina and causes its movement^[2]. Therefore, the conclusions of the above studies suggest that the narrowing of the extent of ILM peeling can reduce the degree of postoperative foveal displacement.

Internal Limiting Membrane Peeling Direction Considering that different starting positions lead to different directions during ILM peeling, pull forces in different tangential directions may be generated on the retina. Researchers compared the ILM peeling mode from the temporal side to the nasal side (T-N) and N-T^[28]. They found that after the successful closure of the hole, there was no difference in the distance between the fovea and the optic disc between the two groups. Therefore, the traction force of ILM peeling in different directions does no effect on the displacement results.

In addition to the above-mentioned studies on membrane tearing methods, ILM tamponade, massage at the edge of the hole, autologous serum, and nerve growth factor injection have also been tried by surgeons to promote the closure of large holes in recent years^[60-61]. But there is no relevant report on whether these improved surgical methods and different ILM flap initiation points affect the change of foveal displacement after the closure of the hole. Therefore, large sample studies are needed to explore the extent and method of ILM peeling that can effectively reduce postoperative macular displacement.

CLINICAL SIGNIFICANCE

Anatomical Prognosis

Retinal thickness Many researchers have measured the retinal thickness of the fovea and the parafovea after MH closure^[11,62-63]. Ohta *et al*^[63] found that the angle of the nasal side after ILM stripping was greater than that of the temporal side by measuring the angle between the horizontal line of the retinal RPE and the slopes of both sides of the closed fovea in postoperative OCT images. Then in Nakagomi *et al*'s^[13] study, they found that this asymmetry was the result of changes in the thickness of the nasal and temporal retina, and called it the parafovea asymmetry (PFA) phenomenon. Kim *et al*^[17] found that PFA can still be observed in some patients 6mo after the operation. The total thickness of the outer segment of the retina near the nasal macular area increases, which is different from that of the temporal retina, which reduces. Asymmetrical recovery of the fovea predicts postoperative inconsistency in bilateral thickness^[11]. Based on this, Yoshikawa *et al*^[48] found a positive correlation between the shortening of the distance from the optic disc to the fovea and the thinning of the temporal retina thickness after surgery. Takeyama *et al*^[29] also observed that the greater the degree of postoperative macular displacement to the optic disc, the thinner the parafoveal temporal inner nuclear layer (INL). On the one hand, the INL contains a large number of retinal cell

bodies, which are rich in water, while the other retinal layers are rich in fibers. Therefore, the INL is relatively susceptible to thickening after displacement^[64]. On the other hand, PFA occurs due to increased flexibility of the retina around the macular area after ILM peeling. The nasal retina may become thicker due to relaxation, while the temporal retina expands and becomes thinner due to traction^[13]. Although there was no correlation between nasal retinal displacement and any rate of retinal thickness change in the nasal region, the postoperative thickness of the nasal retinal nerve fiber layer (RNFL) layer increased significantly, which may support the hypothesis of RNFL contraction^[35]. In summary, macular displacement towards the optic disc may cause relative thinning of the temporal retina after surgery.

In addition, Baba *et al*^[21] found that the FAZ of patients with MH undergoing ILM removal decreased after the operation, suggesting that this represents the centripetal contraction of macular fovea tissue after the operation. Kumagai *et al*^[23] also believes that the reduction of the FAZ in patients with MH after ILM stripping may be the result of the displacement of the inner layer of the retina to the fovea.

Cone outer segment tips line The integrity of the microstructure of the outer retina has a correlation with the visual acuity of patients^[65-67]. There are four continuous hyperreflective signal bands in the outer retinal structure in the macular OCT image. From inside to outside, they were the external limiting membrane, the inner segment/outer segment (now called ellipsoid zone), the cone outer segment tips (COST) line, and the RPE. Reserachers found that the recovery of COST line defect was significantly related to the postoperative foveal function and postoperative visual acuity recovery^[68-69]. Therefore, the integrity and continuity of COST are very important for prognosis. Itoh *et al*^[18] observed asymmetric recovery of the COST line in the OCT cross-sectional images of MH patients after surgery. This is different from the other three postoperative recoveries of high-reflective bands, which starts from the periphery and advances to the center of the closed MH. Moreover, during this process, they observed that the fovea constantly approached the optic disc side at the same time. They concluded that the displacement of the macula may be caused the recovery speed of the COST line to the center of the temporal side, which could not keep up with the overall speed of the fovea to the optic disc, resulting in the asymmetric recovery of the COST line in the horizontal direction (Figure 3, the image is derived from real patient data and has been approved by the Ethics Committee of the Second Hospital of Jilin University, No. 2022-020, with the informed consent of the patient).

Dissociated optic nerve fiber layer In 2001, Tadayoni *et al*^[70] first proposed the phenomenon of dissociated optic nerve

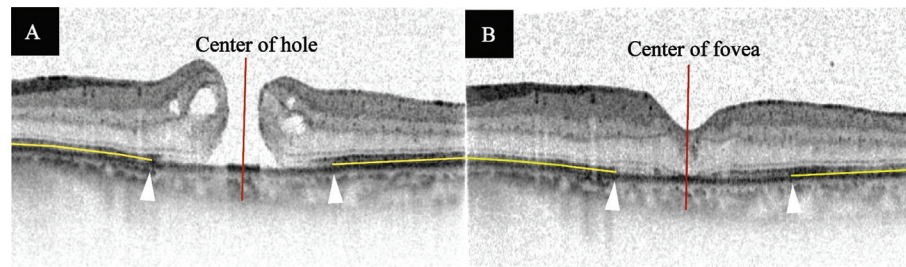


Figure 3 Horizontal cross-sectional SD-OCT images (the images were color inverted) A: The degree of COST line defect on both sides of the hole was approximately symmetrical preoperatively; B: The recovery of the COST line on both sides of the fovea was asymmetrical, and the relative recovery of the temporal side was delayed. SD-OCT: Spectral domain optical coherence tomography; COST: Cone outer segment tips.

fiber layer (DONFL). During the postoperative follow-up of ERM patients, they observed arcuate streaks on the retinal surface of the posterior pole that was darker than normal retinal tissue. In subsequent studies, it was found that the DONFL phenomenon typically appears 2 to 3mo after ILM peeling and is limited to the scope of ILM peeling^[71]. DONFL can have a “insect erosion” appearance in horizontal OCT images, mainly in the temporal retina^[72-74]. This phenomenon is considered to be related to optic nerve fiber separation caused by Müller cell endplate damage after ILM peeling^[71,75]. In addition, Tadayoni *et al*^[70] considered that the retinal surface of ILM was rough, and the irregular surface of optic nerve fibers wrapped by Müller cell processes was exposed after dissection, resulting in the appearance of DONFL. Later, Nakagomi *et al*^[13] found that the distance between the optic disc and the macula was shortened after ILM peeling in IMH eyes. Moreover, they found that the shortening of the distance between the macular and optic disc in eyes with DONFL appearance was significantly greater than that in eyes without DONFL appearance, and therefore, they considered that the displacement was related to the appearance of DONFL. The change of microenvironment in the exposed area of the RNFL layer caused by ILM peeling or the influence of unknown factors leads to the contraction of optic nerve fibers^[15]. And the traction force formed by this contraction is at the same level as the formation of the DONFL. Therefore, they considered that this delayed phenomenon may be a consequence of the tangential traction of the macular area toward the optic disc after ILM removal^[13]. Moreover, Michalewska *et al*^[56] also found that the modified temporal ILM flap inversion would cause a smaller degree of DONFL phenomenon after surgery, the technique was also effective in reducing the degree of postoperative foveal displacement to the optic disc^[27,30]. The results show that the smaller peeling area of ILM is effective in reducing the extent of postoperative DONFL and displacement phenomenon. In addition, the latest research shows that the formation of DONFL phenomenon may be related to the decrease of the inner retinal thickness, and the decrease of the temporal inner retinal thickness is greater than

that of the nasal inner retinal thickness^[72]. This may also be related to the stretching of the temporal retina parenchyma caused by displacement. In conclusion, displacement, DONFL phenomenon and ILM peeling are correlated. However, there are few studies on the correlation between DONFL and displacement. These unexpected morphological changes may be a chain effect caused by ILM peeling, which is worthy of further exploration.

Functional Prognosis

Visual acuity In the above studies of macular displacement after IMH, the visual acuity improved after surgery compared with that before surgery^[10,14,25,27,29]. Of course, the effect of combined cataract surgery on visual acuity improvement is undeniable, but it has not been found that there is any correlation between the degree of displacement and visual prognosis. In a review of 31 patients with IMH, Kim *et al*^[17] found that the fovea showed displacement of the fovea towards the optic disc after macular surgery, and found that its occurrence was not correlated with visual recovery. Similarly, Cobos *et al*^[76] reviewed 20 patients with RRD and ultimately found no association between the postoperative retinal displacement of the fovea and visual acuity. In addition, the phenomenon of macular displacement was also observed in the study of Lee *et al*^[77], and it was found that this phenomenon was correlated with metamorphopsia and distorted vision, but it did not affect the recovery of visual acuity. Kawano *et al*^[14] considered that macular displacement after surgery may cause abnormal macular function. However, the nasal shift phenomenon was found in all 54 IMH eyes after surgery, but no diplopia, pseudoesotropia, and other symptoms were found, and there was no correlation with the postoperative visual prognosis. However, previous reports have shown that displacement will affect the postoperative recovery of the COST line. The postoperative nasal movement of the macular will lead to a relatively delayed recovery of the COST line in the temporal macular area^[18], and the integrity of the microstructure of the outer retina is the key to ensuring the recovery of vision^[78-79]. In the study of Itoh *et al*^[80], it was found that the defect of the temporal COST line was related to

the visual recovery at 6mo after surgery. Therefore, whether the displacement will affect the visual prognosis by affecting the recovery of the COST line remains to be investigated in the future.

Metamorphopsia Hikichit *et al*^[81] believed that the movement of a small cluster of photoreceptors compared with other parts of the original retina causes abnormal visual field projection and metamorphopsia. Studies found that the shift of photoreceptors and the change of the inner retinal structure are important factors affecting metamorphopsia^[16,31,50]. However, the phenomenon of macular displacement after ILM peeling in IMH has attracted attention^[8,18,25,29]. It was previously believed that the centripetal movement of both edges of the postoperative hole was considered to contribute to the recovery of photoreceptor damage in the fovea and the improvement of visual acuity after IMH closure^[11]. However, studies have shown that the phenomenon of the macula moving toward the optic disc is significantly related to the persistence of metamorphopsia after surgery^[9,16,27]. They found that the asymmetric elongation of the fovea after IMH may not directly affect the photoreceptor layer, but perhaps the asymmetric tangential force from other layers hinders the recovery of the photoreceptor layer and leads to visual deformation^[17]. In addition, there are three-level neural networks in the retina of normal human eyes. Pyramidal cells, bipolar cells, and ganglion cells constitute the visual signal transmission pathway. Researchers considered that any level of position change can interfere with the one-to-one conduction relationship among the above-mentioned neurons, resulting in visual dysfunction^[82]. Researchers also found that the change in INL thickness was related to metamorphopsia, considering that it was related to the presence of bipolar cells in the INL. Takeyama *et al*^[29] observed a correlation between the degree of displacement and the INL thickness; they considered that INL contains numerous retinal cell bodies that are rich in water content, unlike other retinal layers that are rich in fiber content. Therefore, the INL is relatively vulnerable following displacement^[64]. Whether the displacement affects the postoperative metamorphopsia by affecting the thickness of the INL remains to be further studied. However, Takeyama *et al*^[31] denied the correlation between displacement and metamorphopsia in their latest study. Therefore, the relationship between displacement and metamorphopsia is controversial, and whether the degree of postoperative displacement will become an effective index of metamorphopsia needs to be investigated

Stereopsis It is common knowledge that when viewing objects with both eyes, there is a slight difference in the imaging of the retina, known as parallax. It is through this parallax that we are able to perceive the depth of objects in the visual field,

also known as stereopsis. Because the retina of the fovea and parafovea shift after macular surgery, it is possible that when viewing objects, one of the binocular images will be projected on the macular fovea and the other on the parafovea^[26]. This could potentially lead to impaired stereopsis. However, research indicates that there is no relationship between macular displacement and postoperative stereopsis recovery^[26]. The same view was also expressed in the study of macular displacement in post-operative patients with RRD. It was considered that postoperative macular translocation does not affect the stereopsis^[76]. Multiple regression analysis showed that the recovery of stereopsis was significantly correlated with postoperative visual acuity^[83]. However, in previous studies, visual acuity recovered best at about 3mo after MH surgery^[84], recent research suggests that improvement of stereopsis in MH reaches its peak at 3mo after surgery and remains stable thereafter^[85]. At present, the displacement is more suspected to be related to the closure of the hiatus, which usually occurs in the early postoperative period^[10,25]. Therefore, there is no correlation between the occurrence of displacement and the recovery of stereo vision from the perspective of time.

DISCUSSION

The displacement phenomenon has been commonly observed postoperatively in patients with retinal detachment and ERM^[86-88], after which it has been found that after IMH, the edges of the MH were reattached to the RPE layer and moved centripetally with the foveal retina appearing to move closer to the optic disc side^[10-11,15,21,25]. This phenomenon has been termed as foveal displacement. A review of macular location shift after IMH was conducted in this paper, which is the first of its kind. However, there is no conclusive morphological study on the occurrence of this phenomenon or its development mechanism. Some experts believe this movement may be a favorable physiological process to help the hole closure^[14], while others suggest adverse effects of the preoperative hole morphology or surgical operation on the macular displacement. Other studies have shown that there may be multiple mechanisms and multiple retinal layers in the occurrence of this phenomenon^[12]. The latest studies have found that the displacement of the macular fovea after IMH is accompanied by the movement of the choroid and RPE layers^[25]. Therefore, the study of this phenomenon is still under continuous exploration, but the macular displacement phenomenon can be confirmed to be initiated by ILM peeling. Current findings indicate that reduction of the extent of ILM peeling can decrease the degree of macular displacement^[27], however, with the need to study whether surgical factors such as ILM starting point, ILM packing techniques or different filling materials impact displacement, and whether displacement is correlated with healing morphology. In addition to the

displacement phenomenon, the DONFL phenomenon and the swelling of the arcuate nerve fiber layer phenomenon was described type of retina changes after ILM peeling in ERM or MH^[72,89]. Study have verified that the DONFL phenomenon is correlated with the degree of fovea displacement to the optic disc and the asymmetric change of macular thickness on both sides after surgery^[13]. These unexpected changes may be a chain reaction caused by ILM peeling. Fortunately, none of the retina changes associated with peeling have been reported to affect postoperative visual acuity recovery^[71,80]. Therefore, these phenomena are more likely to be subclinical changes after surgery, but the occurrence of these phenomena does confirm that the operation of ILM peeling is bound to cause retinal damage to some extent. Together with the discovery of phenomena such as macular displacement, these will be more helpful in our understanding of the two sides of ILM peeling and help us to determine the optimal timing and method of surgery for ILM peeling.

ACKNOWLEDGEMENTS

Authors' contributions: Design of the study (Qin HC); Conduct of the study (Qin HC); Preparation of the data (Li FQ, Jin SY); Collection, management, analysis and interpretation of data (Qin HC, Li FQ); Preparation of the article (Qin HC, Jin SY); Critical revision of the article (Qin HC, Jin SY); Final approval of the article (Zhao JS); Provision of materials, patients, and resources (Zhao JS).

Conflicts of Interest: Qin HC, None; Li FQ, None; Jin SY, None; Zhao JS, None.

REFERENCES

- 1 Ye J, Wu Y, Zhu SQ, Dong L, Qu J, Lu F, Xue AQ. Evaluation of the efficacy of posterior scleral contraction in the treatment of macular hole with retinal detachment in high myopia. *Retina* 2021;41(9):1874-1882.
- 2 Kunikata H, Osada U, Abe T, Nakazawa T. Efficacy of early microincision vitrectomy surgery in traumatic macular hole. *Graefes Arch Clin Exp Ophthalmol* 2021;259(8):2451-2454.
- 3 Li YT, Jin SY, Shi LJ, Qin HC, Zhao JS. Factors associated with anatomic failure and hole reopening after macular hole surgery. *J Ophthalmol* 2021;2021:7861180.
- 4 Ozbek M, Ozcaliskan S, Alagoz C, Artunay O. Comparison of anatomical and functional outcomes of different surgical techniques in myopic macular hole without retinal detachment. *Int J Ophthalmol* 2023;16(10):1651-1656.
- 5 Cheng D, Tao JW, Yu XT, Chen YQ, Shen MX, Wu MH, Yu JF, Lian HL, Lu Z, Shen LJ. Characteristics of macular microvasculature before and after idiopathic macular hole surgery. *Int J Ophthalmol* 2022;15(1):98-105.
- 6 Ittarat M, Somkijrunroj T, Chansangpetch S, Pongsachareonnont P. Literature review of surgical treatment in idiopathic full-thickness macular hole. *Clin Ophthalmol* 2020;14:2171-2183.
- 7 Shiragami C, Shiraga F, Yamaji H, Fukuda K, Takagishi M, Morita M, Kishikami T. Unintentional displacement of the retina after standard vitrectomy for rhegmatogenous retinal detachment. *Ophthalmology* 2010;117(1):86-92.e1.
- 8 Shiono A, Kogo J, Sasaki H, Yomoda R, Jujo T, Tokuda N, Kitaoka Y, Takagi H. Hemi-temporal internal limiting membrane peeling is as effective and safe as conventional full peeling for macular hole surgery. *Retina* 2019;39(9):1779-1785.
- 9 Rodrigues IA, Lee EJ, Williamson TH. Measurement of retinal displacement and Metamorphopsia after epiretinal membrane or macular hole surgery. *Retina* 2016;36(4):695-702.
- 10 Akahori T, Iwase T, Yamamoto K, Ra E, Kawano K, Ito Y, Terasaki H. Macular displacement after vitrectomy in eyes with idiopathic macular hole determined by optical coherence tomography angiography. *Am J Ophthalmol* 2018;189:111-121.
- 11 Faria MY, Ferreira NP, Mano S, Cristóvão DM, Sousa DC, Monteiro-Grillo ME. Internal retinal layer thickness and macular migration after internal limiting membrane peeling in macular hole surgery. *Eur J Ophthalmol* 2018;28(3):311-316.
- 12 Nair U, Mohan A, Sheera KR, Indurkar A, Soman M. Macular morphometrics in foveal displacement following full thickness macular hole surgery. *Indian J Ophthalmol* 2020;68(7):1436-1440.
- 13 Nakagomi T, Goto T, Tateno Y, Oshiro T, Iijima H. Macular slippage after macular hole surgery with internal limiting membrane peeling. *Curr Eye Res* 2013;38(12):1255-1260.
- 14 Kawano K, Ito Y, Kondo M, Ishikawa K, Kachi S, Ueno S, Iguchi Y, Terasaki H. Displacement of foveal area toward optic disc after macular hole surgery with internal limiting membrane peeling. *Eye (Lond)* 2013;27(7):871-877.
- 15 Ishida M, Ichikawa Y, Higashida R, Tsutsumi Y, Ishikawa A, Imamura Y. Retinal displacement toward optic disc after internal limiting membrane peeling for idiopathic macular hole. *Am J Ophthalmol* 2014;157(5):971-977.
- 16 Park SH, Park KH, Kim HY, Lee JJ, Kwon HJ, Park SW, Byon IS, Lee JE. Square grid deformation analysis of the macula and postoperative Metamorphopsia after macular hole surgery. *Retina* 2021;41(5):931-939.
- 17 Kim JH, Kang SW, Park DY, Kim SJ, Ha HS. Asymmetric elongation of foveal tissue after macular hole surgery and its impact on Metamorphopsia. *Ophthalmology* 2012;119(10):2133-2140.
- 18 Itoh Y, Inoue M, Rii T, Ando Y, Hirakata A. Asymmetrical recovery of cone outer segment tips line and foveal displacement after successful macular hole surgery. *Invest Ophthalmol Vis Sci* 2014;55(5):3003-3011.
- 19 Ohta K, Sato A, Senda, Fukui. Displacement of fovea toward optic disk after macular hole surgery with internal limiting membrane peeling. *Int Med Case Rep J* 2017;10:345-348.
- 20 Lee JJ, Lee IH, Park KH, Pak KY, Park SW, Byon IS, Lee JE. Vascular displacement in idiopathic macular hole after single-layered inverted internal limiting membrane flap surgery. *Korean J Ophthalmol* 2017;31(4):336-342.

- 21 Baba T, Kakisu M, Nizawa T, Oshitari T, Yamamoto S. Superficial foveal avascular zone determined by optical coherence tomography angiography before and after macular hole surgery. *Retina* 2017;37(3):444-450.
- 22 Cho JH, Yi HC, Bae SH, Kim H. Foveal microvasculature features of surgically closed macular hole using optical coherence tomography angiography. *BMC Ophthalmol* 2017;17(1):217.
- 23 Kumagai K, Furukawa M, Suetsugu T, Ogino N. Foveal avascular zone area after internal limiting membrane peeling for epiretinal membrane and macular hole compared with that of fellow eyes and healthy controls. *Retina* 2018;38(9):1786-1794.
- 24 Lee SM, Park KH, Kwon HJ, Park SW, Byon IS, Lee JE. Displacement of the foveal retinal layers after macular hole surgery assessed using en face optical coherence tomography images. *Ophthalmic Surg Lasers Imaging Retina* 2019;50(7):414-422.
- 25 Goto K, Iwase T, Akahori T, Yamamoto K, Ra E, Terasaki H. Choroidal and retinal displacements after vitrectomy with internal limiting membrane peeling in eyes with idiopathic macular hole. *Sci Rep* 2019;9(1):17568.
- 26 Ohta K, Sato A, Senda, Fukui. Stereopsis after unilateral macular hole surgery with internal limiting membrane peeling. *Clin Ophthalmol* 2020;14:1777-1783.
- 27 Yilmaz S, Mavi Yildiz A, Avci R. Foveal displacement following temporal inverted internal limiting membrane technique for full thickness macular holes: 12mo results. *Curr Eye Res* 2021;46(12):1923-1930.
- 28 Liu J, Hu ZZ, Zheng XH, Li YL, Huang JL, Cao EB, Yuan ST, Xie P, Liu QH. Displacement of the retina after idiopathic macular hole surgery with different internal limiting membrane peeling patterns. *Int J Ophthalmol* 2021;14(9):1408-1412.
- 29 Takeyama A, Imamura Y, Fujimoto T, Iida T, Komiya Y, Shibata M, Ishida M. Retinal displacement and intraretinal structural changes after idiopathic macular hole surgery. *Jpn J Ophthalmol* 2022;66(2):173-182.
- 30 Kwak JJ, Byeon SH. Comparison of long-term visual and anatomical outcomes between internal limiting membrane flap and peeling techniques for macular holes with a propensity score analysis. *Eye (Lond)* 2023;37(6):1207-1213.
- 31 Takeyama A, Imamura Y, Fujimoto T, Iida T, Komiya Y, Shibata M, Ishida M. Predictors for Metamorphopsia in eyes undergoing macular hole surgery. *Sci Rep* 2023;13(1):810.
- 32 Michalewska Z, Michalewski J, Adelman RA, Nawrocki J. Inverted internal limiting membrane flap technique for large macular holes. *Ophthalmology* 2010;117(10):2018-2025.
- 33 Wollensak G, Spoerl E, Grosse G, Wirbelauer C. Biomechanical significance of the human internal limiting lamina. *Retina* 2006;26(8):965-968.
- 34 Candiello J, Balasubramani M, Schreiber EM, Cole GJ, Mayer U, Halfter W, Lin H. Biomechanical properties of native basement membranes. *FEBS J* 2007;274(11):2897-2908.
- 35 Conde C, Cáceres A. Microtubule assembly, organization and dynamics in axons and dendrites. *Nat Rev Neurosci* 2009;10(5):319-332.
- 36 Gallo G, Yee HF Jr, Letourneau PC. Actin turnover is required to prevent axon retraction driven by endogenous actomyosin contractility. *J Cell Biol* 2002;158(7):1219-1228.
- 37 Pak KY, Park KH, Kim KH, Park SW, Byon IS, Kim HW, Chung IY, Lee JE, Lee SJ, Lee JE. Topographic changes of the macula after closure of idiopathic macular hole. *Retina* 2017;37(4):667-672.
- 38 Qi Y, Yu YP, You QS, Wang ZY, Wang J, Liu W. Hole diameter ratio for prediction of anatomical outcomes in stage III or IV idiopathic macular holes. *BMC Ophthalmol* 2020;20(1):351.
- 39 Tayyab H, Siddiqui R, Jahangir S, Hashmi S. Optical Coherence Tomography based indices in predicting functional outcome of macular hole surgery: a retrospective chart review. *Pak J Med Sci* 2021;37(5):1504-1508.
- 40 Venkatesh R, Mohan A, Sinha S, Aseem A, Yadav NK. Newer indices for predicting macular hole closure in idiopathic macular holes: a retrospective, comparative study. *Indian J Ophthalmol* 2019;67(11):1857-1862.
- 41 Geng XY, Wu HQ, Jiang JH, Jiang K, Zhu J, Xu Y, Dong JC, Yan ZZ. Area and volume ratios for prediction of visual outcome in idiopathic macular hole. *Int J Ophthalmol* 2017;10(8):1255-1260.
- 42 Simpson AR, Petrarca R, Jackson TL. Vitreomacular adhesion and neovascular age-related macular degeneration. *Surv Ophthalmol* 2012;57(6):498-509.
- 43 Goto K, Iwase T, Yamamoto K, Ra E, Terasaki H. Correlations between intraretinal cystoid cavities and pre- and postoperative characteristics of eyes after closure of idiopathic macular hole. *Sci Rep* 2020;10(1):2310.
- 44 Sugiura Y, Okamoto F, Okamoto Y, Hiraoka T, Oshika T. Relationship between Metamorphopsia and intraretinal cysts within the fluid cuff after surgery for idiopathic macular hole. *Retina* 2017;37(1):70-75.
- 45 Joo JH, Nam WH, Joo T, Moon SW. Role of intraretinal cysts in the prediction of postoperative closure and photoreceptor damages of the idiopathic full-thickness macular hole. *BMC Ophthalmol* 2022;22(1):5.
- 46 Qin HC, Zhao JS, Jin SY, Zhang H. The impact of preoperative parameters on postoperative foveal displacement in idiopathic macular hole. *Sci Rep* 2024;14(1):3755.
- 47 Eckardt C, Eckardt U, Groos S, Luciano L, Reale E. Removal of the internal limiting membrane in macular holes. Clinical and morphological findings. *Ophthalmologe* 1997;94(8):545-551.
- 48 Yoshikawa M, Murakami T, Nishijima K, Uji A, Ogino K, Horii T, Yoshimura N. Macular migration toward the optic disc after inner limiting membrane peeling for diabetic macular edema. *Invest Ophthalmol Vis Sci* 2013;54(1):629.
- 49 Tung HF, Chen YL, Tung HY, Tung HW, Chen SN. Foveal displacement in eyes with epiretinal membrane after vitrectomy and membrane peeling. *Retina* 2021;41(11):2246-2252.
- 50 Watanabe A, Ishida M, Shibata M, Fujimoto T, Mizushima A, Takeyama A, Imamura Y. One-year outcomes of Metamorphopsia and retinal displacement after epiretinal membrane surgery. *Retina* 2022;42(9):1756-1761.

- 51 Kumagai K, Ogino N, Furukawa M, Ooya R, Horie E. Early centripetal displacements of capillaries in macular region caused by internal limiting membrane peeling. *Clin Ophthalmol* 2018;12:755-763.
- 52 Bleidißel N, Friedrich J, Klaas J, Feucht N, Lohmann CP, Maier M. Inverted internal limiting membrane flap technique in eyes with large idiopathic full-thickness macular hole: long-term functional and morphological outcomes. *Graefes Arch Clin Exp Ophthalmol* 2021;259(7):1759-1771.
- 53 Chen G, Tzekov R, Jiang F, Mao S, Tong Y, Li W. Inverted ILM flap technique versus conventional ILM peeling for idiopathic large macular holes: a meta-analysis of randomized controlled trials. *PLoS One* 2020;15(7):e0236431.
- 54 Bleidißel N, Friedrich J, Feucht N, Klaas J, Maier M. Visual improvement and regeneration of retinal layers in eyes with small, medium, and large idiopathic full-thickness macular holes treated with the inverted internal limiting membrane flap technique over a period of 12 months. *Graefes Arch Clin Exp Ophthalmol* 2022;260(10):3161-3171.
- 55 Hu ZZ, Qian HM, Fransisca S, Gu XY, Ji JD, Wang JN, Liu QH, Xie P. Minimal internal limiting membrane peeling with ILM flap technique for idiopathic macular holes: a preliminary study. *BMC Ophthalmol* 2020;20(1):228.
- 56 Michalewska Z, Michalewski J, Dulczewska-Cichecka K, Adelman RA, Nawrocki J. Temporal inverted internal limiting membrane flap technique versus classic inverted internal limiting membrane flap technique: a comparative study. *Retina* 2015;35(9):1844-1850.
- 57 Kase S, Saito W, Mori S, Saito M, Ando R, Dong ZY, Suzuki T, Noda K, Ishida S. Clinical and histological evaluation of large macular hole surgery using the inverted internal limiting membrane flap technique. *Clin Ophthalmol* 2017;11:9-14.
- 58 Morawski K, Kocemba-Pilarczyk K, Zarzycka M, Dudzik P, Trojan SE, Laidler P. *In vitro* culture Muller cell model to study the role of inverted internal limiting membrane flap technique in macular hole closure. *J Physiol Pharmacol* 2021;72(3).
- 59 Chatziralli I, Machairoudia G, Kazantzis D, Theodossiadi G, Theodossiadi P. Inverted internal limiting membrane flap technique for myopic macular hole: a meta-analysis. *Surv Ophthalmol* 2021;66(5):771-780.
- 60 Iwasaki M, Miyamoto H, Imaizumi H. Effects of inverted internal limiting membrane technique and insertion technique on outer retinal restoration associated with glial proliferation in large macular holes. *Graefes Arch Clin Exp Ophthalmol* 2020;258(9):1841-1849.
- 61 Li S, Zhang L, Yu JG. Inverted internal limiting membrane flap versus internal limiting membrane insertion technique for large macular holes: a meta-analysis. *Semin Ophthalmol* 2023;38(8):752-760.
- 62 Ohta K, Sato A, Fukui E. Asymmetrical thickness of parafoveal retina around surgically closed macular hole. *Br J Ophthalmol* 2010;94(11):1545-1546.
- 63 Ohta K, Sato A, Senda, Fukui. Asymmetrical steepening of the foveal contour after macular hole surgery with internal limiting membrane peeling. *Jpn J Ophthalmol* 2016;60(5):388-394.
- 64 Reichenbach A BA. Cell biology of retinal glia. In: Schachat A, editor *Ryan's Retina*. 2018;6th ed. Amsterdam, The Netherlands: Elsevier; 2018. p. 466-87.
- 65 Singh SR, Vaidya H, Borrelli E, Chhablani J. Foveal photoreceptor disruption in ocular diseases: an optical coherence tomography-based differential diagnosis. *Surv Ophthalmol* 2023;68(4):655-668.
- 66 Nakamura K, Inoue T, Nagura K, Tanaka Y, Arasaki R, Asaoka R, Yanagi Y, Maruyama-Inoue M, Kadonosono K. Foveal microstructure and visual function in patients with lamellar macular hole, epiretinal membrane foveoschisis or macular pseudohole. *Eye (Lond)* 2022;36(12): 2247-2252.
- 67 Yang XH, Wu XJ, Qi BY, Zhang K, Yu YP, Wang XB, Feng X, Jia QL, Jin ZB, Liu W. Foveal microstructure and visual outcomes after pars plana vitrectomy in patients with different types of epiretinal membrane foveoschisis. *Ophthalmic Res* 2024;67(1):137-144.
- 68 Shimozono M, Oishi A, Hata M, Matsuki T, Ito S, Ishida K, Kurimoto Y. The significance of cone outer segment tips as a prognostic factor in epiretinal membrane surgery. *Am J Ophthalmol* 2012;153(4):698-704,704.e1.
- 69 Itoh Y, Inoue M, Rii T, Hiraoka T, Hirakata A. Correlation between length of foveal cone outer segment tips line defect and visual acuity after macular hole closure. *Ophthalmology* 2012;119(7):1438-1446.
- 70 Tadayoni R, Paques M, Massin P, Mouki-Benani S, Mikol J, Gaudric A. Dissociated optic nerve fiber layer appearance of the fundus after idiopathic epiretinal membrane removal. *Ophthalmology* 2001;108(12):2279-2283.
- 71 Mitamura Y, Ohtsuka K. Relationship of dissociated optic nerve fiber layer appearance to internal limiting membrane peeling. *Ophthalmology* 2005;112(10):1766-1770.
- 72 He SC, Ye X, Qiu WL, Yang SC, Zhong XX, Chen YQ, He R, Shen LJ. Analysis of retinal microstructure in eyes with dissociated optic nerve fiber layer (DONFL) appearance following idiopathic macular hole surgery: an optical coherence tomography study. *J Pers Med* 2023;13(2):255.
- 73 Ye X, Xu JH, He SC, Wang J, Yang JL, Tao JW, Chen YQ, Shen LJ. Quantitative evaluation of dissociated optic nerve fibre layer (DONFL) following idiopathic macular hole surgery. *Eye (Lond)* 2023;37(7):1451-1457.
- 74 Kim K, Yoon K, Park JB, Kang MS, Kim ES, Yu SY. Perifoveal microvascular changes following internal limiting membrane peeling surgery for epiretinal membrane and macular hole. *Ophthalmologica* 2023;246(5-6):324-332.
- 75 Ikeda T, Nakamura K, Sato T, Kida T, Oku H. Involvement of aniois in dissociated optic nerve fiber layer appearance. *Int J Mol Sci* 2021;22(4):1724.
- 76 Cobos E, Rubio MJ, Arias L, Caminal JM, Garcia-Bru P, Català J, Jordan S, Vidal M, Gutiérrez L. Incidence and relation with anatomical and functional variables of postoperative macular displacement in rhegmatogenous retinal detachment. *Retina* 2016;36(5):957-961.

- 77 Lee E, Williamson TH, Hysi P, Shunmugam M, Dogramaci M, Wong R, Laidlaw DA. Macular displacement following rhegmatogenous retinal detachment repair. *Br J Ophthalmol* 2013;97(10):1297-1302.
- 78 Mansour HA, Uwaydat SH, Parodi M, Jürgens I, Smiddy W, Ellabban AA, Schwartz SG, Foster RE, Ascaso J, Leoz MS, Belotto S, Mateo J, Olivier-Pascual N, Lima LH, Navea A, Neila EMR, Castillo RA, Alaman AS, Mansour AM, Collaborators of the Nonsurgical Resolution of Macular Hole Study Group. Recovery course of foveal microstructure in the nonsurgical resolution of full-thickness macular hole. *Graefes Arch Clin Exp Ophthalmol* 2022;260(10):3173-3183.
- 79 Bodhankar PU, Joshi AK, Dronadula M, Patil AN. Postoperative microstructural re-modelling and functional outcomes in idiopathic full thickness macular hole. *Indian J Ophthalmol* 2022; 70(6):2077-2083.
- 80 Itoh Y, Inoue M, Rii T, Hirota K, Hirakata A. Correlation between foveal cone outer segment tips line and visual recovery after epiretinal membrane surgery. *Invest Ophthalmol Vis Sci* 2013;54(12):7302.
- 81 Hikichi T, Kitaya N, Takahashi J, Ishiko S, Mori F, Yoshida A. Association of preoperative photoreceptor displacement and improved central scotoma after idiopathic macular hole surgery. *Ophthalmology* 2002;109(11):2160-2164.
- 82 Watanabe A, Arimoto S, Nishi O. Correlation between Metamorphopsia and epiretinal membrane optical coherence tomography findings. *Ophthalmology* 2009;116(9):1788-1793.
- 83 Okamoto F, Morikawa S, Moriya Y, Sugiura Y, Murakami T, Tomioka M, Hiraoka T, Oshika T. Vision-related parameters that affect stereopsis in patients with macular hole. *Sci Rep* 2020;10(1):2805.
- 84 Ezra E, Gregor ZI, Morfields Macular Hole Study Ggroup Report No.1 Surgery for idiopathic full-thickness macular hole: two-year results of a randomized clinical trial comparing natural history, vitrectomy, and vitrectomy plus autologous serum: Morfields Macular Hole Study Group RAeport no. 1. *Arch Ophthalmol* 2004;122(2):224-236.
- 85 Okamoto F, Moriya Y, Sugiura Y, Murakami T, Morikawa S, Hoshi S, Hiraoka T, Oshika T. Stereopsis and retinal microstructures following macular hole surgery. *Sci Rep* 2020;10(1):19534.
- 86 Bazvand F, Azarkish A, Riazi-Esfahani H, Nabavi A, Khodabandeh A, Akbari M, Mirmohammadsadeghi A, Ebrahimiadib N, Khojaste H. Retinal displacement following pars Plana vitrectomy with silicone oil tamponade for rhegmatogenous retinal detachment. *Int Ophthalmol* 2021;41(9):3007-3011.
- 87 Mason RH, Minaker SA, Marafon SB, Figueiredo N, Hillier RJ, Muni RH. Retinal displacement following rhegmatogenous retinal detachment: a systematic review and meta-analysis. *Surv Ophthalmol* 2022;67(4):950-964.
- 88 Rossi T, Querzoli G, Cosimi P, Ripandelli G, Steel DH, Romano MR. Tangential retinal displacement increases after macular pucker surgery: an apparent nonsense. *Retina* 2024;44(4):610-617.
- 89 Kim DJ, Kim DG, Park KH. Three-dimensional heads-up vitrectomy versus conventional microscopic vitrectomy for patients with epiretinal membrane. *Retina* 2023;43(6):1010-1018.