

Alzheimer's visual variant: a report of a diagnosis easily missed on ophthalmic examination

Jorge Cárdenas–Belaunzarán¹, Lorena Wheelock–Gutierrez¹, Karen A. Cerrillo–Avila²

¹Department of Neuro-Ophthalmology, Association to Prevent Blindness in Mexico, I.A.P., Mexico City 04030, Mexico

²Independent Researcher, Mexico City 04040, Mexico

Correspondence to: Jorge Cárdenas–Belaunzarán. Department of Neuro-Ophthalmology, Association to Prevent Blindness in Mexico, I.A.P., Av. Vicente García Torres 46, Coyoacán, Ciudad de México 04030, México. jorge.cardenas@apec.com.mx
Received: 2023-12-19 Accepted: 2024-02-02

DOI:10.18240/ijo.2024.08.24

Citation: Cárdenas-Belaunzarán J, Wheelock-Gutierrez L, Cerrillo-Avila KA. Alzheimer's visual variant: a report of a diagnosis easily missed on ophthalmic examination. *Int J Ophthalmol* 2024;17(8):1571-1575

Dear Editor,

We present a case of posterior cortical atrophy (PCA), which is a syndromic entity caused by different neurodegenerative diseases, mainly Alzheimer's disease, but it has been described in several other entities. Its frequency is reported to be as high as 5% of all cases; however, it remains widely under-recognized among ophthalmologists and optometrists due to scarce reports in visual health-related journals^[1].

The main purpose of this report is to describe the principal signs and symptoms of PCA on ocular examination, to document how to look for them, and to raise awareness about this condition in which most patients will seek visual health specialists care during the onset of early symptoms. This study follows the tenets of the Declaration of Helsinki, was approved by the Institution's Internal Review Board and patient consent was obtained.

CASE REPORT

A 65-year-old Hispanic woman presented to clinic with bilateral painless, progressive loss of sharpness of vision, and difficulty in reading or seeing details. Four years prior, she had been evaluated for these same symptoms at another institution, and a diagnosis of normal-tension glaucoma was established. Visual field testing showed significant visual field loss with concern for a possible homonymous hemianopia (Figure 1).

The provider did feel the visual field did not match the rest of the exam and prompted neuroimaging. Magnetic resonance imaging (MRI) scan was performed and read as normal, ruling out intracranial pathology at the time (Figure 1). After normal findings on the MRI, she was initiated on travoprost *q.h.s.* in both of her eyes. Her visual symptoms worsened significantly despite intraocular pressure lowering treatment; therefore, she presented to an ophthalmologic center for a second opinion.

Her past medical history was significant for type 2 diabetes mellitus and systemic hypertension, which were controlled with metformin and amlodipine. The best-corrected visual acuity (BCVA) with Snellen's chart was 6/6 in both her eyes. The pupils were isochoric; they reacted briskly to light and dilated swiftly in the dark. Slit-lamp biomicroscopic examination showed only a narrow anterior chamber angle and mild cataracts in both eyes. The intraocular pressure was 14 mm Hg in both eyes on topical travoprost. Fundus examination showed a cup-to-disk ratio of 0.6 and 0.5 in the right and left eye respectively (Figure 2). She was unable to read any of the Ishihara plates including the control plate.

A new 24-2 SITA standard visual field test, along with an optic nerve optical coherence tomography, was performed. The visual fields showed a left homonymous hemianopia while the optical coherence tomography results were within normal limits (Figure 2). Based on these findings, a broader and more detailed neuro-ophthalmological examination was performed. The patient had trouble recognizing other complex figures, such as Navon letters and Arcimboldo paintings; she incorrectly described the Boston Cookie Theft picture. On the visual object recognition test, she failed to mention half of the everyday objects presented to her. She was only able to recognize the objects once they were placed in her hand, that is, by touch, through which she was able to correctly identify a pen, a stapler, a key, and a coin. Eye movement tests showed normal saccadic, smooth pursuit, convergence, and optokinetic eye movements with a conserved oculocephalic response; however, the patient showed marked optic ataxia in the finger-to-nose test.

A new MRI was ordered (Figure 2), showing marked parietal and occipital lobes atrophy with no other pathologic findings. With this clinical scenario PCA syndrome was diagnosed

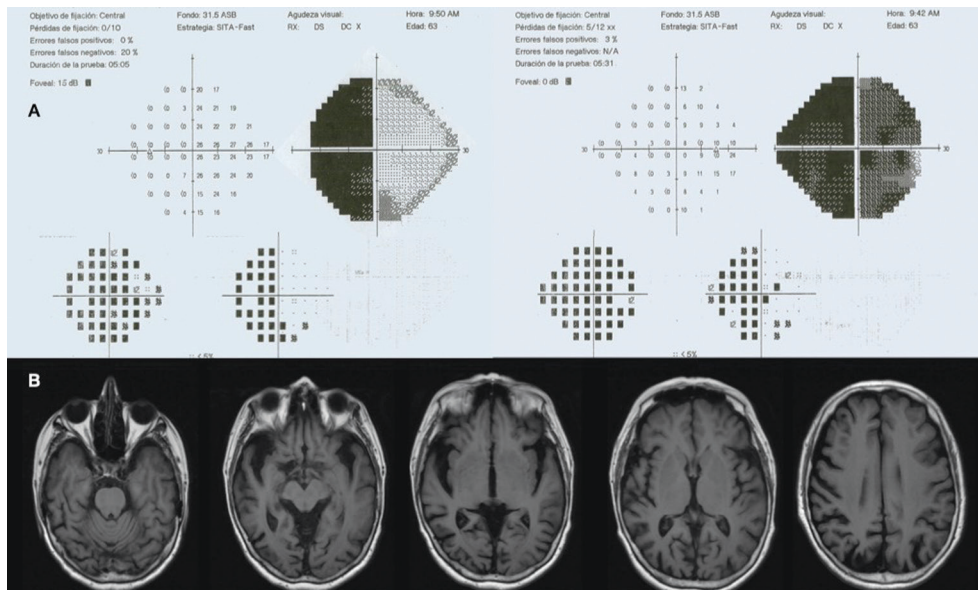


Figure 1 Patient's tests performed 4y prior A: First visual fields, this visual field was taken into consideration for the diagnosis of normal-tension glaucoma. Although not reliable, the pattern deviation map in the left eye clearly shows a temporal hemianopia, which appears to be homonymous when analyzing both eyes; B: First magnetic resonance imaging. No structural lesions were reported at the time, which could explain a possible homonymous hemianopia.

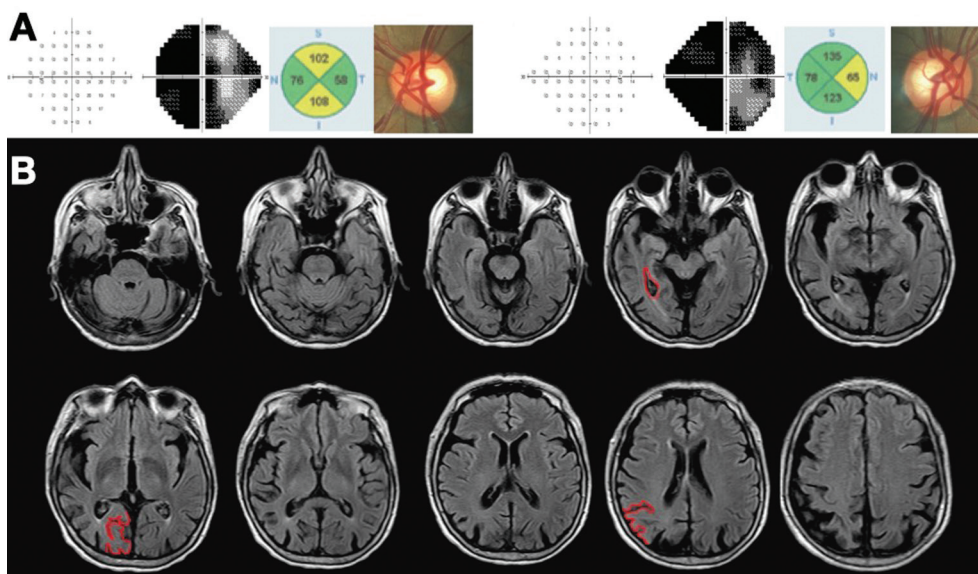


Figure 2 Patient's current tests A: Visual fields showing a left homonymous hemianopia, while the optic nerve resulted within normal limits measured with ocular coherence tomography: optic nerve photography is included on the right corner for each eye; B: Magnetic resonance imaging, showing marked atrophy on occipital lobes with no other pathologic findings, more prominent on the right side (marked in red). Also, lateral ventricular enlargement was noticed. With these findings, posterior cortical syndrome was diagnosed.

and the patient was evaluated in a cognitive impairment clinic, where Alzheimer's disease was the final diagnosis and rehabilitation treatment started, the glaucoma medication was discontinued once this diagnosis was made.

DISCUSSION

PCA is a widely under-recognized syndrome among visual health specialists; a prominent reason for this may be the lack of objective findings on routine examination and even on neuroimaging tests at initial phases^[1]. Its frequency is reported as high as 5%-14% of all of Alzheimer's cases^[2]; however,

it remains widely under-recognized due to scarce reports in visual-health related journals. This patient presented with most of the findings that can be red flags to consider the PCA syndrome. In this case report, an important distractor was a previous diagnosis of glaucoma in the setting of apparently normal neuroimaging findings.

Homonymous hemianopia in the setting of normal MRI has been previously described by Brazis *et al*^[3], who classified the main causes according to the form of onset of the visual field defect and its progression. Differential diagnoses include:

1) occipital hypoxia or ischemia, with hyper-acute onset; 2) non-ketotic hyperglycemia, with acute presentation; 3) Heidenhain variant of Creutzfeldt-Jakob disease, with subacute presentation; 4) degenerative diseases such as Alzheimer's disease, Lewy body disease, or Pick's disease, all of which have a chronic presentation^[3]. It is not surprising that some of these patients with a chronic condition or complaints, which show homonymous hemianopia on visual field testing but normal neuroimaging, are mistakenly treated as a non-organic condition^[3], thus delaying rehabilitation and prompt treatment of their disease.

Our patient was misdiagnosed with normal-tension glaucoma, although from the start there was clinical suspicion of a neurologic diagnosis, as an initial MRI was ordered. A few characteristics will correctly guide the diagnosis to a neurological-related loss of vision instead of glaucoma: first, a homonymous visual field defect that does not correlate with optic nerve head cupping^[4]. Second, the abnormal results in tests such as Ishihara test and the Boston Cookie Theft picture^[1]. Third, the marked reading impairment and the ability to recognize objects only with a stereotactic aid, all these despite normal BCVA.

The incorrect diagnosis of this neuro-ophthalmological condition led, in our patient, to unnecessary treatment with topical hypotensive drops^[5]. As we will describe, there are only subtle symptoms and signs that can point to the correct diagnosis of PCA on a routine ocular examination.

A comprehensive patient history focusing on a precise description of the patient's visual complaints is of utmost importance. Certain symptoms should be considered as red flags for this pathology from the beginning, like the one our patient presented: problems with reading, not associated with blurry, hazy or dimmed vision in the setting of a normal BCVA; this is alexia and has been reported as the most common sign in patients with PCA^[6]. Also, problems with finding certain objects, and getting lost when going outside, because of having trouble recognizing their own house^[1]. These are not the usual symptoms for an optometric or ophthalmologic consultation; rather, they all are specific to certain activities so they should be recognized as red flags and detailed when they arise in a consultation.

Once PCA is suspected, attention should be directed toward neurodegenerative diseases and higher visual functions must be examined. These functions include visual agnosia, ocular praxis, and visuospatial skills and should be explored as we will review next; in case they are altered, it strengthens the diagnostic suspicion^[7]. A discussion of the main clinical tests used to assess these deficits is included in Table 1.

Visual agnosia refers to a patient's inability to recognize what is visually presented to them. The specific clinical types of visual

agnosia are as follows: 1) Object agnosia is the lost capacity to describe an object in the field of vision, with no trouble identifying it by different means; 2) Simultanagnosia refers to the inability to integrate all the elements of a visual scene despite good visual acuity and being able to recognize each object on its own. The patient cannot grasp the meaning of a visual image as a whole. Instead, patients direct visual attention and keep gazing at specific parts of an image, perceiving them as separate; 3) Topographagnosia is the inability to visually recognize places, even a previously familiar one, such as their own house or workplace; 4) Prosopagnosia refers to the inability to visually recognize previously known faces; 5) Alexia without agraphia is the inability to recognize written text and one of the most prominent features of PCA^[1].

Apraxia is a movement disorder that prevents the patient from performing intentional acts, despite having an intact physical ability or will to do it. In patients with PCA acquired ocular motor apraxia is a notable finding^[1,8]. Among visuospatial skills, optic ataxia is a prominent clinical dysfunction present in PCA patients^[1] (Table 1).

Other examination findings in PCA patients include visual field defects, mainly homonymous defects are reported in 89% of patients with PCA and 62% are homonymous hemianopia. Unilateral, incomplete and bilateral defects have been described, thus PCA should be suspected in patients with homonymous visual field defects with apparently normal neuroimaging^[6].

The combination of simultanagnosia, acquired ocular motor apraxia and optic ataxia is known as Balint's syndrome, and is present when there is bilateral damage to parieto-occipital areas, or the so-called dorsal pathway^[8]. Incomplete Balint's syndrome is the most frequent finding in PCA^[2,9], as was the case in our patient, who presented with optic ataxia and simultanagnosia but not ocular motor apraxia. Apperceptive agnosia, such as alexia without agraphia, object agnosia and prosopagnosia are present with lesions of the occipitotemporal visual association areas or the ventral pathway^[1,9]

Other findings are less common in PCA, such as akinetopsia, visual hemineglect, hemi-achromatopsia, acalculia, agraphia, digit agnosia, and left-right disorientation^[1,8,10].

In 2017, Crutch *et al*^[11] proposed a new classification of PCA establishing a classification in three levels. Level 1, being PCA as the clinical, cognitive and neuroimaging definition (that brain atrophy is predominantly occipital, parietal and/or occipitotemporal) once any additional syndrome is excluded. Level 2 proposes PCA classification as PCA-pure or PCA-plus, taking into account whether there are features of neurodegenerative syndromes other than Alzheimer's. Finally Level 3 provides a definitive determination of the underlying cause of PCA, having pathological markers for one of the

Visual Alzheimer's: a diagnosis easily missed on examination

Table 1 Visual signs that may be present in PCA

| Clinical signs | Tests used to explore the deficit | Interpreting the test in the setting of suspected PCA |
|---|--|--|
| Bilateral temporal-occipital dysfunction | | |
| General visual agnosia | Visual object recognition, placing several objects in front of the patient and asking to name each of them | Patient won't be able to name the objects, although when feeling them the subject will show no difficulty in identifying the object |
| Cerebral achromatopsia | Farnsworth-Munsell D15 | Color vision test to screen for dyschromatopsia in PCA patients, as pseudoisochromatic plates results may be altered by the presence of simultanagnosia |
| Right temporal-occipital dysfunction | | |
| Prosopagnosia | Face recognition tests, Boston face recognition test | Can be tested using validated tests or, for screening purposes, the faces of famous people can be used, first ascertaining that they are people known to the subject |
| Topographagnosia | History of not recognizing own house or other familiar places | Patients can get lost when going outside due to difficulties in identifying the visual cues or specific patterns that normally make places visually recognizable. |
| Left temporal-occipital dysfunction | | |
| Alexia without agraphia | Reading texts, musical notation and numbers | This can be explored in the office by asking the patients to write a word or sentence down; further on in the interview, when asked to read it aloud, the subjects will not be able to read what they just wrote |
| Bilateral parietal-occipital dysfunction | | |
| Akinetopsia | Kinetic visual fields | Ideally explored with a formal kinetic perimetry test, may be screened by confrontational kinetic field testing |
| Simultanagnosia | Figures composed of smaller elements: pseudoisochromatic plates, Navon letters, Arcimboldo paintings Describing an image: Boston cookie-theft, Poppelreuter-Ghent | Patients with PCA will not be able to correctly identify the figures or bigger elements on these tests or will partially describe the image. Pseudoisochromatic plates can be used as a screening test for simultanagnosia. In PCA, the inability to correctly identify the numbers, including the control plate, is a sign of simultanagnosia rather than being representative of dyschromatopsia |
| Optic ataxia | Finger-to-nose test | In PCA patients there will neither be tremor (seen in cerebellar disease) nor lateropulsion (seen in vestibular disease), and there is no difficulty for the patient to reach their own nose; however, when they attempt to touch the finger of the examiner, the patients misplace their finger, with either hand, and in any direction even when looking directly at the examiner's finger. |
| Acquired ocular motor apraxia | Saccadic eye movements - tested by telling the patient to quickly change their gaze from one object to another, both horizontally and vertically | First observed as a delay in voluntary saccade initiation, or latency. However, in advanced cases precision and speed can be altered or there can be a complete absence of volitional saccades. Sparing reflex saccades and other types of conjugate eye movements, such as slow-pursuit, optokinetic, oculocephalic and convergence. |

PCA: Posterior cortical atrophy.

following conditions: Alzheimer's, prion disease, corticobasal degeneration, Lewy body disease *etc*^[11]. This classification permits to establish clinical diagnosis of the syndrome and to characterize the heterogeneity of PCA. Our patient had core features of PCA (Level 1) such as insidious onset, gradual progression and prominent early visual disturbances, as well as all the cognitive symptoms described in the clinical case (apraxia, visual agnosia, *etc.*) and some other neurological and medical causes were excluded. Final diagnosis was PCA-pure (Level 2) because no *in vivo* evidence of Alzheimer's was obtained, such as cerebrospinal fluid or positron emission tomography (PET) biomarkers due to the socioeconomic context of the patient and the lack of social security. The work-up fulfilled the criteria of the Alzheimer's International Working Group^[11] and pointed to PCA associated with Alzheimer's disease. Importantly, unlike typical Alzheimer's disease, patients with PCA have relatively preserved episodic memory at baseline; and unlike frontotemporal dementia, behavior, personality and the capacity for introspection are preserved^[2]. Regarding the management of PCA, it is similar to that of typical Alzheimer's disease, but takes into account the visual problems^[2]. A multidisciplinary approach with ophthalmology, low vision specialists, neurology, geriatrics, social workers and spatial and visual rehabilitation must be carried out. As

well as establishing an action plan with the family from the early stages due to the progressive nature of the condition^[12]. It is important to provide the patient with early access to information so that both the patient and family members are aware of the situation and its limitations, for example, patients with PCA are not fit to drive vehicles and it is important to establish that from the beginning^[12]. Current therapeutic options are scant as they are based on small studies or expert opinion. Cholinesterase inhibitors, N-methyl-D-aspartate (NMDA) receptor antagonists, or anti-amyloid monoclonal antibodies have been suggested, however, disease-modifying treatments are not yet available^[13-14]. As we have described, PCA has subtle ophthalmological findings, commonly having an entirely normal routine ocular examination. This is the reason why the attending physician must heed the symptomatology of the patient cautiously, thus being able to identify the red flags and then intentionally search for these subtle findings during the examination, such as some slight alteration of saccadic movements or problems when reading words instead of single optotypes^[1]. They must also methodically examine what was previously addressed. In conclusion, higher visual function findings, altered in the PCA syndrome, can be easily tested at the office or bedside, as described. Once the diagnosis of PCA is suspected, searching

for suggestive examination signs is straightforward, and more importantly, it can spare the patient more exhaustive and often unneeded testing or treatment before reaching the correct diagnosis.

ACKNOWLEDGEMENTS

We thank Dr. Cindy Haro-Zuno for referring the patient to us.

Conflicts of Interest: Cárdenas-Belaunzarán J, None; Wheelock-Gutierrez L, None; Cerrillo-Avila KA, None.

REFERENCES

- Beh SC, Muthusamy B, Calabresi P, Hart J, Zee D, Patel V, Frohman E. Hiding in plain sight: a closer look at posterior cortical atrophy. *Pract Neurol* 2015;15(1):5-13.
- Schott JM, Crutch SJ. Posterior Cortical Atrophy. *Continuum (Minneapolis)* 2019;25(1):52-75.
- Brazis PW, Lee AG, Graff-Radford N, Desai NP, Eggenberger ER. Homonymous visual field defects in patients without corresponding structural lesions on neuroimaging. *J Neuroophthalmol* 2000;20(2):92-96.
- Gupta PK, Asrani S, Freedman SF, El-Dairi M, Bhatti MT. Differentiating glaucomatous from non-glaucomatous optic nerve cupping by optical coherence tomography. *Open Neurol J* 2011;5:1-7.
- Dias DT, Ushida M, Battistella R, Dorairaj S, Prata TS. Neurophthalmological conditions mimicking glaucomatous optic neuropathy: analysis of the most common causes of misdiagnosis. *BMC Ophthalmol* 2017;17(1):2.
- Olds JJ, Hills WL, Warner J, et al. Posterior cortical atrophy: characteristics from a clinical data registry. *Front Neurol* 2020;11:358.
- Pelak VS, Tang-Wai DF, Boeve BF, et al. Consensus recommendations for clinical assessment tools for the diagnosis of posterior cortical atrophy syndrome from the Atypical AD PIA of ISTAART. *Alzheimer's Dement* 2023;15(3):e12474.
- Shakespeare TJ, Kaski D, Yong KX, Paterson RW, Slattery CF, Ryan NS, Schott JM, Crutch SJ. Abnormalities of fixation, saccade and pursuit in posterior cortical atrophy. *Brain* 2015;138(Pt 7):1976-1991.
- Pellegrini F, Lee AG, Zucchetta P. Homonymous Hemianopsia due to posterior cortical atrophy. *Neuroophthalmology* 2017;41(3):154-158.
- Cárdenas-Belaunzarán J, Cerrillo-Avila KA. Visual agnosia mimicking memory impairment: a case report of posterior cortical atrophy. *Neuroophthalmology* 2024;48(1):30-36.
- Crutch SJ, Schott JM, Rabinovici GD, et al. Consensus classification of posterior cortical atrophy. *Alzheimer's Dement* 2017;13(8):870-884.
- Yong KXX, Graff-Radford J, Ahmed S, Chapleau M, Ossenkoppele R, Putcha D, Rabinovici GD, Suarez-Gonzalez A, Schott JM, Crutch S, Harding E. Diagnosis and management of posterior cortical atrophy. *Curr Treat Options Neurol* 2023;25(2):23-43.
- Chapleau M, La Joie R, Yong K, et al. Demographic, clinical, biomarker, and neuropathological correlates of posterior cortical atrophy: an international cohort study and individual participant data meta-analysis. *Lancet Neurol* 2024;23(2):168-177.
- Bejanin A, Villain N. Posterior cortical atrophy: new insights into treatments and biomarkers for Alzheimer's disease. *Lancet Neurol* 2024;23(2):127-128.