

# Nasal flap preservation in endoscopic dacryocystorhinostomy for nasolacrimal duct obstruction

Marianne Romanos<sup>1,2</sup>, Charbel Medawar<sup>1,2</sup>, Souheil Hallit<sup>1,3</sup>, Bassam Romanos<sup>1,2</sup>

<sup>1</sup>School of Medicine and Medical Sciences, Holy Spirit University of Kaslik, P.O. Box 446, Jounieh, Lebanon

<sup>2</sup>Department of Ophthalmology, Eye and Ear Hospital International, Naccache, Lebanon

<sup>3</sup>Applied Science Research Center, Applied Science Private University, Amman 11937, Jordan

**Correspondence to:** Souheil Hallit and Marianne Romanos. School of Medicine and Medical Sciences, Holy Spirit University of Kaslik, P.O. Box 446, Jounieh, Lebanon. souheilhallit@hotmail.com; marianneromanos@hotmail.com

Received: 2023-07-12 Accepted: 2024-05-24

## Abstract

• **AIM:** To compare surgical outcomes between the conventional endoscopic dacryocystorhinostomy (DCR) and a modified endoscopic DCR for the treatment of nasolacrimal duct obstruction (NLDO), and evaluate factors associated with the surgical success rate.

• **METHODS:** Medical records of patients who underwent primary DCR surgery between January 2016 and July 2020 at the Otorhinolaryngology Department of Eye and Ear International Hospital, Lebanon were reviewed.

• **RESULTS:** The study group consisted of 50 consecutive modified endoscopic DCR and the control group consisted of 138 consecutive conventional endoscopic DCR. The success rates at 1y were 98.0% (49 out of 50) for modified DCR, significantly higher compared to 84.8% (117/138) for the conventional DCR; there was no significant difference in the success rate throughout the years in terms of both surgical techniques. The modified surgery vs traditional [adjusted odds ratio (aOR)=14.96] and having an adjunctive septoplasty surgery vs not (aOR=3.99) were significantly associated with higher odds of success.

• **CONCLUSION:** Mucosal flap preservation and apposition shows significant improvement in the surgical success rate. Moreover, there is no statistically significant difference found in terms of complication rate and mean operative time between the conventional and the modified techniques.

• **KEYWORDS:** nasolacrimal duct obstruction; endoscopic dacryocystorhinostomy; mucosal flap

DOI:10.18240/ijo.2024.09.09

**Citation:** Romanos M, Medawar C, Hallit S, Romanos B. Nasal flap preservation in endoscopic dacryocystorhinostomy for nasolacrimal duct obstruction. *Int J Ophthalmol* 2024;17(9):1633-1638

## INTRODUCTION

Dacryocystorhinostomy (DCR) is the gold standard procedure performed to reestablish a normal lacrimal flow in the setting of nasolacrimal duct obstruction (NLDO). It consists of bypassing the obstruction, usually distally located in the nasolacrimal duct, by creating a fistula between the lacrimal sac and the nasal cavity. This fistula can be performed through either an external or an endonasal approach. The Caldwell-Luc operation was the first to introduce the endonasal approach in 1893. However, the instrumental limitations and difficulties in visualization at that time made the external approach the technique of choice given its finer success rate. In the last 3 decades, advancements in nasal endoscopy and anatomy knowledge facilitated the manipulation in the nasal cavity and thus endoscopic DCR became common.

Deviated septum, concha bullosa, and nasal polyps were shown to be risk factors for unsuccessful DCR<sup>[1]</sup>. Moreover, fibrosis at the level of anastomosis is the main cause of endoscopic DCR failure. In addition, a wide exposure of the lacrimal sac and a complete marsupialization of the latter are key factors to a successful endoscopic DCR<sup>[2]</sup>. In recent years, studies have aimed to improve the outcome by decreasing the granulation tissue formation, to maintain the patency of the rhinostomy suggesting the coverage of bare bone which can promote healing by primary intention and curtail the granulation tissue formation, improving success rates<sup>[3-5]</sup>. However, the results are still controversies<sup>[4-6]</sup>.

Accordingly, we conducted a study to compare surgical outcomes of endoscopic DCR removing the nasal mucosal flap and a modified endoscopic DCR with total preservation of the flap.

The aims of this study were to compare surgical outcomes between the conventional endoscopic DCR and a modified endoscopic DCR for the treatment of NLDO, and evaluate factors associated with the surgical success rate.

## SUBJECTS AND METHODS

**Ethical Approval** Ethical clearance was obtained by the research Ethics Committee of the Eye and Ear International Hospital, Lebanon. The study was conducted in accordance with the principles of the Declaration of Helsinki. The informed consent was obtained from the subjects.

**Study Design** We conducted a case-control study, investigating 188 DCRs performed from January 2016 till July 2020, for 181 patients of whom 8 underwent the procedure bilaterally. The control group consisted of 138 consecutive conventional endoscopic DCR with complete mucosal flap resection, performed on 134 patients from January 2016 to June 2019 (42mo). The study group consisted of 50 consecutive modified endoscopic DCR with apposition of the preserved mucosal flap over the rhinostomy, performed on 47 patients from June 2019 to July 2020 (14mo). Patients were assigned to either group according to the date of surgery by following a chronological sequence: the transition from the conventional technique to the modified technique in DCR practice of the surgeon took place in June 2019. All case notes included in our study documented comprehensive preoperative assessment, surgical details, and a minimum follow-up period of 1y focusing on the reemergence of symptoms and irrigation of the nasolacrimal drainage system. Anatomic patency of the rhinostomy on endoscopic visualization was evaluated for patients with persistence or reemergence of symptoms or signs of NLDO in the post-operative period. We were able to have two groups with no significant disparity with regards to demographic characteristics except for the average age. All surgeries were performed by the same ear, nose and throat (ENT) surgeon. The pre-operative assessment included a detailed ophthalmic examination including lacrimal probing and syringing of the nasolacrimal drainage system, and a complete intranasal endoscopic examination by an otolaryngologist. For both groups, additional nasal surgeries, like septoplasty, functional endoscopic sinus surgery (FESS), turbinectomy, and polypectomy were planned along. Peroperatively, removed tissues were collected for histopathologic studies in all patients. Further para-clinical imaging was not routinely indicated and hence only performed when secondary NLDO is suspected. All patients included in our study were diagnosed as having NLDO. Patients presenting eyelid pathologies, facial palsy, and history of facial trauma were excluded. As well, we excluded patients with a history of previous DCR to the same eye. Medical records were reviewed and the data collected included the patient demographics, preoperative assessment, surgical details, and postoperative follow-up results. Anatomical patency does not always guarantee symptomatic relief. Since patient comfort is the cardinal purpose of the procedure, surgical success was

defined as complete resolution of NLDO symptoms 1y after surgery. Any new episode of dacryocystitis or reoccurrence of epiphora during the follow-up period correlates to failure of the procedure. Postoperative follow-ups were scheduled at 1wk, 1, 3mo, and 1y. The patient demographics were summarized in Table 1.

**Surgical Technique** All procedures were done under general anesthesia and using a 0-degree rigid endoscope.

The nasal cavity was packed with cotton pledgets soaked in oxymetazoline hydrochloride 0.05%, followed by submucosal injection of lidocaine 2% and epinephrine 1/100 000 at the level of the middle turbinate head, axillae, and over the predetermined rhinostomy site. This promotes vasoconstriction and decongestion of the nasal mucosa permitting optimal visualization and minimizing bleeding.

We started by identifying our landmarks: the insertion of the middle turbinate, the maxillary line and the uncinat process.

Using a 15 scalpel blade, the incision of our flap began 5 mm above the root of the middle turbinate and went down to the top of the inferior turbinate insertion. A parallel incision was made 8 mm distal from the first incision. A 15 mm length ×8 mm width U-shaped flap was elevated having a unique attachment upwards, toward the insertion of the middle turbinate. The flap was folded superiorly, and the thin lacrimal bone and thick frontal process of the maxilla, separated by the lacrimal suture line, were therefore exposed.

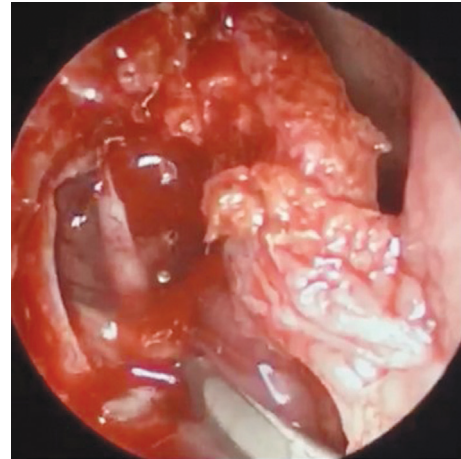
Measures in length, width and subsequent surface of the rhinostomy were invariable between the two groups. The only variation in the surgical technique between the control and study groups was related to the preservation of the nasal mucosal flap.

In the control group, the nasal flap was than excised completely, in contrary to the study group where the U-shaped flap was entirely preserved for the subsequent coverage of the rhinostomy site in the later phase. Using a Kerrison bone rongeur, we removed the exposed bone covering the lacrimal sac. When rich pneumatization of agger nasi was present, anterior ethmoidectomy was done for better exposure of the lacrimal sac. A large rhinostomy of 15 mm in vertical length was fashioned to expose the lacrimal sac from fundus to sac-duct junction. Using a Beaver cataract knife, we made a vertical long incision of the sac from the fundus down to the nasolacrimal duct, followed by horizontal incisions at the top and bottom forming an "I" shape (Figure 1). A thorough lavage followed by a complete marsupialization of the sac was made. Subsequently, in both groups and in all patients, a silicone tube was inserted through the upper and lower puncta down in the nasolacrimal duct and grasped with a Blakesley forceps. At the opening of the common canaliculus at the lacrimal sac, the tubes were tied together with clips and trimmed afterward.

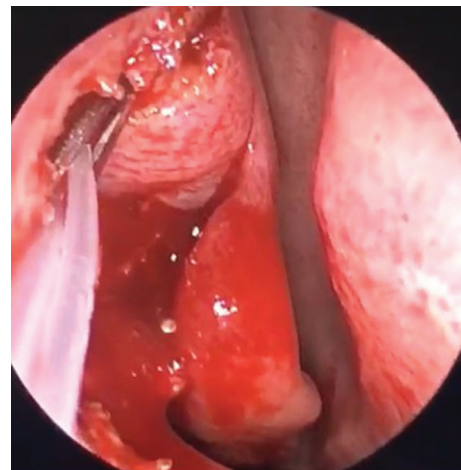
**Table 1 Comparison between the conventional and modified endoscopic DCR**

Variables	Conventional endoscopic DCR (n=138)	Modified endoscopic DCR (n=50)	<i>n</i> (%)
Gender			0.990
Male	33 (23.9)	12 (24.0)	
Female	105 (76.1)	38 (76.0)	
Laterality			0.251
Right	54 (39.1)	15 (30.0)	
Left	84 (60.9)	35 (70.0)	
Smoking			0.466
No	83 (60.1)	33 (66.0)	
Yes	55 (39.9)	17 (34.0)	
Hypertension			0.580
No	114 (82.6)	43 (86.0)	
Yes	24 (17.4)	7 (14.0)	
Diabetes mellitus			0.574
No	120 (87.0)	45 (90.0)	
Yes	18 (13.0)	5 (10.0)	
Allergic rhinitis/asthma			0.797
No	108 (78.3)	40 (80.0)	
Yes	30 (21.7)	10 (20.0)	
Chronic sinusitis			0.968
No	119 (86.2)	43 (86.0)	
Yes	19 (13.8)	7 (14.0)	
Ocular history			0.555
No	96 (69.6)	37 (74.0)	
Yes	42 (30.4)	13 (26.0)	
History of rhinoplasty or sinus surgery			1
No	125 (90.6)	45 (90.0)	
Yes	13 (9.4)	5 (10.0)	
History of chemotherapy intake			1
No	134 (97.1)	49 (98.0)	
Yes	4 (2.9)	1 (2.0)	
Adjunctive FESS			0.715
No	124 (89.9)	44 (88.0)	
Yes	14 (10.1)	6 (12.0)	
Adjunctive septoplasty			0.926
No	79 (57.2)	29 (58.0)	
Yes	59 (42.8)	21 (42.0)	
Adjunctive ethmoidectomy			0.730
No	129 (93.5)	48 (96.0)	
Yes	9 (6.5)	2 (4.0)	
Adjunctive turbinectomy			1
No	129 (93.5)	47 (94.0)	
Yes	9 (6.5)	3 (6.0)	
Postop. epistaxis			0.704
No	134 (97.10)	48 (96.0)	
Yes	4 (2.90)	2 (4.0)	
Others (+)			0.342
No	120 (87.0)	46 (92.0)	
Yes	18 (13.0)	4 (8.0)	
Success			0.013 <sup>a</sup>
No	21 (15.2)	1 (2.0)	
Yes	117 (84.8)	49 (98.0)	
Age (y)	59.98±10.52	56.28±9.04	0.012 <sup>a</sup>

<sup>a</sup>*P*<0.05. DCR: Dacryocystorhinostomy; FESS: Functional endoscopic sinus surgery.



**Figure 1** Partially exposed lacrimal sac lumen with U-shaped mucosal flap superiorly attached to the lateral nasal wall.



**Figure 2** Mucosal flap drawn into the rhinostomy site with emerging silicone tube.

Irrigation with saline fluid was done to verify the patency of the common internal punctum.

Finally, in the study group, we reinserted the U-shaped mucosal flap inside the nasolacrimal sac ostium and packed the cavity with Gelfoam soaked in methylprednisolone to stabilize and assure stabilization of the flap apposition (Figure 2).

Post-operatively, patients were instructed to rinse their nose with saline spray three to four times daily for 10d and to use eye drops containing a combination of low dosage steroids and antibiotics every 8h for 6wk. Moreover, the patient is directed to avoid nose blowing and sneezing without the mouth open for 10d in order to avoid subcutaneous emphysema.

**Statistical Analysis** SPSS v.25 was used for all statistical analysis. The Chi-square test was used to compare categorical variables between both types of surgery, whereas the Student's *t*-test was used to compare two means. A logistic regression was conducted taking the success rate (yes/no) as the dependent variable. *P*<0.05 was deemed statistically significant.

## RESULTS

The study group consisted of 50 consecutive modified endoscopic DCR and the control group consisted of 138 consecutive

**Table 2 Comparison of the success rate throughout the years**

Year of surgery	Conventional endoscopic DCR (n=138)		P	Modified endoscopic DCR (n=50)		P	n (%)
	Non-success	Success		Non-success	Success		
	2016	6 (14.6)		35 (85.4)	0.957		
2017	5 (13.2)	33 (86.8)		-	-		
2018	6 (16.2)	31 (83.8)		-	-		
2019	4 (18.2)	18 (81.8)		0	26 (100)		
2020	-	-		1 (4.2)	23 (95.8)		

DCR: Dacryocystorhinostomy.

conventional endoscopic DCR. Surgical outcomes were evaluated and compared between the 2 groups with regards to success rates, complications, and mean operative time.

There was no statistically significant difference between the groups with regards to demographic characteristics except for the average age. The diagnosis of NLDO was confirmed based on the history of the patient and clinical investigation. Epiphora was the most experienced symptom and observed in all our patients in both groups. Acute or chronic dacryocystitis was confirmed clinically in 25 out of 138 (18.12%) lacrimal vies in the control group and 10 out of 50 (20%) in the study group.

We used a bicanalicular stent in all our patients with a median time for stent placement of 6.5wk for the study group and 6.8wk for the control group.

The success rate at 1y was 98.0% (49/50) for modified DCR significantly higher compared to 84.8% (117/138) for the conventional DCR. The mean operative duration was 45min for modified DCR and 40min for conventional DCR. There were no major complications encountered during the procedure or in the follow-up period in both groups. Minor complication rates were low in both groups, as 6 presented postoperative epistaxis which responded to conservative treatment: 2 in the study group and 4 in the control group, with no significant statistical difference between them.

To achieve optimal endonasal visualization and manipulation, additional procedures were required in 81 patients in the control group (58.7%) and 29 patients in the study group (58.0%). In the control group, septoplasty was required in 59 patients (42.8%), sinus surgery in 23 patients (16.6%) and other additional endonasal procedures for middle turbinate and nasal polyposis were performed in 27 patients (19.5%). In the study group, septoplasty was required in 21 patients (42.0%), sinus surgery in 8 patients (16.0%), and 7 patients underwent other concomitant endonasal procedures for middle turbinate and nasal polyposis (14.0%).

During the 1y follow-up period, endoscopic investigation was done in all the 22 failed cases and showed closure of the rhinostomy site due to granulation tissue formation.

Histopathologic analysis of the resected lacrimal sac tissue

during the procedure did not show any specific findings in all patients for both groups except for the failed case of the study group in which non-caseating granulomatous inflammation was documented and the patient was later diagnosed as having sarcoidosis.

The period to observe the failure was 2.73mo (range 2–4mo) for the control group and 2.9mo (range 2–4mo) for the study group.

**Comparison Between Conventional and Modified Endoscopic DCR**

A significantly higher percentage of success was seen among patients who underwent modified endoscopic DCR compared to the conventional method (98.0% vs 84.8%;  $P=0.013$ ). Moreover, a significantly lower mean age was found in those who underwent modified endoscopic DCR compared to the conventional method (56.28 vs 59.98;  $P=0.012$ ; Table 1). There was no significant difference in the success rate throughout the years in terms of both surgical techniques as shown in Table 2.

**Multivariable Analysis** The modified surgery vs traditional [adjusted odds ratio (aOR)=14.96] and having an adjunctive septoplasty surgery vs not (aOR=3.99) were significantly associated with higher odds of success (Table 3).

**DISCUSSION**

In the present study, the surgical success rate for the conventional DCR was 84.8%, whereas, for the modified DCR, it was 98.0%, showing that mucosal flap preservation and apposition improve significantly the outcomes. Moreover, there were no statistically significant differences found in terms of complication rate and mean operative time between the conventional and the modified techniques. The overall postoperative epistaxis rate in our study of 3.19% is acceptable when compared to the incidence of epistaxis after endoscopic DCR in literature<sup>[7-8]</sup>.

Many publications aimed to study the effectiveness of preserving the mucosal flap and the results were controversial, with the possibility of 91.3% of success after primary DCR, and 95.65% after revision surgery<sup>[4]</sup> with preservation of the mucosal flap or 81% with conventional endoscopic DCR versus 95.1% with endoscopic DCR preserving of the mucosal flap<sup>[5]</sup>. Another study showed an anatomical success rate of



**Table 3 Logistic regression taking the success rate (yes/no) as the dependent variable**

Variables	P	aOR	95%CI
Surgery type (modified vs traditional DCR)	0.015 <sup>a</sup>	14.96	1.71; 131.13
Age	0.459	0.98	0.93; 1.04
Sex (female vs male)	0.065	0.20	0.04; 1.10
Laterality (left vs right)	0.369	0.60	0.20; 1.82
Smoking (yes vs no)	0.589	1.35	0.46; 3.97
Hypertension (yes vs no)	0.856	1.15	0.26; 5.05
Diabetes mellitus (yes vs no)	0.073	0.30	0.08; 1.12
Allergic rhinitis/asthma (yes vs no)	0.714	0.79	0.22; 2.82
Chronic sinusitis (yes vs no)	0.156	4.75	0.55; 40.75
History of ocular problems (yes vs no)	0.493	1.57	0.43; 5.68
History of rhinoplasty (yes vs no)	0.482	0.53	0.09; 3.09
Previous chemotherapy intake (yes vs no)	0.545	0.45	0.04; 5.89
Adjunctive septoplasty (yes vs no)	0.031 <sup>a</sup>	3.99	1.13; 14.06
Adjunctive ethmoidectomy (yes vs no)	0.583	1.89	0.20; 18.13
Adjunctive turbinectomy (yes vs no)	0.094	0.23	0.04; 1.28

<sup>a</sup>P<0.05. aOR: Adjusted odds ratio; DCR: Dacryocystorhinostomy.

97%, and symptom relief in 91% of the cases with preservation of the mucosal flap in endoscopic DCR<sup>[3]</sup>.

The reason for achieving higher success rates can be the lesser granulation tissue formation since bar bone can have increased granulation tissue<sup>[3-5]</sup>. Therefore, the coverage of bare bone promotes healing by primary intention and curtails the granulation tissue formation.

In our study, postoperative endoscopic investigation for the 22 failed DCR cases showed closure of the rhinostomy site due to granulation tissue formation. Concerning the failed case in the study group, the histopathologic analysis of the resected lacrimal sac tissue during the procedure showed non-caseating granulomatous inflammation and the patient was later diagnosed as having sarcoidosis.

In our study, the discrepancy in the mean age at presentation between the study and control groups was found to be significant. Although some studies suggest that age can be a prognostic factor for surgical success of DCR<sup>[9]</sup>, others reached controversial results<sup>[10-11]</sup>. In our study, comparison in terms of age-adjusted surgical success between the two groups, showed a statistically significant increase of the surgical success in the study group. Therefore, we do not consider the age variability between the control and study groups a major limitation in our study.

Many studies reported the advantage of endoscopic approaches in the recognition and correction of intra-nasal abnormalities for higher success rates<sup>[1,12]</sup>. In our study, the rate of adjunctive intra-nasal procedures was comparable to some others reported in the literature<sup>[8,13]</sup>, and higher relatively to some others<sup>[14]</sup>. Septoplasty facilitated the creation of the large rhinostomy

and the mucosal flap apposition for higher success rates<sup>[15]</sup>. In one study, the results showed the importance of middle turbinectomy in providing better exposure of the lateral nasal wall and in decreasing the risk of postoperative adhesions<sup>[16]</sup>. Turbinectomy was performed in our patients when the evaluated risk of scarring in the region of the neo-ostium was eminent. In our study, the percentage of additional procedures was comparable in both groups and this is why we do not consider it as a confounding factor for the study.

Knowledge of the intra-nasal anatomy is crucial, not only for surgical success, but also for the prevention of intra-operative complications<sup>[17-18]</sup>. Practical experience was proved to be an essential characteristic of the surgeon, improving significantly the outcomes, in terms of success rate and postoperative complications. Inadequate sac marsupialization, inaccurate localization of the sac, and small osteotomies are correlated with failure of the procedure<sup>[2]</sup>. In a prospective study, comparison was done between the results of DCR carried out by experienced surgeons and DCR operated by inexperienced surgeons. The success rates were respectively 94.4% and 58%. The main cause of failure in the inexperienced group was attributed to the improper localization of the lacrimal sac<sup>[19]</sup>.

In our study, all cases were operated by the same surgeon who has 25y of experience in endoscopic DCR. Moreover, results of studies comparing surgical techniques performed by the same surgeon have higher statistical significance since we are reducing variability between the control and the study groups, thus, reducing bias.

Drawbacks of endoscopic DCR are steep learning curve of the intra-nasal anatomy and technical manipulation, and more expensive instrumentation<sup>[20]</sup>. In our study, the learning curve was not a major concern in both groups and did not influence results in consideration of the level of experience the surgeon had in the studied interval, the analogy between the conventional and modified techniques, and the sustainable success rate over years during the study period for both techniques. The procedure length varies according to the approach followed by the surgeon, his or her skills, and practical experience.

This study has several limitations including its retrospective nature and the difference in the studied period between the control and study groups. The average age discrepancy between the two groups, although significant, lacks of evidence relating age to the surgical success. The follow-up period in our study was one-year. Furthermore, majority of case failure occur in the following two to three postoperative months, although, the risk of surgical failure is still present in the following period. Longer follow-up period would have helped better judge the relation between rhinostomy coverage with mucosal flap and surgical success rate.

The strength of this study was the surgical procedures performed by an experienced surgeon following a consistent management, thus avoiding potential confounding variables. We can not deny, that the experience the surgeon has already gained in the study interval, may explain the high success rate in both techniques that differ in only one surgical step. Yet, even though practice of conventional DCR has a clear impact on the success rate of the modified technique, the difference in success rate between the 2 techniques is statistically significant and experience is obviously not the main factor for the higher success rate in the study group since the cases of modified DCR were all done in a relatively short period after the immediate transition done by the surgeon.

In conclusion, our results suggest that endoscopic DCR with preservation of the mucosal flap provides higher success rates at 1y and low complications risk. The knowledge of the nasal anatomy, surgical competency, and rhinostomy with mucosal flap apposition are crucial considerations for successful endoscopic DCR for the treatment of NLDO.

#### ACKNOWLEDGEMENTS

**Authors' contributions:** Romanos M drafted the manuscript; Romanos B designed the study; Hallit S carried out the analysis and interpreted the results; Romanos M and Medawar C involved in the data collection; all authors read and approved the final manuscript; Romanos B was the project supervisor.

**Conflicts of Interest:** Romanos M, None; Medawar C, None; Hallit S, None; Romanos B, None.

#### REFERENCES

- 1 Fayet B, Katowitz WR, Racy E, Ruban JM, Katowitz JA. Endoscopic dacryocystorhinostomy: the keys to surgical success. *Ophthalmic Plast Reconstr Surg* 2014;30(1):69-71.
- 2 Dave TV, Ali Mohammed F, Ali MJ, Naik MN. Etiologic analysis of 100 anatomically failed dacryocystorhinostomies. *Clin Ophthalmol* 2016;10:1419-1422.
- 3 Wormald PJ, Tsirbas A. Investigation and endoscopic treatment for functional and anatomical obstruction of the nasolacrimal duct system. *Clin Otolaryngol Allied Sci* 2004;29(4):352-356.
- 4 Trimarchi M, Resti AG, Bellini C, Forti M, Bussi M. Anastomosis of nasal mucosal and lacrimal sac flaps in endoscopic dacryocystorhinostomy. *Eur Arch Otorhinolaryngol* 2009;266(11): 1747-1752.
- 5 Vatansever M, Dursun Ö. Endoscopic dacryocystorhinostomy with modified mucosal flap technique. *J Craniofac Surg* 2023;34(3): e216-e218.

- 6 Kingdom TT, Barham HP, Durairaj VD. Long-term outcomes after endoscopic dacryocystorhinostomy without mucosal flap preservation. *Laryngoscope* 2020;130(1):12-17.
- 7 Horn IS, Tittmann M, Fischer M, Otto M, Dietz A, Mozet C. Endonasal nasolacrimal duct surgery: a comparative study of two techniques. *Eur Arch Oto Rhino Laryngol* 2014;271(7):1923-1931.
- 8 Tsirbas A, Wormald PJ. Mechanical endonasal dacryocystorhinostomy with mucosal flaps. *Br J Ophthalmol* 2003;87(1):43-47.
- 9 Sung JY, Lee YH, Kim KN, Kang TS, Lee SB. Surgical outcomes of endoscopic dacryocystorhinostomy: analysis of age effect. *Sci Rep* 2019;9(1):19861.
- 10 Zenk J, Karatzanis AD, Psychogios G, Franzke K, Koch M, Hornung J, Velegrakis GA, Iro H. Long-term results of endonasal dacryocystorhinostomy. *Eur Arch Otorhinolaryngol* 2009;266(11): 1733-1738.
- 11 Dolmetsch AM. Nonlaser endoscopic endonasal dacryocystorhinostomy with adjunctive mitomycin C in nasolacrimal duct obstruction in adults. *Ophthalmology* 2010;117(5):1037-1040.
- 12 Nussbaumer M, Schreiber S, Yung MW. Concomitant nasal procedures in endoscopic dacryocystorhinostomy. *J Laryngol Otol* 2004;118(4):267-269.
- 13 Ali MJ, Psaltis AJ, Murphy J, Wormald PJ. Powered endoscopic dacryocystorhinostomy: a decade of experience. *Ophthalmic Plast Reconstr Surg* 2015;31(3):219-221.
- 14 Figueira E, Al Abbadi Z, Malhotra R, Wilcsek G, Selva D. Frequency of simultaneous nasal procedures in endoscopic dacryocystorhinostomy. *Ophthalmic Plast Reconstr Surg* 2014;30(1): 40-43.
- 15 Karpishchenko SA, Vereshchagina OE, Karpov AA. Endoscopic septoplasty as a stage of endonasal dacryocystorhinostomy. *Vestn Otorinolaringol* 2020;85(6):56-59.
- 16 Metson R. Endoscopic surgery for lacrimal obstruction. *Otolaryngol Head Neck Surg* 1991;104(4):473-479.
- 17 Rajak SN, Psaltis AJ. Anatomical considerations in endoscopic lacrimal surgery. *Ann Anat* 2019;224:28-32.
- 18 Erdem RO, Dundar MA, Arbag S, Arbag H, Seker M. Endoscopic anatomy of the lacrimal sac: a cadaveric study. *Acta Med Acad* 2022;51(3):175-180.
- 19 Onerci M, Orhan M, Ogretmenoğlu O, Irkeç M. Long-term results and reasons for failure of intranasal endoscopic dacryocystorhinostomy. *Acta Otolaryngol* 2000;120(2):319-322.
- 20 Jawaheer L, MacEwen CJ, Anijeet D. Endonasal versus external dacryocystorhinostomy for nasolacrimal duct obstruction. *Cochrane Database Syst Rev* 2017;2(2):CD007097.