

Dacryocystitis and canaliculitis secondary to residual of epidural catheter remaining in lacrimal duct for 25 years: a case report and literature review

Bing-Ran Dong¹, Ming-Hai Chen^{1,2}, Peng Wang¹, Hai Tao^{1,2}

¹Senior Department of Ophthalmology, the Third Medical Center, Chinese PLA General Hospital, Beijing 100039, China

²The Fifth Clinical College of Anhui Medical University, Hefei 230032, Anhui Province, China

Co-first authors: Bing-Ran Dong and Ming-Hai Chen

Correspondence to: Hai Tao. Senior Department of Ophthalmology, the Third Medical Center, Chinese PLA General Hospital, Yongding Road 69, Haidian District, Beijing 100039, China. taohaiwj@sina.com

Received: 2024-04-01 Accepted: 2024-08-05

DOI:10.18240/ijo.2024.12.24

Citation: Dong BR, Chen MH, Wang P, Tao H. Dacryocystitis and canaliculitis secondary to residual of epidural catheter remaining in lacrimal duct for 25 years: a case report and literature review. *Int J Ophthalmol* 2024;17(12):2333-2335

Dear Editor,

We present a case of dacryocystitis and canaliculitis secondary to residual of epidural catheter remaining in lacrimal duct for 25y. A 56-year-old male patient was admitted to our medical center on February 16, 2023. We obtained the written informed consent from the patient, and this case study was in accordance with the tenets of the Declaration of Helsinki. The main complaint was that the right eye had suffered from persistent tears for more than 25y and discharge for more than 1y. He had trauma in his right eye and inferior canaliculus laceration and underwent surgery to canaliculus repair with bicanalicular intubation using a lacrimal stent. The stent was removed 3mo later. Despite the patient's ongoing mild epiphora, lacrimal irrigation results indicated patency of the lacrimal drainage. There was a lack of significant attention given to this symptom, and no further investigations or treatments were initiated. One year ago, epiphora was aggravated, accompanied by the onset of pus discharge. Lacrimal irrigation test showed lacrimal drainage blocked. The patient was admitted to the hospital with a suspicion of chronic traumatic dacryocystitis

resulting from old lacrimal trauma, and an exploratory surgical intervention was planned. Ophthalmological examination was unremarkable bilaterally. Lacrimal system examination: partial defect in the right lower canaliculus, with a triangular area of defect measuring 2.5 mm on each side. The nasal broken end of the lower lacrimal canaliculus was found in the nasal edge of the defect area. There were no signs of acute dacryocystitis. The upper and lower lacrimal canaliculus showed "hard stop". Reflux of purulent secretion exited while compressing lacrimal sac. Lacrimal duct irrigation test: using the upper and lower canaliculus irrigation showed obstruction, with the fluid returning to the same puncta with secretion. Positive chloramphenicol taste test in the left eye showed patent. Three-plane reconstruction of computed tomography (CT) dacryocystography based on the trend of nasolacrimal canal (CT-DCG-TPR-BTNC): Contrast agents were irregularly retained in the right lacrimal fossa and nasolacrimal duct on coronal and sagittal CT scans (Figure 1). Partial obstruction located in the nasolacrimal duct.

The diagnosis was right-side chronic traumatic secondary dacryocystitis with partial lacrimal duct obstruction. The patient underwent to external dacryocystorhynchostomy (DCR) under local anesthesia but a residual rigid tube was discovered concealed within the lacrimal sac. A small portion of a rigid tube was located inside the lacrimal sac cavity, with the majority situated in the surrounding tissues of the lacrimal sac and nasolacrimal duct. Both its upper and lower ends are firmly anchored by extensively fibrotic tissue, resulting in immobility (Figure 2). The surgeon meticulously dissected the fibrotic proliferative tissue, excised the lacrimal canaliculus for exploration, and confirmed that this residual tube originates from the inferior canaliculus, passes through the nasolacrimal duct, and ultimately lodges within the lacrimal sac and nasolacrimal duct (Figure 3A).

The removal of the tube during the procedure was very difficult, with a significant amount of purulent secretions around the residual end and in the lower lacrimal canaliculus, resulting in a definitive diagnosis of secondary dacryocystitis and canaliculitis. Considering the patient's medical history,

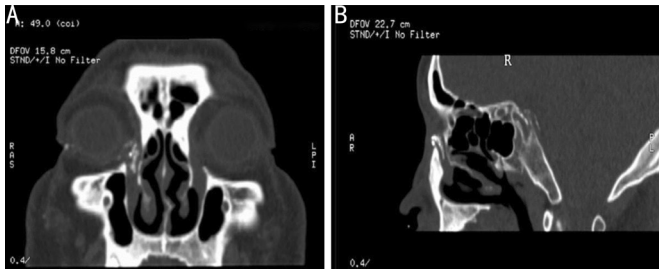


Figure 1 Three-plane reconstruction of CT-DCG-TPR-BTNC A: Coronal position; B: Sagittal position. Contrast agents were irregularly retained in the right lacrimal fossa and nasolacrimal duct. The contrast agent is Ioversol. CT-DCG-TPR-BTNC: Computed tomography dacryocystography based on the trend of nasolacrimal canal.

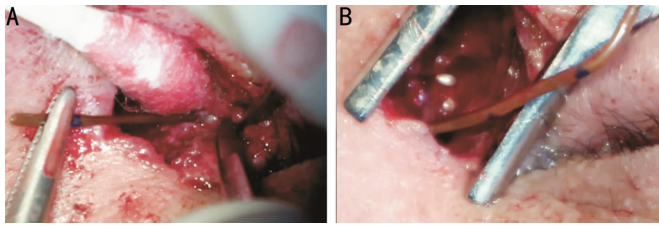


Figure 2 Intraoperative picture A: Surgical incision of the lacrimal sac reveals a retained rigid tube within; B: The tube is firmly encased in severely fibrotic tissue, with purulent secretions around its remnant end.

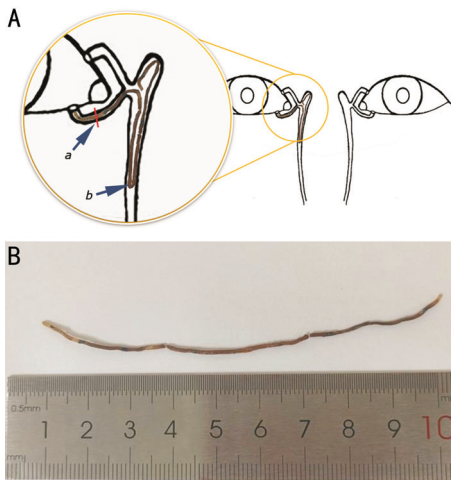


Figure 3 Schematic diagram and real picture A: Schematic diagram illustrating the presence of a lacrimal stent in the lacrimal duct. a: The red mark indicates an old laceration of the right inferior lacrimal canaliculus; b: The structure of the residual epidural catheter tube within the lacrimal duct. B: The epidural catheter removed by surgery.

it was deduced that this residual rigid tube segment was indeed the epidural catheter that was incompletely removed after the initial canalicular intubation performed 25 years ago (Figure 3B). The patients underwent external DCR, removal of residual dural anesthetic tube segment, lesion excision, anastomosis of the inferior canaliculus, bicanalicular silicone tube intubation, and correction of epicanthal deformity. The surgical procedure was successful, with excellent wound healing, and the sutures were removed 7d postoperatively. The patient was discharged successfully. The lacrimal stent was

removed 6mo postoperatively, and the epiphora symptoms disappeared. Follow-up for 12mo showed no recurrence.

Traumatic chronic dacryocystitis is typically a result of nasolacrimal duct obstruction or severe stenosis secondary to nasolacrimal duct injury^[1]. Similarly, traumatic canaliculitis is caused by lacrimal duct obstruction or severe stenosis resulting from trauma. It is uncommon for traumatic chronic dacryocystitis and traumatic canaliculitis to stem from an epidural catheter inadvertently left in the lacrimal duct for an extended period, particularly one inserted during the initial stage of lacrimal canalicular anastomosis^[2]. To the best of our knowledge, such a scenario has not been documented in existing literature. Combining lacrimal canalicular anastomosis with lacrimal intubation represents an effective treatment for canalicular laceration^[3-4] and the practice of lacrimal intubation has a history spanning over 100y^[5]. Throughout history, the materials utilized for lacrimal placement have undergone continuous improvement. In ancient times, these materials ranged from the use of feather tubes from chicken and goose wings, silk thread, plastic, and nylon wire to horsetail, gold, silver, copper, alloy, stainless steel wire, and latex strips (tubes) in the initial stages. Subsequently, with the ongoing evolution of lacrimal stents, materials such as epidural catheters, pediatric intravenous catheters, silicone rubber tubes (strips), medical silicone tubes (strips) of varying shapes and diameters, nitinol lacrimal stents, stainless steel nasolacrimal stents, silicone tubes, and various self-made stents have been employed as lacrimal placement materials in the world^[6]. Nowadays, the good performance of silicone stents in treatment is recognized^[7]. The shared objective of utilizing various materials for lacrimal placement is to restore the lumen in ruptured lacrimal canaliculi. Moreover, with the development of surface engineering techniques, drug and lacrimal stent are combined to obtain better surgical results^[8]. Consequently, safety, effectiveness, and simplicity represent the continual focus and purpose of improvement in this area. In early clinical practice, there have been numerous cases of utilizing epidural catheter to anastomose the ruptured lacrimal canaliculi^[9]. The epidural catheter possesses several advantages, including cost-effectiveness and ease of access. Currently, some primary hospitals still employ it due to restricted resources. However, the epidural catheter, being rigid in nature, is prone to causing lacrimal canalicular laceration and punctal laceration. Prolonged placement of the epidural catheter within the lacrimal duct can result in secondary inflammation, fibrous tissue hyperplasia, and granuloma. Its rigid material makes it susceptible to rupturing within the lacrimal duct, potentially leaving behind residual tube segments. Meanwhile, it is inserted into the lacrimal duct through mono-canalicular intubation. Following intubation, a

segment of the tube is secured on the skin of the eyelid, cheek, or forehead outside the lacrimal duct, which adversely affects appearance, stability, and comfort, particularly causing foreign body sensation. Furthermore, the use of an epidural catheter in the lacrimal duct constitutes an off-label application^[10]. The standardization of lacrimal stent application is necessary. The preferred recommendation is the utilization of silicone stents. For patients with canalicular lacerations requiring lacrimal stent placement, the preferred material recommended is the smooth, soft, and biocompatible silicone lacrimal stent, such as the silicone bicanalicular stent^[11-14]. The treatment approach involving “one-stitch anastomosis through the skin with bicanalicular intubation” has shown to be effective for canalicular lacerations^[15].

In conclusion, for patients with a history of lacrimal intubation, it is important to thoroughly investigate previous surgical details, including the completeness of tube removal, any indications of tube rupture, or the presence of residual segments of the artificial lacrimal stent. The image exams that can help to detect a foreign body inside the lacrimal system. The standardization of lacrimal stent application is necessary. Epidural catheter as lacrimal stent inserted into lacrimal duct for treatment of canalicular laceration can lead to more harm than good. This falls within the realm of off-label use, which is prone to causing medical disputes. Therefore, it is not recommended to use epidural catheters like this case.

ACKNOWLEDGEMENTS

Conflicts of Interest: Dong BR, None; Chen MH, None; Wang P, None; Tao H, None.

REFERENCES

- 1 Amin RM, Hussein FA, Idriss HF, Hanafy NF, Abdallah DM. Pathological, immunohistochemical and microbiological analysis of lacrimal sac biopsies in patients with chronic dacryocystitis. *Int J Ophthalmol* 2013;6(6):817-826.
- 2 Ducasse A, Larré I. Lacrimal system trauma. *J Fr Ophthalmol* 2024;47(3):104076.
- 3 Patnaik JSS, Balaraman K, Ramani V, Bhat K, Thomas D, Bharathi RR, Sabapathy SR. Incidence and outcome of repair of canalicular lacerations: a case series. *J Craniomaxillofac Surg* 2021;49(2):135-139.
- 4 Cai WH, Li ZY, Xie JH, Lv WJ, Lin YD. Canalicular laceration repair with a novel bicanalicular silicone tube. *J Plast Reconstr Aesthet Surg* 2022;75(11):4243-4248.
- 5 Han JJ, Chen HL, Wang T, Zhang XL, Jin XM. A case series study of lacrimal canalicular laceration repair with the bi-canalicular stent. *Gland Surg* 2022;11(11):1801-1807.
- 6 Athanasiov PA, Madge S, Kakizaki H, Selva D. A review of bypass tubes for proximal lacrimal drainage obstruction. *Surv Ophthalmol* 2011;56(3):252-266.
- 7 Sahan B, Ciftci F. Trephination and silicone tube intubation in the treatment of canalicular obstruction. *Int Ophthalmol* 2023;43(2):541-547.
- 8 Xiao WZ, Wang BJ, Wang XM, Zhang GH, Zhao YH, Zhang ZZ, Li LH, Qu C. Two-electron oxidized polyphenol chemistry-inspired superhydrophilic drug-carrying coatings for the construction of multifunctional nasolacrimal duct stents. *J Mater Chem B* 2024;12(11):2877-2893.
- 9 Lin MT, Tsai CC, Lee SS, Lai CS, Lin SD. A new method using epidural catheters in the reconstruction of lacrimal drainage. *Scand J Plast Reconstr Surg Hand Surg* 2005;39(2):85-89.
- 10 Wladis EJ, Aakalu VK, Tao JP, Sobel RK, Freitag SK, Foster JA, Mawn LA. Monocanalicular stents in eyelid lacerations: a report by the American academy of ophthalmology. *Ophthalmology* 2019;126(9):1324-1329.
- 11 Yang YY, Li Q, Yu T, Mao JL, Wang YL, Wu WJ. Bicanalicular-nasal silicone stent for deep canalicular laceration management. *J Plast Reconstr Aesthet Surg* 2023;77:339-345.
- 12 Cai WH, Wang HX, Zhou YK, Zheng X, Li ZY, Cai JH, Zhou YS, Ma YT, Lin YD. Canalicular laceration repair using a novel bicanalicular silicone stent versus traditional bicanalicular stent with nasal fixation. *J Plast Reconstr Aesthet Surg* 2024;90:192-199.
- 13 Zhuang A, Jin XL, Li YW, Fan XQ, Shi WD. A new method for locating the proximal lacerated bicanalicular ends in Chinese preschoolers and long-term outcomes after surgical repair. *Medicine (Baltimore)* 2017;96(33):e7814.
- 14 Bai F, Tao H, Zhang Y, Wang P, Han C, Huang YF, Tao Y. Old canalicular laceration repair: a retrospective study of the curative effects and prognostic factors. *Int J Ophthalmol* 2017;10(6):902-907.
- 15 Tao H, Wang P, Han C, Zhang J, Bai F, He ZY. One-stitch anastomosis through the skin with bicanalicular intubation: a modified approach for repair of bicanalicular laceration. *Int J Ophthalmol* 2013;6(5):656-658.