

# Clinical profile and outcomes of ocular surface squamous neoplasia at the Philippine General Hospital: a retrospective study

Mary Ellaine S. Diaz<sup>1</sup>, Ruben Lim Bon Siong<sup>1,2</sup>, Justin Alan Yao<sup>1</sup>, Gary John V. Mercado<sup>1,3</sup>

<sup>1</sup>Department of Ophthalmology and Visual Sciences, University of the Philippines Manila-Philippine General Hospital, Manila 1000, Philippines

<sup>2</sup>Eye Institute, St. Luke's Medical Center, Quezon City, Manila 1112, Philippines

<sup>3</sup>Eye and Vision Institute, The Medical City, Pasig 1800, Philippines

**Correspondence to:** Mary Ellaine S. Diaz. Sentro Oftalmologico Jose Rizal, Philippine General Hospital, Taft Avenue, Ermita, Manila 1000, Philippines. ellainediaz.md@gmail.com

Received: 2024-01-17 Accepted: 2024-09-05

## Abstract

• **AIM:** To evaluate the demographics, clinical characteristics, treatments, and outcomes of patients with ocular surface squamous neoplasia (OSSN) at the Philippine General Hospital.

• **METHODS:** This was a single-center, 11-year retrospective, cross sectional case series on 18 cases of OSSN seen between January 2012 to June 2023. The patient's demographics, presenting symptoms, tumor characteristics, histopathologic diagnosis, treatment, outcomes, and duration of follow-up were reviewed.

• **RESULTS:** Out of 33 identified cases of OSSN, only 18 were eligible for inclusion in the study. Mean age was 60.78y (range 31 to 80), with male predominance (66.67%). The left eye was most commonly affected (61.11%) with most presenting with fleshy mass (83.33%). Most tumors were located nasally (66.67%) and were predominantly papilliform (44.44%) in morphology with associated hyperpigmentation (38.89%). Squamous cell carcinoma (SCCA) was the most common histopathologic diagnosis (72.22%). The main primary treatment was surgical excision (94.44%) with or without adjunctive therapy, with only 1 patient undergoing first-line topical chemotherapy. Only 3 recurrences (16.67%) were noted with a median follow-up of 7.5mo. A statistically significant recurrence-free odds leaning towards the utilization of cryotherapy was noted.

• **CONCLUSION:** OSSN seen at the Philippine General Hospital is presented as a limbal papilliform mass, most commonly affecting elderly males. Surgical excision with adjuvant cryotherapy and/or chemotherapy is the preferred mode of treatment.

• **KEYWORDS:** ocular surface squamous neoplasia; conjunctival malignancy; squamous cell carcinoma; conjunctival intraepithelial neoplasia

**DOI:10.18240/ijo.2025.01.16**

**Citation:** Diaz ME, Lim Bon Siong R, Yao JA, Mercado GJ. Clinical profile and outcomes of ocular surface squamous neoplasia at the Philippine General Hospital: a retrospective study. *Int J Ophthalmol* 2025;18(1):132-138

## INTRODUCTION

Ocular surface squamous neoplasia (OSSN) is a potentially serious condition that, if left untreated, can lead to visual deterioration or even blindness<sup>[1-2]</sup>. It is the most common non-melanocytic malignancy of the conjunctiva and cornea. It encompasses a spectrum of diseases from pre-invasive conjunctival intraepithelial neoplasia (CIN) to invasive squamous cell carcinoma (SCCA). Its incidence ranges from 0.03 to 3.5 per 100 000 persons/year and accounts for 4% to 29% of orbito-ocular tumors. It typically presents as a white or pink growth on the surface of the eye and can be misdiagnosed as nondysplastic lesions such as pterygium, pyogenic granuloma, or epithelial hyperplasia<sup>[1-3]</sup>. A higher risk was seen among males, Caucasians, and residents of countries located on the lower latitudes<sup>[3-4]</sup>. In a local single-center study that reviewed submitted ophthalmic pathologic specimens, it was found that OSSN among Philipinos comprised 8.4% of all malignant tumors of the eye and its adnexa and is the most common conjunctival malignancy. SCCA accounts for 40.4%, followed by CIN, with 26.3%<sup>[5]</sup>. There appears to be a wide variation in the distribution and outcomes of treatment of OSSN geographically and racially, with some studies reporting that darker-skinned individuals living in tropical climates near the equator can develop the disease much earlier than

Caucasians<sup>[3-4]</sup>. The Philippines is a country that just sits on top of the equator, thus, it would be interesting to note how it will compare to the results of the other countries in terms of clinical profile, tumor characteristics, and treatment outcomes.

CIN is considered a low-grade malignancy, however, upon transformation into SCCA it can exhibit high recurrence rates with potential for metastases to the regional lymph nodes<sup>[1-3]</sup>. Early diagnosis and appropriate therapy with regular monitoring are critical. As of this writing, no local study has investigated on OSSN among Filipinos. Hence, this study aims to describe the clinical profile, histopathologic diagnosis, treatment done, as well as treatment outcomes of patients with OSSN at the Philippine General Hospital.

## PARTICIPANTS AND METHODS

**Ethical Approval** This study was approved by the Research Ethics Board of the University of the Philippines Manila on June 15, 2023 (code 2023-0400-01) and waived the need for written informed consent from the study patients. The protocol adhered to the basic principles of the Declaration of Helsinki and conformed with the guidelines set forth by the International Council for Harmonization-Good Clinical Practice (ICH-GCP).

**Study Population & Clinical Data** This was a single-center, 11-year retrospective case series, utilizing medical records of patients with a clinical and histopathologic diagnosis of ocular surface squamous neoplasia (either SCCA or CIN), that were seen and managed at the External Disease & Cornea Clinic and the Ocular Oncology Clinic of Philippine General Hospital from January 2012 to June 2023.

All patients with a clinical diagnosis of OSSN between January 2012 to June 2023 were included. Cases were identified through the census available from the External Disease & Cornea clinic and the Ocular Oncology clinic. The medical records and histopathologic results were retrieved for review. The records were excluded if the follow-up period was less than 3mo or if the case underwent surgical and/or medical treatment elsewhere before presentation. Other reasons for exclusion were incomplete data or unretrievable charts.

Clinical data collected include age in years, gender, occupation, laterality of involved eye, occupation, chief complaint, visual acuity, specific involved areas of the lesion, tumor size and characteristics, associated clinical findings, histopathologic diagnosis, treatment modalities, outcomes, and follow-up period. Tumor morphology was classified as either papilliform, gelatinous, leukoplakic, combined, predominantly corneal/opalescent, or diffuse/ulcerated, according to how they were described in the medical records. The treatment was categorized as either surgical or non-surgical. Wide surgical excision with at least 2 mm margins *via* no-touch technique as outlined by Shields *et al*<sup>[1]</sup> were performed. Surgical excisions

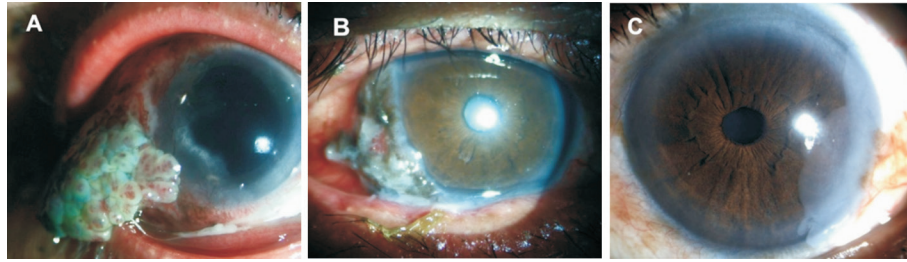
were further classified based on the presence or absence of intraoperative adjuncts. Intraoperative adjuncts included the use of either mitomycin C (MMC) 0.04% or cryotherapy with 3 freeze-thaw cycles. The primary outcome of the study was treatment efficacy, defined as the presence or absence of recurrence. Recurrence of disease was defined as regrowth or reappearance of a mass on the same location or adjacent to previous site of surgical excision, exhibiting clinical features consistent with OSSN and positive lissamine staining, following clinical resolution after completion of previous primary treatment. Secondary outcomes include the clinical profile and tumor characteristics of patients.

**Statistical Analysis** Statistical analysis was done on all valid data of patients included in the study. Normality assessment using the Ryan-Joiner Test of all continuous outcome measures (*e.g.*, age, follow-up duration) was performed. Summary statistics were presented in tables and reported as mean (standard deviation, range) for continuous outcome measures, and as count (percent) for categorical measures (*e.g.*, sex, occupation, laterality, tumor characteristic, treatment strategy). Odds ratio, 95% confidence interval, and *P*-values, using alpha of 5%, were also computed. IBM SPSS Statistics Subscription 1.0.0.1508 and Statdisk-Triola Statistics Series were used in data processing, descriptive statistics, and statistical analysis.

## RESULTS

A total of 33 cases were identified within the inclusive period, with 25 (75.75%) cases of SCCA and 8 CIN (24.24%). However, only 23 records were available for review and from these, 5 were excluded due to incomplete data, follow up less than 3mo, and/or due to history of treatment elsewhere. Thus, only 18 were eligible for inclusion in the study. Included patients had a mean age of 60.78y, ranging from 31 to 80y. Majority of patients were male (66.67%) with a male-female sex ratio of 2:1. All patients had unilateral disease, majority of which involved the left eye (61.11%). Occupation was categorized into outdoor and indoor, with the majority of patients (66.67%) engaging in outdoor work such as farming, fishing, carpentry, and driving of public utility vehicles. Patients were followed up ranging from 3mo to 46mo with a mean of 18mo. Demographic data of patients were summarized in Table 1.

Most of the patients complained of the presence of a fleshy mass (83.33%). Other complaints include foreign body sensation, blurring of vision, and presence of a corneal opacity (Table 2). Mean duration of symptoms or complaints before consult was 1.8y. SCCA was the most common histopathologic diagnosis (72.22%) followed by CIN. Most tumors were located nasally (66.67%) involving both corneal and conjunctival surfaces (72.22%). Clinical morphology (Figure 1) of tumors was mostly papilliform (38.89%)



**Figure 1 Clinical morphology of OSSN** A: Papilliform mass; B: Gelatinous mass with associated hyperpigmentation; C: Predominantly corneal opalescent lesion. OSSN: Ocular surface squamous neoplasia.

**Table 1 Demographic data of patients with ocular surface squamous neoplasia** *n*=18

Parameters	Values
Age, mean±SD (range)	60.78±12.40y (31–80y)
Sex, <i>n</i> (%)	
Male	12 (66.67)
Female	6 (33.33)
Sex ratio (M:F)	2:1
Laterality, <i>n</i> (%)	
Unilateral	18 (100.0)
Right eye	7 (38.89)
Left eye	11 (61.11)
Occupation, <i>n</i> (%)	
Outdoor	12 (66.67)
Indoor	6 (33.33)
Duration of follow-up, mean/median (SD, range)	18/7.5 (14.42, 3–46)mo

SD: Standard deviation.

**Table 2 Chief complaint on presentation** *n* (%)

Complaint	Values
Fleshy mass	15 (83.33)
Foreign body sensation	1 (5.56)
Blurring of vision	1 (5.56)
Corneal opacity	1 (5.56)
Duration of complaint before consult, mean±SD (range)	22.3±2.34 (4–120)mo

followed by gelatinous (27.78%). Hyperpigmentation (38.89%) was the most common associated finding. This was characterized as areas of dark brown patchy pigmentation with irregular borders, some were raised or thickened, blending into the surrounding tumor tissue (Table 3).

Majority of patients underwent surgical procedures (cumulative 94.44%), while only 1 underwent topical chemotherapy as initial therapy (Table 4). The patient that received primary medical therapy presented with a predominantly corneal opalescent lesion, and was started on 5-fluorouracil (5-FU) 1% 4 times a day for 7d with a 3 week-holiday, for a total of 4 cycles. Surgical excision was done with 2-3 mm margins, no touch technique. Of those that underwent surgery, 83.33% had adjuvant therapy using either cryotherapy (44.44%)

**Table 3 Tumor characteristic** *n* (%)

Tumor characteristic	Values
Histopathologic findings	
Squamous cell carcinoma	13 (72.22)
Conjunctival Intraepithelial neoplasia	5 (27.78)
Location	
Nasal	12 (66.67)
Temporal	6 (33.33)
Involved ocular surface	
Corneal-conjunctival	13 (72.22)
Conjunctival	3 (16.67)
Corneal	2 (11.11)
Clinical morphology	
Papilliform	7 (38.89)
Gelatinous	5 (27.78)
Leukoplakic	3 (16.67)
Combined	2 (11.11)
Flat/opalescent	1 (5.56)
Diffuse/ulcerated	-
Associated findings	
Pigmentation	7 (38.89)
Pterygium	1 (5.56)
Calcification	1 (5.56)
Tumor size, mm <sup>2</sup> , mean (range)	65.4 (1–224)

**Table 4 Initial treatments of OSSN and outcomes** *n* (%)

Treatment	Values	Recurrence
Non-surgical		
5-fluouracil 1.0%+mitomycin C 0.04%	1 (5.56)	1 (100)
Surgical (wide excision, no-touch technique)	17 (94.44)	2 (11.76)
No adjunct	2 (11.11)	0
With adjunct	15 (83.33)	
Cryotherapy	8 (44.44)	0
Mitomycin C 0.04%	4 (22.22)	2
Both	3 (16.67)	0

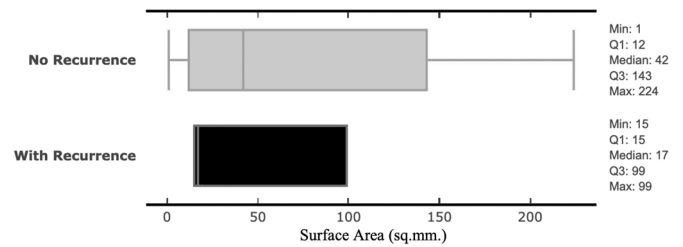
OSSN: Ocular surface squamous neoplasia.

with 2-3 freeze-thaw cycles, MMC 0.04% (22.22%) applied on the conjunctival margins for 2min then rinsed off, or both (16.67%). Two cases received pre-operative 5-FU 1% for 3 cycles prior to surgical excision with intraoperative cryotherapy. Subsequent histopathological evaluation

confirmed SCCA in both cases, with no reported recurrence as of their latest recorded follow-up.

With a mean follow-up of 18mo, there were three recurrences observed in the study. The first patient presented with a corneal opalescent lesion that initially received topical chemotherapy with 5-FU 1% for 4 cycles, however, recurrence was noted 1mo after the last cycle. He subsequently underwent alcohol keratectomy with MMC, and histopathology revealed CIN. Post-operative topical MMC 0.04% was given 4 times a day for 2wk with 2wk off for 2 cycles with good compliance, however, a second recurrence was noted after 3mo presenting as a raised gelatinous perilimbal conjunctival lesion encroaching the cornea with positive lissamine staining. The patient subsequently underwent wide excision with alcohol keratectomy and cryotherapy, where histopathologic diagnosis revealed SCCA with negative surgical margins. It is possible that the first histopathologic evaluation was inaccurate since the submitted specimen was from the cornea only, and dysplastic cells rarely invade an intact Bowman layer. He has been in remission for the last 6mo. The 2<sup>nd</sup> case presented with a fleshy perilimbal mass spanning 9 clock hours that underwent wide excision biopsy with MMC. Initial histopathologic diagnosis was CIN. He was disease-free for 5mo until local recurrence was noted. He underwent repeat excision with MMC and cryotherapy, after which he was disease-free for 4mo before being lost to follow-up. Histopathologic diagnosis revealed SCCA. The 3<sup>rd</sup> case presented with a combined papilliform mass with leukoplakia and underwent wide excision biopsy with MMC for which histopathologic diagnosis was SCCA. Patient was in remission for 30mo before presenting with a suspicious pseudo-ptyerygium in the post-excision area. He underwent repeat wide excision biopsy with cryotherapy, with histopathology confirming recurrence of the SCCA. No recurrence was reported after 6mo post-operatively and thereafter was lost to follow-up.

Relationship of OSSN surface area and recurrence was also analyzed, showing no relationship between the two variables. Surface areas of cases with recurrence and without recurrence are overlapping and, hence, may not be a reliable indicator for recurrence risk (Figure 2). Recurrence-free odds ratio for each combination of treatment strategies and sub-analysis for each treatment strategy, regardless of any combination with other strategies, showed inclusive ratios. Wide confidence intervals were also noted (Table 5). Comparing cryotherapy versus MMC as an adjunct treatment to wide excision showed that cryotherapy is 32.2 times more likely to have recurrence-free results. The confidence interval for its recurrence-free odds (1.23–841.87) significantly showed higher recurrence-free outcomes. However, due to limitations in sample size, the wide



**Figure 2** Box plot of OSSN surface areas comparing cases with and without recurrence OSSN: Ocular surface squamous neoplasia.

**Table 5** Recurrence-free odds

Parameters	OR (95%CI)	P
Individual treatment strategy <sup>a</sup>		
Wide excision	18.60 (0.58–596.70)	0.0985
Topical chemotherapy	0.075 (0.003–1.730)	0.1053
Combined treatment strategy		
Wide excision+cryotherapy	7.93 (0.35–179.97)	0.1935
Wide excision	1.30 (0.05–33.63)	0.8759
Wide excision+cryotherapy+MMC	1.96 (0.08–47.68)	0.6794
Wide excision+MMC	0.067 (0.004–1.116)	0.0596

<sup>a</sup>Sub-analysis for each treatment strategy (wide excision, and topical chemotherapy) not considering any combined strategy. MMC: Mitomycin C; OR: Odds ratio; CI: Confidence interval.

**Table 6** Recurrence-free odds for surgical adjunct

Surgical adjunct treatment	OR (95%CI)	P
Cryotherapy vs mitomycin C	32.20 (1.23–841.87)	0.0371

OR: Odds ratio; CI: Confidence interval.

confidence interval may suggest non-generalizability of the odds estimate (Table 6).

## DISCUSSION

This retrospective series has shown that OSSN is not uncommon in the Philippines, with 33 cases seen in the largest Philippine referral center for eye diseases for the past 11y. However, only 18 cases were included in the analysis. This number is relatively lower than those reported in studies from Korea, Taiwan (China), and Thailand<sup>[6-8]</sup>. There is a possibility that OSSN may be underdiagnosed and underreported in the Philippines due to its geography, and lack of a centralized registry for rare ocular diseases. It has been noted that variations occur in the racial and geographical distribution of OSSN, with most reports involving Caucasian and African populations. In 2015, Gichuhi *et al*<sup>[9]</sup> reported the highest incidence of OSSN in Africa with a younger mean age (41y) and a predominantly female population. Similarly, cases from India have a younger age of onset, but a predominantly male population<sup>[10-11]</sup>. Interestingly, 74% of the African patients and 23% of the Indian cases with OSSN tested positive for the human immunodeficiency virus (HIV)<sup>[9-11]</sup>. Studies among caucasian patients reported a male predilection and tended to be older, at around 60y<sup>[3-4]</sup>. Similarly, studies done among Asian countries and region, namely Korea, Taiwan (China),

and Thailand reported a higher tendency for OSSN to occur among elderly men<sup>[6-8]</sup>. In this retrospective case series, patients were also older with a mean age of 60.78y and with a male predominance.

The most common chief complaint was a fleshy mass, followed by foreign body sensation, blurring of vision, and presence of a corneal opacity. OSSN typically presents as a visible growth on the surface of the eye that can be easily noticed by the patient or others. In some cases, these lesions may exhibit rapid growth which can be alarming for patients thus motivating them to seek medical attention promptly. All tumors in this study were seen along the interpalpebral region, with most tumors occurring at the nasal limbal region. Most involve both the conjunctiva and cornea, similar to previous studies<sup>[6-8]</sup>. The predilection to the nasal area, like pterygium, suggests that both share solar ultraviolet radiation exposure as risk factors. Incident temporal sunlight gets focused nasally with a 20-fold magnification in intensity, resulting in DNA damage and excessive proliferation of cells<sup>[12-13]</sup>. This is supported by the finding that 66.67% of patients in this study had occupations with increased sun exposure, the most common of which include farming, fishing, carpentry, driving of public utility vehicles.

Our study also found that the most common clinical morphology seen was papilliform, consistent with other studies conducted in Asian populations<sup>[6-8]</sup>. In contrast, studies involving African and Indian populations found that a nodular, gelatinous mass was more common<sup>[9-11,14]</sup>. Approximately 38.89% of eyes with OSSN also had hyperpigmentation, resembling melanocytic malignancies. OSSN can resemble pigmented tumors like malignant melanoma or primary acquired melanosis. In one study, Shields *et al*<sup>[15]</sup> described cases of conjunctival carcinoma *in situ* (CIN) that resembled melanoma in both Caucasians and non-Caucasians and suggested that the pigmentation might be due to pigmented dendritic melanocytes within the tumor. Conjunctival pigmentation is generally greater in individuals with darker skin types and the degree of pigmentation can vary due to genetic factors, environmental exposures, presence of inflammation, and others. Hence, pigmented OSSN lesions may be commonly seen among the Asian population.

OSSN is managed through various surgical and non-surgical options, and there remains no consensus regarding the best treatment approach. In our institution, there is currently no treatment guideline for OSSN. In a standard-of-care practice survey done in the US in 2003, and a subsequent follow-up study in 2012, surgical excision was favored as the mainstay therapy for OSSN of various sizes (<2 mm to >8 mm)<sup>[16-17]</sup>. Wide excision using the 'no-touch technique' as described by Shields *et al*<sup>[15]</sup>, is currently the gold standard for treatment,

especially for tumors that occupy four clock hours or less of the limbus, or those with a basal diameter of 15 mm or less<sup>[1,18]</sup>. However, a follow-up survey in 2022 revealed a significant paradigm shift with topical medical therapy becoming the preferred primary treatment for OSSN lesions measuring <2 mm. For lesions measuring 2–8 mm, preference for topical chemotherapy alone was similar to surgery with post-operative medical therapy, while for lesions >8 mm, excision with post-operative medical therapy remained the most preferred treatment approach. Surgical excision alone has become unpopular due to its high risk of recurrence, scarring, and potential for limbal stem cell deficiency<sup>[19]</sup>. Advantages of topical treatment include the ability to treat the entire ocular surface for any microscopic or subclinical disease, and avoiding post-operative limbal stem cell deficiency and scarring<sup>[18-22]</sup>. In this study, 94.44% underwent surgical excision regardless of tumor size, with 88% receiving adjunctive intraoperative treatment with either MMC, cryotherapy, or both. The use of topical therapy in Philippine General Hospital started only recently, in 2022, with the use of 5-FU 1% for chemo-reduction of large tumors prior to surgical excision. Chemo-reduction could be beneficial for situations where topical monotherapy alone is expected to have limited effectiveness<sup>[22]</sup>. However, the available evidence is limited since there have been no studies comparing neoadjuvant chemotherapy to other treatment approaches. In this study, two cases that had a tumor size >150 mm<sup>2</sup> received pre-operative chemotherapy with 5-FU 1% given 4 times a day for 1wk with a 3-week holiday for 3 cycles. Both cases showed a significant decrease in tumor size prior to surgical excision with intraoperative cryotherapy. Histopathologic diagnosis for both cases was SCCA. No recurrence of disease was noted as of their last follow-up. A combination of topical neoadjuvant chemotherapy with surgical excision can avoid the need for extensive surgical excision, enable tissue diagnosis, and decrease the likelihood of tumor recurrence<sup>[19,22]</sup>.

Yeoh *et al*<sup>[22]</sup> have summarized the available evidence surrounding the use of topical chemotherapy and immunomodulatory agents that include 5-FU, MMC, and interferon alpha as monotherapy. This review showed that these 3 agents have very high resolution rates (range 81%–100%) and low recurrence rates (range 0–14%) and seem to be comparable to surgery. Numerous studies have also discussed the safety profile of these agents with 5-FU being reported to be well tolerated with mostly mild side effects<sup>[23-24]</sup>, while use of MMC was reported to be limited due to having more frequent and severe side effects. These side effects included ocular pain, redness, allergic conjunctivitis, epitheliopathy, punctal stenosis, and even limbal stem cell deficiency<sup>[18-22]</sup>. Other disadvantages seen with these topical therapies include

longer duration of therapy, compliance risk, and cost<sup>[19,21-22]</sup>. Interferon alpha 2b was the preferred topical monotherapy in the United States because it had the best safety profile, however, it was also the most expensive<sup>[19,25-26]</sup>. Recently, there has been limited accessibility due to its non-production, hence there is an expected shift to 5-FU as the first-line option for medical therapy since 5-FU and IFN have comparable rates of resolution<sup>[27]</sup>. In the Philippines, IFN remained largely unavailable due to its inaccessibility and high cost, while 5-FU and MMC were more available and affordable. Consequently, 5-FU was the preferred first-line topical therapy since it was better tolerated than MMC and had less severe ocular surface side effects. One patient that was given topical MMC 0.04% experienced mild burning sensation and intermittent eye redness after use.

In this small case series, only 3 (16.67%) recurrences were noted, hence inferential analysis is limited. Other studies reported that recurrence has a wide range of 0 to 56%<sup>[3,9-11]</sup>. In Asian studies, it was 13 to 37%, with most recurrences occurring within 2y of treatment<sup>[6-8]</sup>. In our study, recurrence can occur as early as 3mo and as long as 30mo, which further elucidates the importance of pre-treatment staging and post-treatment monitoring, and long-term follow-up. Diagnosis, staging, and post-treatment monitoring require anterior segment optical tomography (AS-OCT) for detection of depth of invasion and recurrence. This is a readily available, non-invasive diagnostic modality for OSSN with high specificity and sensitivity of up to 100%, that is able to detect subclinical OSSN. It may be used to prevent premature termination of treatment and to monitor treatment response to reduce the risk of overtreatment with topical chemotherapy<sup>[28-30]</sup>. In the Philippines, AS-OCT is only available in a few government institutions that includes the Philippine General Hospital, and in even fewer private institutions. Its use in the diagnosis and post-operative monitoring of OSSN is yet to become routine. One of the strongest predictors for recurrence was positive surgical margins but the use of adjuvant chemotherapy decreased this risk<sup>[31-33]</sup>. The incomplete histopathological records in this retrospective review limited our data interpretation.

Due to the small sample size, recurrence-free odds ratio for each combination of treatment strategies and sub-analysis for each treatment strategy, regardless of any combination with other strategies, showed wide confidence intervals with no statistical significance. However, it was noted that adjuvant intraoperative cryotherapy had a significant lean of recurrence-free odds towards its utilization when compared with MMC. Cryotherapy has consistently been shown to decrease the risk of recurrence. Its use significantly decreased the risk of recurrence even in cases that limited margins to just 2 mm, and in

those with resultant positive margins<sup>[31-33]</sup>. This then increases the confidence of achieving a lower risk of recurrence while being able to conserve the conjunctiva.

The findings of this study should be cautiously interpreted due to the inherent limitations associated with a retrospective study. Furthermore, the relatively small number of included OSSN patients in our tertiary academic institution may not necessarily reflect the features seen in the rest of the Filipino population. Surgeon skill could also have affected the outcomes since the surgeries in this study were done by multiple surgeons consisting of cornea fellows and senior consultants. Other limitations of this study include the absence of data on tumor margins, suboptimal patient compliance to treatment and follow-up examination, and non-routine performance of AS-OCT.

In conclusion, OSSN in the Philippine General Hospital occurred more commonly among men in their sixth decade. The most common presentation was a papilliform mass located on the nasal limbal area, and may be associated with variable pigmentation. Surgical excision with wide margins of at least 2 mm was the preferred treatment approach. Adjuvant cryotherapy seemed to decrease the risk of recurrence. This study had limited data on the use of topical chemotherapy as a standalone treatment for OSSN, and may merit further studies.

#### ACKNOWLEDGEMENTS

The authors thank the Department of Ophthalmology and Visual Sciences of the Philippine General Hospital for their support in the preparation of this paper.

**Conflicts of Interest:** Diaz ME, None; Lim Bon Siong R, None; Yao JA, None; Mercado GJ, None.

#### REFERENCES

- 1 Shields CL, Shields JA. Tumors of the conjunctiva and cornea. *Indian J Ophthalmol* 2019;67(12):1930-1948.
- 2 Basti S, Macsai MS. Ocular surface squamous neoplasia: a review. *Cornea* 2003;22(7):687-704.
- 3 Hollhumer R, Williams S, Michelow P. Ocular surface squamous neoplasia: population demographics, pathogenesis and risk factors. *Afr Vis Eye Health* 2020;79(1):a553.
- 4 Sun EC, Fears TR, Goedert JJ. Epidemiology of squamous cell conjunctival cancer. *Cancer Epidemiol Biomarkers Prev* 1997;6(2):73-77.
- 5 Domingo RE, Manganip LE, Castro RM. Tumors of the eye and ocular adnexa at the philippine eye research institute: a 10-year review. *Clin Ophthalmol* 2015;9:1239-1247.
- 6 Tananuvat N, Niparugs M, Wiwatwongwana D, Lertprasertsuk N, Mahanupap P. Ocular surface squamous neoplasia in northern Thailand: a 16-year review. *BMC Ophthalmol* 2022;22(1):121.
- 7 Ma IH, Hu FR, Wang IJ, Chen WL, Hsu YJ, Chu HS, Yuan CT, Hou YC. Clinicopathologic correlation of ocular surface squamous neoplasia from a university hospital in North Taiwan 1994 to 2014. *J Formos Med Assoc* 2019;118(4):776-782.

- 8 Kim BH, Kim MK, Wee WR, Oh JY. Clinical and pathological characteristics of ocular surface squamous neoplasia in an Asian population. *Graefes Arch Clin Exp Ophthalmol* 2013;251(11):2569-2573.
- 9 Gichuhi S, Macharia E, Kabiru J, Zindamoyen AM, Rono H, Ollando E, Wanyonyi L, Wachira J, Munene R, Onyuma T, Sagoo MS, Weiss HA, Burton MJ. Clinical presentation of ocular surface squamous neoplasia in Kenya. *JAMA Ophthalmol* 2015;133(11):1305-1313.
- 10 Dandala PP, Malladi P, Kavitha. Ocular surface squamous neoplasia (OSSN): a retrospective study. *J Clin Diagn Res* 2015;9(11):NC10-NC13.
- 11 Meel R, Dhiman R, Vanathi M, Pushker N, Tandon R, Devi S. Clinicodemographic profile and treatment outcome in patients of ocular surface squamous neoplasia. *Indian J Ophthalmol* 2017;65(10):936-941.
- 12 Coroneo M. Ultraviolet radiation and the anterior eye. *Eye Contact Lens* 2011;37(4):214-224.
- 13 Chawda D, Shinde P. Effects of solar radiation on the eyes. *Cureus* 2022;14(10):e30857.
- 14 Fasina O. Ocular surface squamous neoplasia at a tertiary eye facility, southwestern Nigeria: a 10-year review. *Int Ophthalmol* 2021;41(10):3325-3331.
- 15 Shields CL, Manchandia A, Subbiah R, Eagle RC, Shields JA. Pigmented squamous cell carcinoma *in situ* of the conjunctiva in 5 cases. *Ophthalmology* 2008;115(10):1673-1678.
- 16 Stone DU, Butt AL, Chodosh J. Ocular surface squamous neoplasia: a standard of care survey. *Cornea* 2005;24(3):297-300.
- 17 Adler E, Turner JR, Stone DU. Ocular surface squamous neoplasia: a survey of changes in the standard of care from 2003 to 2012. *Cornea* 2013;32(12):1558-1561.
- 18 Alvarez OP, Zein M, Galor A, Karp CL. Management of ocular surface squamous neoplasia: bowman club lecture 2021. *BMJ Open Ophthalmol* 2021;6(1):e000842.
- 19 Greenfield JA, Cohen AK, Galor A, Chodosh J, Stone D, Karp CL. Ocular surface squamous neoplasia: changes in the standard of care 2003 to 2022. *Cornea* 2024;43(8):942-949.
- 20 Höllhumer R, Williams S, Michelow P. Ocular surface squamous neoplasia: management and outcomes. *Eye (Lond)* 2021;35:1562-1573.
- 21 Al Bayyat G, Arreaza-Kaufman D, Venkateswaran N, Galor A, Karp CL. Update on pharmacotherapy for ocular surface squamous neoplasia. *Eye Vis (Lond)* 2019;6:24.
- 22 Yeoh CHY, Lee JJR, Lim BXH, *et al.* The management of ocular surface squamous neoplasia (OSSN). *Int J Mol Sci* 2022;24(1):713.
- 23 Parrozzani R, Frizziero L, Trainiti S, Testi I, Miglionico G, Pilotto E, Blandamura S, Fassina A, Midena E. Topical 1% 5-fluorouracil as a sole treatment of corneconjunctival ocular surface squamous neoplasia: long-term study. *Br J Ophthalmol* 2017;101(8):1094-1099.
- 24 Wylegala A, Sripawadkul W, Zein M, Alvarez OP, Al Bayyat G, Galor A, Karp CL. Topical 1% 5-fluorouracil eye drops as primary treatment for ocular surface squamous neoplasia: long-term follow-up study. *Ocul Surf* 2023;27:67-74.
- 25 Karp CL, Galor A, Chhabra S, Barnes SD, Alfonso EC. Subconjunctival/perilesional recombinant interferon  $\alpha$ 2b for ocular surface squamous neoplasia: a 10-year review. *Ophthalmology* 2010;117(12):2241-2246.
- 26 Sripawadkul W, Reyes-Capo D, Zein M, Wylegala A, Albayyat G, Galor A, Karp CL. Long term study of topical interferon  $\alpha$ -2b eye drops as primary treatment of ocular surface squamous neoplasia. *Ocul Surf* 2023;28:108-114.
- 27 Venkateswaran N, Mercado C, Galor A, Karp CL. Comparison of topical 5-fluorouracil and interferon Alfa-2b as primary treatment modalities for ocular surface squamous neoplasia. *Am J Ophthalmol* 2019;199:216-222.
- 28 Karp CL, Mercado C, Venkateswaran N, Ruggeri M, Galor A, Garcia A, Sivaraman KR, Fernandez MP, Bermudez A, Dubovy SR. Use of high-resolution optical coherence tomography in the surgical management of ocular surface squamous neoplasia: a pilot study. *Am J Ophthalmol* 2019;206:17-31.
- 29 Höllhumer R, Michelow P, Williams S. Diagnosis and staging of ocular surface squamous neoplasia. *Afr Vis Eye Health* 2020;79(1):a590.
- 30 Venkateswaran N, Sripawadkul W, Karp CL. The role of imaging technologies for ocular surface tumors. *Curr Opin Ophthalmol* 2021;32(4):369-378.
- 31 Galor A, Karp CL, Oellers P, Kao AA, Abdelaziz A, Feuer W, Dubovy SR. Predictors of ocular surface squamous neoplasia recurrence after excisional surgery. *Ophthalmology* 2012;119(10):1974-1981.
- 32 Bowen RC, Soto H, Raval V, Bellerive C, Yeane G, Singh AD. Ocular surface squamous neoplasia: outcomes following primary excision with 2mm margin and cryotherapy. *Eye(Lond)* 2021;35(11):3102-3109.
- 33 Li AS, Shih CY, Rosen L, Steiner A, Milman T, Udell IJ. Recurrence of ocular surface squamous neoplasia treated with excisional biopsy and cryotherapy. *Am J Ophthalmol* 2015;160(2):213-219.e1.