

Idiopathic uveal effusion syndrome with increased intraocular pressure

Zhi-Bin Wang¹, Xue Wang², Yu Di¹

¹Department of Ophthalmology, Shengjing Hospital of China Medical University, Shenyang 110004, Liaoning Province, China

²Department of Ophthalmology, Tianjin Nankai Hospital, Tianjin 300070, China

Co-first authors: Zhi-Bin Wang and Xue Wang

Correspondence to: Yu Di. Department of Ophthalmology, Shengjing Hospital of China Medical University, Shenyang 110004, Liaoning Province, China. diyujsdxt@163.com

Received: 2024-02-26 Accepted: 2024-09-29

DOI:10.18240/ijo.2025.02.22

Citation: Wang ZB, Wang X, Di Y. Idiopathic uveal effusion syndrome with increased intraocular pressure. *Int J Ophthalmol* 2025;18(2):362-365

Dear Editor,

We reported the case of idiopathic uveal effusion syndrome (IUES) with increased intraocular pressure. IUES is a disease caused by an abnormal increase in serous exudation of the choriocapillaris in the eye for unknown reasons; it accumulates in the choroid and subretinal space, leading to choroidal and ciliary body detachment and non-rhegmatogenous retinal detachment^[1]. The diagnosis of IUES requires the exclusion of other causes of uveal effusion, such as choroidal tumors, uveitis, and surgical causes^[2-3]. IUES is rare in clinical settings. Patients often present with unilateral retinal detachment, and sometimes with only macular neuroepithelial detachment^[4]. IUES is easily misdiagnosed as simple retinal detachment, uveitis, or central serous chorioretinopathy^[5]. Because some patients with IUES are effective in taking oral corticosteroids, it can be confused with uveitis^[6], and IUES with elevated intraocular pressure can easily be misdiagnosed as an acute attack of glaucoma, which may lead to inappropriate treatment and decay in the patient's condition. Careful attention is necessary for the accurate diagnosis and timely treatment of this rare condition. Systemic corticosteroid application and surgical treatment is the IUES mainstream treatments^[1]. We recently discovered a case of IUES with elevated intraocular pressure. Written informed consent was

obtained from the patient for the publication of potentially identifiable images or data included in this article.

A 40-year-old male patient was admitted to our hospital with bilateral orbital pain that had persisted for more than half a month. Half a month before admission, the patient complained of blurred vision in the right eye without an obvious cause and then developed severe pain, accompanied by binocular vision loss, severe dizziness, headache, and nausea without vomiting. No redness of the eyes, photophobia, tears, increased secretion, or other discomfort was reported. The patient's other general conditions were normal. The patient had no previous history of ocular diseases and denied systemic diseases such as hypertension, diabetes, or immune system diseases. At the onset of the disease, the patient was found to have elevated intraocular pressure [right eye (OD), 44 mm Hg; left eye (OS), 42 mm Hg] at the local primary hospital. The local hospital provided the patient with an intravenous infusion of mannitol and eye drops combined with oral absorption (iodized lecithin) and intraocular pressure-lowering drugs; however, the patient was not given a clear diagnosis. On admission to our hospital, the visual acuity of both eyes was OD: 0.1 (corrected 0.6), OS: 0.1 (corrected 0.6), and there was no inflammatory reaction in the anterior segment of either eye. The pupils of both eyes were slightly reduced (pilocarpine-induced reduction), with a diameter of approximately 2 mm and light reaction (+). The anterior segment optical coherence tomography (OCT) could clearly show the structure of the anterior chamber. After examination, we found that the patient's anterior chamber was extremely shallow and the iris was dilated in both eyes (Figure 1). After that, we further performed ultrasound biomicroscopy (UBM) examination on the patient. UBM, which has low penetration to the ocular tissue, is commonly used clinically to understand the anterior segment, the anterior chamber angle and its surrounding tissue structure, and to diagnose diseases of the ciliary body and peripheral retina. The results showed anterior displacement of the ciliary process, a dilated iris, and root hypertrophy in right eye. Shallow anterior chambers, angle closures, and ciliary detachments were observed in 90 of the 360 degrees (Figure 2). To further understand the choroidal thickness, we performed OCT, which revealed

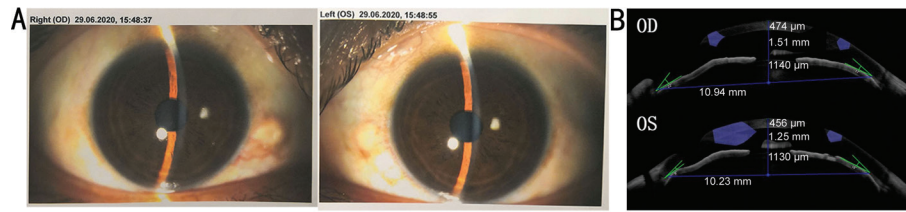


Figure 1 Anterior segment photograph and bilateral anterior segment OCT at admission of both eyes A: Anterior segment photograph of both eyes at admission; B: Bilateral anterior segment OCT at admission. Degree of the angle of the anterior chamber: OD-I degree; OS-I degree. OD: Right eye; OS: Left eye; OCT: Optical coherence tomography.

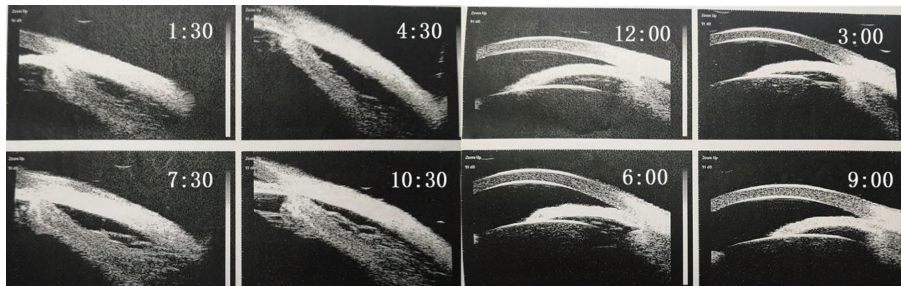


Figure 2 Ultrasound biomicroscopy examination at admission (right eye) The result showed shallow anterior chamber, angle closure, and ciliary detachment in right eye.

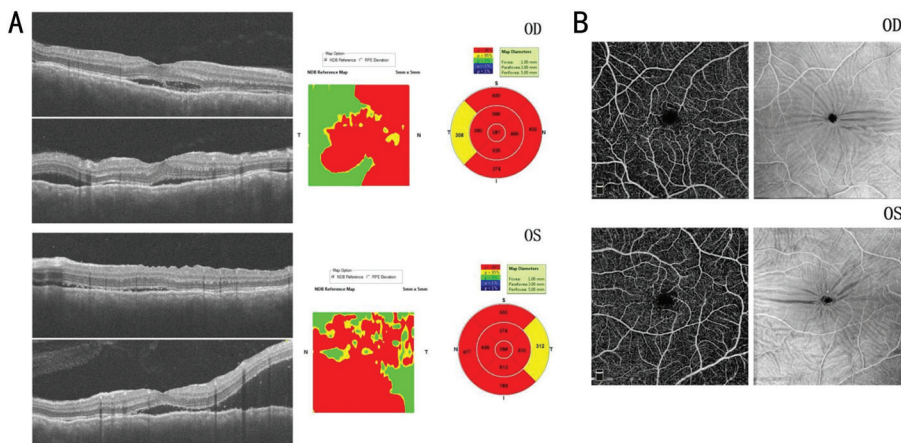


Figure 3 OCT and OCTA examination of both eyes at admission A: Optical coherence tomography examination of both eyes at admission; B: Optical coherence tomography angiography (OCTA) in both eyes at admission. The results showed that there are neurosensory detachments (A) and choroidal folds (B) in both eyes. OD: Right eye; OS: Left eye.

choroidal thickening in both eyes with multiple neurosensory detachments (Figure 3).

After admission, the patient stopped using intraocular pressure-lowering drugs and was treated with 80 mg methylprednisolone sodium succinate intravenous infusion for 7d, during which time the anterior chamber of both eyes gradually deepened. On the fourth day of medication, the depth of the anterior chamber was normal, and visual acuity was significantly improved compared to that on admission. Seven days later (before discharge), the visual acuity in both eyes was OD: 0.3 (corrected to 0.8), OS: 0.4 (corrected to 0.8). Choroidal detachment was significantly reduced in both eyes but did not completely recover. Intraocular pressure was OD: 15 mm Hg and OS: 15 mm Hg.

After discharge, the prednisone dose was tapered gradually. Oral prednisone tablets were administered at 60 mg daily in the

morning, then reduced by 10 mg per week until reaching 10 mg per day. After two weeks, the drug was discontinued. One week after discharge, the visual acuity of the patient was OD: 0.6 (corrected to 1.0) and OS: 0.6 (corrected to 1.0), the anterior chambers of both eyes had returned to normal depth, the ciliary body was significantly reattached, and choroidal detachment was reattached. Intraocular pressure was OD: 15 mm Hg and OS: 15 mm Hg.

IUES is clinically rare^[7], and related literature is scarce. Ciliary body detachment, choroidal detachment, and retinal detachment can lead to the reduction of the volume of the vitreous cavity, and the abnormal position of the ciliary body after ciliary body detachment will cause the closure of the anterior chamber angle and lead to the increase of intraocular pressure^[3].

IUES must be differentiated from the following diseases: 1) Uveitis. IUES has some characteristics that differentiate it

from uveitis. It often occurs in patients without autoimmune diseases. The symptom of Vogt-Koyanagi-Harada disease usually share some similarities with IUES, such as neurosensory detachments, bilateral disease, folds of the pigmented epithelium, fluctuations in the internal limiting membrane, headache; however, patients with this disease may have tinnitus, skin leukoplakia, hearing impairment, and other manifestations. Generally, there is no inflammatory reaction in the anterior chamber or vitreous humor. Fluorescence angiography showing mottled fluorescence, a leopard-like change, can also help in the differential diagnosis. 2) Posterior scleritis. The disease can also be accompanied by orbital pain, bilateral swelling, and pain, along with Neurosensory detachments and choroid folds. It remains to be verified by the T sign on an ocular ultrasound or by nuclear magnetic resonance. 3) Central serous chorioretinopathy. IUES can be easily confused with central serous chorioretinopathy when only macular retinal detachment occurs^[4], both of which are more common in young and middle-aged healthy men without inflammation of the anterior segment or vitreous body, which may lead to misdiagnosis and mistreatment. 4) Retinal detachment. Some rhegmatogenous retinal detachments, because the holes are small and located in very peripheral areas, may not be detected before surgery^[8]; however, the morphology of retinal detachment was not symmetrical (except for the hole at 6 o'clock), the height of detachment was mostly at the hole, and pigment flappers or proliferation could be seen in the vitreous cavity^[9].

The diagnosis of this disease requires a full understanding of the patient's general condition, occurrence, and development of the disease, and a general examination to exclude the diagnosis of uveitis. Auxiliary examinations, such as fluorescence angiography, OCT, color Doppler imaging, and UBM, are essential for the diagnosis of this disease, and UBM is the key to its early diagnosis.

The use of corticosteroid can promote the absorption of retinal exudation, effectively relieve eye posterior chamber pressure, promote the recovery of the corner, have the effect of intraocular pressure reduction, which helps to alleviate early illness as well as the recovery of vision^[4]. And this method is non-invasive, less pain for patients, and more easy to accept. During the period of corticosteroid treatment, the signs and symptoms of the patient gradually stabilized, and ophthalmic examination showed that the binocular ciliary body angle and choroid gradually returned to a normal shape. After discharge, the patient's corticosteroids were changed to oral prednisone tablets, and the dose was gradually reduced until a small dose was maintained. During this period, eye B-mode ultrasound and UBM examinations should be regularly performed to closely detect changes in the condition, adjust the medication

dose of corticosteroids at any time, pay attention to the general condition, and prevent the occurrence of complications. Besides, some studies have found that systemic corticosteroids therapy may not be effective^[1].

In addition to systemic steroid therapy, surgery is another important treatment option for patients with IUES. Shen *et al*^[1] collected data from 33 eyes of 26 patients with IUES. A total of four-quadrant lamellar sclerectomy, in combination with partial full-thickness sclerostomy, was performed on every patient. In the study by Zhu *et al*^[10], they applied topical mitomycin-C before further performing sclerostomy in additional quadrants of the eye, which may be considered a potential therapeutic adjunct in the treatment of IUES.

In this study, we report a case of IUES with elevated intraocular pressure. In addition to the typical manifestations of IUES, such as no inflammatory reaction in the anterior segment of both eyes, ciliary body detachment, and choroidal thickening in both eyes, atypical manifestations such as a shallow anterior chamber, dilated iris, and angle closure in both eyes have also been reported. The patient achieved satisfactory therapeutic effects after systemic corticosteroids therapy. Based on this case report, we suggest that systemic corticosteroid administration is the first choice for patients with IUES. If the effect is not satisfactory, the drug can be stopped and the patient should be observed, and then surgical treatment can be considered.

This case report demonstrates that a diagnosis of IUES requires a detailed understanding of the patient's medical history, careful eye examination, and sufficient ophthalmic auxiliary examination, besides UBM can be a technique that helps diagnose and assess the response to treatment of IUES. Although this disease is rare, it is necessary to fully understand its clinical characteristics, differential diagnosis, and treatment to avoid misdiagnosis and delayed treatment. We look forward to more research in the future to explore the specific pathogenesis of IUES and the optimal treatment.

ACKNOWLEDGEMENTS

Foundations: Supported by the National Natural Science Foundation of China (No.81600747); Foundation of Liaoning Province Education Administration (No.JYTMS20230089); Joint Project Planned by the Department of Science and Technology of Liaoning Province (No.2023JH2/101700129).

Conflicts of Interest: Wang ZB, None; Wang X, None; Di Y, None.

REFERENCES

- 1 Shen ZJ, Shen L, Wang H. Clinical characteristics and surgical treatment of idiopathic uveal effusion syndrome. *Int J Ophthalmol* 2022;15(4):604-608.
- 2 Breazzano MP, Chen RWS. Scleritis with uveal effusion from alirocumab. *Ann Intern Med* 2020;172(12):834-836.

- 3 Lee DH, Kim TY, Lee SC, *et al.* Uveal effusion associated with presumed viral encephalitis. *Ocul Immunol Inflamm* 2022;30(1):68-72.
- 4 Francone A, Rosales D, Lavaque E, *et al.* Type III uveal effusion syndrome: unilateral idiopathic serous detachment. *Ophthalmol Retina* 2018;2(6):637-639.
- 5 Boulanger E, Bonnin S, Delahaye-Mazza C, *et al.* Central serous chorioretinopathy mimicking idiopathic uveal effusion syndrome. *Retin Cases Brief Rep* 2023;17(3):288-293.
- 6 Shields CL, Roelofs K, di Nicola M, *et al.* Uveal effusion syndrome in 104 eyes: response to corticosteroids—the 2017 Axel C. Hansen lecture. *Indian J Ophthalmol* 2017;65(11):1093-1104.
- 7 Sharma R, Foot B, Jackson TL. A prospective, population-based, surveillance (BOSU) study of uveal effusion syndrome in the UK. *Eur J Ophthalmol* 2021;31(5):2451-2456.
- 8 Li X. Observation on the curative effect of scleral buckling operation on old retinal detachment. *Inner Mongolia Med J* 2020;52(04):430-431.
- 9 Chua J, Ke MY, Tan BY, *et al.* Association of macular and choroidal perfusion with long-term visual outcomes after macula-off rhegmatogenous retinal detachment. *Br J Ophthalmol* 2022;106(9):1258-1263.
- 10 Zhu I, Haq Z, Ali MH, *et al.* Application of adjunctive topical mitomycin-c in sclerostomy revision for refractory idiopathic uveal effusion syndrome. *Retin Cases Brief Rep* 2021;15(4):339-343.