

# Traumatic subhyaloid hemorrhage treated with argon laser-assisted hyaloidotomy

Seokoh Lee<sup>1</sup>, Ga Hee Han<sup>1</sup>, Yoo-Ri Chung<sup>1,2</sup>

<sup>1</sup>Department of Ophthalmology, Ajou University School of Medicine, Suwon 16499, Republic of Korea

<sup>2</sup>Department of Ophthalmology, Pitié-Salpêtrière University Hospital, Sorbonne University, Paris 75013, France

**Correspondence to:** Yoo-Ri Chung. Department of Ophthalmology, Ajou University School of Medicine, 164 World Cup-ro, Yeongtong-gu, Suwon 16499, Republic of Korea. [hyalith@ajou.ac.kr](mailto:hyalith@ajou.ac.kr)

Received: 2024-03-08 Accepted: 2024-05-24

**DOI:10.18240/ijo.2025.03.25**

**Citation:** Lee S, Han GH, Chung YR. Traumatic subhyaloid hemorrhage treated with argon laser-assisted hyaloidotomy. *Int J Ophthalmol* 2025;18(3):562-564

## Dear Editor,

Acute subhyaloid hemorrhage causes sudden profound vision loss in the macular region. This is a term that designates ocular hemorrhages lying between the posterior hyaloid membrane and the retina, often presented as a 'boat' or 'D' shaped hemorrhage<sup>[1]</sup>. The development of optical coherence tomography (OCT) had enabled detailed differentiation of subhyaloid hemorrhage, allowing the term sub-internal limiting membrane (ILM) hemorrhage to be applied in selected cases where the blood is located beneath the ILM<sup>[1-2]</sup>. However, it is not always possible to distinguish the location of the hemorrhage due to the attenuation of the retinal structures on OCT. Accordingly, subhyaloid hemorrhage remains a widely used term, implying both subhyaloid and sub-ILM hemorrhage<sup>[1]</sup>.

Subhyaloid hemorrhage can occur in patients with preexisting retinal vascular disorders, such as age-related macular degeneration, retinal artery macroaneurysms, polypoidal choroidal vasculopathy, leukemic retinopathy, and proliferative diabetic retinopathy<sup>[3-5]</sup>. In otherwise healthy patients, trauma and Valsalva retinopathy are the common causes of subhyaloid hemorrhage<sup>[6-8]</sup>. Multiple therapeutic options exist to treat subhyaloid hemorrhage, but the optimal treatment remains controversial. Simple observation with conservative care can be considered while awaiting spontaneous resolution.

Alternatively, pneumatic displacement, neodymium-doped yttrium aluminum garnet (Nd:YAG) laser-hyaloidotomy, or vitrectomy can be applied to drain or displace the entrapped hemorrhage<sup>[6]</sup>. The use of argon laser to treat subhyaloid or sub-ILM hemorrhage is rarely reported<sup>[9]</sup>; therefore, we herein report a case of traumatic subhyaloid hemorrhage successfully treated with argon green laser.

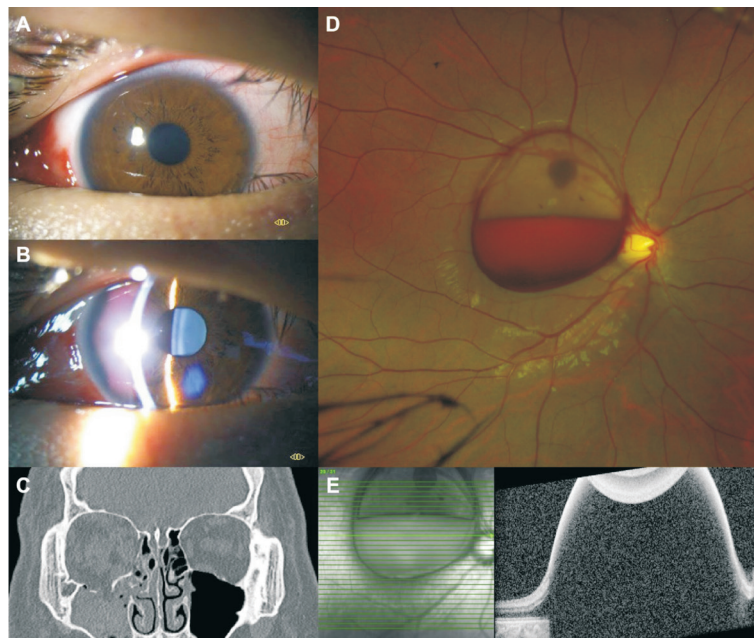
## CASE REPORT

**Ethical Approval** The study was conducted in accordance with the Declaration of Helsinki. This case report was approved by the Institutional Review Board of Ajou University Hospital, Suwon, Korea (IRB No.AJOUIRB-EX-2023-588) and informed consent was waived.

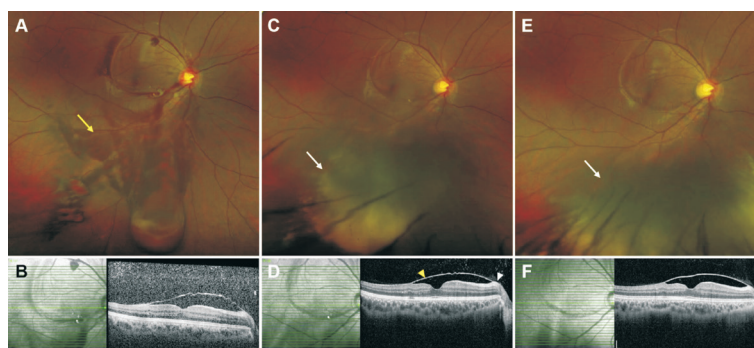
A 20-year-old male presented with a sudden decrease of vision in the right eye following blunt facial trauma. He had no known systemic illness, except for major depressive disorder. Corrected visual acuity was finger count in the right eye and 20/20 in the left eye. He presented with features associated with trauma in the right eye, including moderate palpebral bruise and edema, subconjunctival hemorrhage, and minimal microscopic hyphema on slit lamp examination (Figure 1A, 1B). Facial computed tomography revealed right medial and inferior orbital wall fracture (Figure 1C). Fundus examination revealed a large subhyaloid hemorrhage involving the fovea in the right eye, which was also identified on OCT (Figure 1D, 1E). Clinical findings in the left eye were unremarkable.

The patient was observed with conservative care for 2d to check for improvement or deterioration. The large subhyaloid hemorrhage persisted without any change; therefore, treatment options were discussed with the patient. For laser-assisted hyaloidotomy, hyaloid membrane puncture was performed using argon laser on the same day. The lowest margin of the subhyaloid hemorrhage was targeted, with the smallest spot size (50 μm), power starting at 300 mW, and duration of 0.05s. After 24 shots with the power increased to 900 mW, the hyaloid membrane was punctured and the hemorrhage was drained.

Four days after the laser treatment, the vision of the right eye had improved to 20/30, and most of the subhyaloid hemorrhage had drained into the vitreous cavity (Figure 2A, 2B). The drained vitreous hemorrhage became organized but decreased in



**Figure 1 Ocular findings at initial presentation** A, B: Slit lamp examinations showing subconjunctival hemorrhage, clear cornea, and deep anterior chamber in the right eye; C: Facial computed tomography showing right medial and inferior orbital wall fractures; D: Fundus photograph showing a large subhyaloid hemorrhage involving the fovea; E: Optical coherence tomography showing a significant height of subhyaloid hemorrhage, with attenuation of underlying retinal structures.



**Figure 2 Clinical course after argon laser-assisted posterior hyaloidotomy** A, B: Mostly drained subhyaloid hemorrhage into the vitreous cavity (yellow arrow) 4d after laser treatment; C: More organized but smaller vitreous hemorrhage (white arrow) 1mo after laser treatment; D: Partially detached internal limiting membrane remained at 1mo (yellow arrowhead), while posterior hyaloid membrane became identifiable with more vitreous media (white arrowhead); E, F: Remaining vitreous hemorrhage (white arrow) with persistent detached internal limiting membrane at 6mo.

amount (Figure 2C, 2D), and the reconstruction of orbital wall fractures was performed without complication in 2wk after injury. A partially detached ILM was identified on OCT with clearer vitreous media in 1mo after the procedure (Figure 2D). At the latest 6mo follow-up visits, some vitreous hemorrhages persisted, with improved vision to 20/20 (Figure 2E, 2F). No definite scarring or damage to the retinal pigment epithelium was observed at the laser site.

Small subhyaloid hemorrhage can wait for spontaneous resolution in most cases; however, there is a risk of permanent vision impairment due to the toxic effects of prolonged exposure to hemoglobin and iron<sup>[10]</sup>. Treatments including Nd:YAG laser-assisted hyaloidotomy, pneumatic displacement, and vitrectomy are preferred for larger subhyaloid hemorrhages.

As vitrectomy is a relatively invasive procedure, this option is usually preserved for cases where other noninvasive methods fail. Common progression of postoperative cataract is another point to consider when planning vitrectomy in phakic patients. Pneumatic displacement with gas and/or tissue plasminogen activator is often considered in cases with submacular hemorrhage, but retinal detachment can occur as a complication<sup>[11-12]</sup>. Consequently, the Nd:YAG laser is primarily used to drain the subhyaloid hemorrhage into the vitreous cavity<sup>[10,13]</sup>. This procedure is often performed by focusing the Nd:YAG laser beam on the inferior margin of the subhyaloid membrane and puncturing the posterior hyaloid surface. This noninvasive procedure is relatively safe, although rare complications such as iatrogenic macular hole or secondary

choroidal neovascularization have been reported<sup>[14-15]</sup>.

Argon laser can be applied in various ocular diseases with different protocols, depending on the targeted tissue and indications. Letting the large subhyaloid hemorrhage serve as a protective buffer against the laser burns to the retina, we applied a similar protocol of peripheral iridotomy to perform hyaloidotomy. The shots were repeated to the same targeted point at the inferior margin, which was easy to identify as it was a white-yellow mark at the beginning. By gradually augmenting the power, the targeted hyaloid membrane was opened successfully, with drainage of the subhyaloid hemorrhage. No definite damage to the photoreceptor and/or retinal pigment epithelium layer or iatrogenic retinal breaks were observed on OCT. In the literature, there was one case treated with argon laser due to Valsalva retinopathy, which presented as a subclinical pseudohole near the laser site after 2-year follow-up<sup>[9]</sup>. Otherwise, most reports revealed no definite complications associated with argon laser. However, caution should be exercised when concluding that argon laser-assisted hyaloidotomy has minimal complications, as there are no larger-scale comparative studies.

In summary, we report a case of a traumatic subhyaloid hemorrhage that was successfully treated with argon laser. Argon laser therapy can be a safe option for treating subhyaloid hemorrhage, particularly in young patients with large hemorrhage allowing low probability of side effect from laser burns.

#### ACKNOWLEDGEMENTS

This case was presented as a poster at the 130<sup>th</sup> Annual Meeting of the Korean Ophthalmological Society, Seoul, Republic of Korea, November 23-26, 2023.

**Conflicts of Interest:** Lee S, None; Han GH, None; Chung YR, None.

#### REFERENCES

- Mennel S. Subhyaloidal and macular haemorrhage: localisation and treatment strategies. *Br J Ophthalmol* 2007;91(7):850-852.
- Hayamizu R, Totsuka K, Azuma K, *et al.* Optical coherence tomography findings after surgery for sub-inner limiting membrane hemorrhage due to ruptured retinal arterial macroaneurysm. *Sci Rep* 2022;12(1):16321.
- Ghanbarnia M, Sedaghat S, Rasoulinejad SA. Leukemic retinopathy presenting as concurrent bilateral subhyaloid hemorrhage and subarachnoid hemorrhage in a patient with acute monocytic leukemia: a case report. *J Med Case Rep* 2022;16(1):466.
- Mahjoub A, Zaafrane N, Ben Youssef C, *et al.* Retinal artery macroaneurysm complicated with subhyaloid hemorrhage: two case reports. *Ann Med Surg (Lond)* 2023;85(4):1130-1136.
- Almater AI, Alhadlaq GS, Alromaih AZ. Unilateral subhyaloid hemorrhage as a presenting sign of chronic myeloid leukemia. *Am J Case Rep* 2022;23:e936266.
- Alarfaj MA, Hasen AA, Al-Yami SS. Traumatic subhyaloid macular hemorrhage with complete resolution following Neodymium-Doped Yttrium Aluminium Garnet Laser. *Am J Ophthalmol Case Rep* 2018;9:85-87.
- Leite J, Meireles A, Correia NA. Valsalva retinopathy after a vomiting episode. *Case Rep Ophthalmol* 2022;13(3):706-710.
- Rohowetz LJ, Patel V, Sridhar J, *et al.* Valsalva retinopathy: clinical features and treatment outcomes. *Retina* 2023;43(8):1317-1320.
- Tirhis H, Caglar C, Yilmazbas P, *et al.* Argon green laser for Valsalva retinopathy treatment and long-term follow-up of the internal limiting membrane changes in optical coherence tomography. *Korean J Ophthalmol* 2015;29(6):437-438.
- Khadka D, Bhandari S, Bajimaya S, *et al.* Nd: YAG laser hyaloidotomy in the management of Premacular Subhyaloid Hemorrhage. *BMC Ophthalmol* 2016;16:41.
- Sniatecki JJ, Ho-Yen G, Clarke B, *et al.* Treatment of submacular hemorrhage with tissue plasminogen activator and pneumatic displacement in age-related macular degeneration. *Eur J Ophthalmol* 2021;31(2):643-648.
- Fujikawa M, Sawada O, Miyake T, *et al.* Comparison of pneumatic displacement for submacular hemorrhages with gas alone and gas plus tissue plasminogen activator. *Retina* 2013;33(9):1908-1914.
- McCartney M, Verma N, Traill A. Nd:YAG laser for subhyaloid haemorrhage: a series and observation of treatment outcomes. *Int J Ophthalmol* 2019;12(2):348-350.
- Christodoulou E, Batsos G, Christou EE, *et al.* Long-term outcomes following intravitreal ranibizumab for choroidal neovascularization related to Nd: YAG laser macular injury: a case report. *Case Rep Ophthalmol* 2023;14(1):68-74.
- Kannan NB, Kohli P, Mishra C, *et al.* Surgical management of full-thickness macular hole following Nd: YAG laser hyaloidotomy for pre-macular haemorrhage in a patient with anaemic retinopathy. *BMJ Case Rep* 2022;15(8):e249564.