

Consecutive superior oblique palsy following surgical management of brown syndrome: case series

Hajar Farvardin, Majid Farvardin

Department of Ophthalmology, Poostchi Ophthalmology Research Center, School of Medicine, Shiraz University of Medical Sciences, Shiraz 7134997446, Iran

Correspondence to: Majid Farvardin. Poostchi Ophthalmology Research Center, Zand Avenue, Shiraz 7134997446, Iran. Majidfarvardinjahromi@gmail.com

Received: 2024-03-31 Accepted: 2024-12-24

DOI:10.18240/ijo.2025.06.27

Citation: Farvardin H, Farvardin M. Consecutive superior oblique palsy following surgical management of brown syndrome: case series. *Int J Ophthalmol* 2025;18(6):1178-1180

Dear Editor,

Brown syndrome is an ocular motility disorder characterized by restriction of elevation in adduction combined with a positive forced duction test and minimal or no superior oblique (SO) overaction^[1]. Other features include V-pattern horizontal deviation and palpebral fissure widening while adduction^[1]. Various SO-weakening surgeries have been developed to correct the patient's primary position hypotropia (HOT) and abnormal head posture (contralateral face turn and chin-up position)^[1-2]. Consecutive SO palsy is an important complication that may occur after surgical correction of Brown syndrome^[2-3]. This study discusses the surgical management of three cases with consecutive SO palsy and provides a brief review of this complication in the ophthalmic literature. Additionally, the article will cover the differential diagnosis and surgical management of this complication.

This study was conducted in accordance with the principles of the Declaration of Helsinki, and informed consent was obtained from all subjects. The study was approved and supported by the Institutional Review Board at Shiraz University of Medical Sciences and approved by the ethical committee (Approval number 32044).

Figure 1 shows the flowchart of case selection. Four patients with hypertropia (HT) in the operated eye were identified. Three had consecutive SO palsy, while one developed Brown syndrome in the non-operated eye after surgery.

Case 1: A 5-year-old girl underwent right-side SO tenectomy

and right lateral rectus muscle recession due to congenital Brown syndrome. Before surgery, she had 10 prism diopter (PD) HOT in the primary position, which increased to 15 PD in the side gaze and 40 PD in the contralateral elevation gaze along with V-pattern exotropia. One year after the operation, she had 12 PD HT in the right eye, which increased in the contralateral gaze (18 PD in the left gaze vs 5 PD in the right gaze) combined with a face tilt to the left. She underwent right IO myectomy and left lateral rectus muscle recession to correct iatrogenic SO palsy and residual exotropia. As a result, she achieved orthotropia and her face tilt was resolved.

Case 2: A 7-year-old boy underwent right SO tenectomy due to severe right-side acquired Brown syndrome. He had 8 PD HOT in the primary position which increased to 15 PD in the contralateral gaze and 40 PD in the contralateral elevation. After surgery, he developed 18 PD HT in the operated eye that increased to 22 PD on the left gaze and 25 PD on the left side elevation. Fundus examination revealed macular extorsion in the operated eye. The patient was then treated with a right IO muscle large myectomy. Six months after the second surgery, the patient was found to be orthotropic with no face turn or tilt.

Case 3: A 6-year-old boy was brought to our clinic with a complaint of persistent ocular deviation despite strabismus surgery at the age of 4y. His operation note revealed right-side SO muscle elongation of 8 mm with a silicone band due to right-side Brown syndrome. Postoperative, he had developed right HT of 10 PD in the primary position, which worsened in the contralateral gaze (12 PD) and the ipsilateral tilt (15 PD). He was treated with right IO myectomy due to iatrogenic right-side SO palsy. On his last postoperative visit, he had no ocular deviation and no head tilt.

Case4: A 3-year-old girl was treated with left-side SO elongation 8 mm due to left-side acquired Brown syndrome. Her initial HOT was 8 PD in the primary position which increased to 12 PD in the contralateral gaze and 25 PD in the contralateral elevation. She also had a V-pattern exotropia (25 PD exotropia in up-gaze), a compensatory face turn to the right, and a chin-up head position. One year after the surgery, she presented with 5 PD HOT of the right eye in the primary position which increased to 10 PD in the left gaze and was associated with a moderate under-elevation in adduction. She

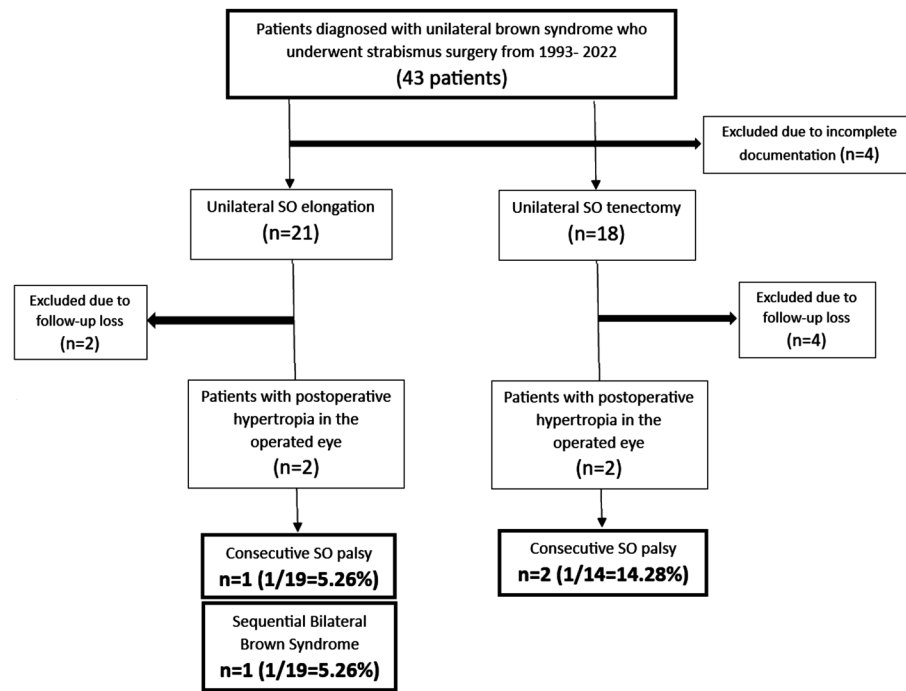


Figure 1 Case selection SO: Superior oblique.

Table 1 Consecutive SO palsy after SO lengthening procedures

Study/year	n (range of HOT)	Surgical treatment	n of consecutive SO palsy (%)	Management of consecutive SO palsy
Wright 1999 ^[3]	15 (0-30 PD)	SO silicone expander surgery (5.5-7 mm)	2/15 (30)	1 patient underwent IO recession
Stager <i>et al</i> , 1999 ^[4]	19 (20 eyes)	SO silicone expander surgery (6-10 mm)	4/19 (21)	4 patients underwent IO weakening
Awad <i>et al</i> , 2003 ^[7]	12 (20-40 PD)	SO silicone expander surgery (10-12 mm)	3/12 (25)	No surgery mild SO palsy (2-4 PD HT)
Suh <i>et al</i> , 2001 ^[5]	3 (0-25 PD)	SO suture spacer surgery (2-8 mm)	1/3 (33)	Prism spectacles in 1 patient
Suh <i>et al</i> , 2008 ^[6]	13 (0-35 PD)	SO adjustable suture spacer surgery (3-8 mm)	4/13 (30.7)	1 patient underwent IO weakening 3 patients experienced detrimental increasing effects over time
Yazdian <i>et al</i> , 2008 ^[8]	25 (5-25 PD)	SO adjustable suture spacer surgery (5-8 mm)	2/25 (8)	Prism spectacles in 1 patient 1 patient underwent suture loosening and SO tendon re-approximation
Moghaddam <i>et al</i> , 2014 ^[10]	15 (10-25 PD)	SO split tendon lengthening (10 mm)	0	-
Awadein <i>et al</i> , 2012 ^[9]	9 (4-20 PD) 6 (4-20 PD)	SO suture spacer surgery (5-8 mm) SO silicone expander surgery (5-7 mm)	0 0	-
Sharma <i>et al</i> , 2018 ^[11]	19	SO adjustable suture spacer surgery (2-7 mm)	6/19 (32)	2 patients underwent scar tissue removal + IO weakening 1 patient underwent IO recession alone 1 patient underwent 5 mm temporal tuck of SO tendon

SO: Superior oblique; IO: Inferior oblique; n: Number of patients; HOT: Hypotropia; HT: Hypertropia; PD: Prism diopter.

underwent right SO elongation with the diagnosis of right-side Brown syndrome and remained orthotropic till her last follow-up.

DISCUSSION

SO weakening procedures are divided into two main groups, SO tenotomy/tenectomy and SO lengthening techniques^[1]. SO lengthening can be performed with a silicone expander, Mersilene suture spacer, autologous expander, split tendon lengthening, and Z-lengthening^[3-11]. SO tenotomy/tenectomy was proven successful in relieving the limitation of elevation in adduction. However, postoperative iatrogenic SO palsy, which occurred in up to 80% of the cases, was a great challenge^[2-3]. Several recommendations were proposed to solve this issue such as performing SO tenotomy near the insertion

or simultaneous IO weakening in the same surgical session^[12]. SO lengthening techniques were later introduced as a novel surgical option carrying a lower risk of iatrogenic SO palsy. The incidence of iatrogenic SO palsy was reported to be up to 33% after different methods of SO lengthening^[3-11]. A summary of consecutive SO palsy cases after SO lengthening procedures is presented in Table 1.

This study reported three cases of iatrogenic SO palsy, two after SO tenotomy (14.2% incidence) and one after SO silicon expander surgery (5.2% incidence). The rate of iatrogenic SO palsy following tenotomy in the current study was lower than previously reported^[2], possibly due to intraoperative surgical variations in the hand of the surgeon. Furthermore, surgery

was limited to patients with severe hypotropia in the primary position. Conservative management is preferred over surgery, particularly for patients with mild HOT in the side gaze, since lower preoperative HOT in the affected side gaze was found to be associated with a higher risk of consecutive SO palsy^[11].

Few reports have discussed the surgical management of consecutive SO palsy following SO weakening in Brown syndrome. Santiago and Rosenbaum^[2] emphasized that surgical correction of this condition is rather challenging due to the complex nature of the palsy. SO tendon re-anastomosis was only successful in one of their cases. Two patients were previously managed through prism correction^[7-8], and seven patients with IO weakening surgeries, including IO recession^[3-4,6,11]. IO weakening combined with scar tissue removal^[11], SO tuck^[11], and SO re-approximation were also reported^[8]. In this study, cases 1, 2, and 3 were successfully managed with IO myectomy, an easy and effective IO weakening procedure.

Bilateral Brown syndrome can have a delayed onset in the second eye^[13]. Therefore, not all cases of postoperative HOT in the non-operated eye following surgical management of a presumably unilateral Brown syndrome are consecutive SO palsy. After unilateral SO weakening surgery, nine individuals were found to develop Brown syndrome in their second eye, as reported in four previous studies^[13-16]. Seemingly we found one patient in our series with sequential presentation of bilateral Brown syndrome who achieved orthotropia after SO weakening of the second eye.

It is crucial to educate patients and their parents about the potential risks that come with performing an SO weakening procedure. These risks include the possibility of consecutive SO palsy, especially after SO tenectomy, and the development of Brown syndrome in the other eye. Simultaneous IO weakening surgery in the same session is not recommended, considering the low incidence of consecutive SO palsy. We found that IO myectomy is a safe and effective surgical option for relieving symptoms in cases of consecutive SO palsy.

ACKNOWLEDGEMENTS

Authors' Contributions: Farvardin H: Data collection, Manuscript preparation. Farvardin M: Study design, Data collection supervision, Manuscript review and editing.

Data Availability: Data will be available upon reasonable request.

Conflicts of Interest: Farvardin H, None; Farvardin M, None.

REFERENCES

- 1 Khorrami-Nejad M, Azizi E, Tarik FF, *et al.* Brown syndrome: a literature review. *Ther Adv Ophthalmol* 2024;16:25158414231222118.
- 2 Santiago AP, Rosenbaum AL. Grave complications after superior oblique tenotomy or tenectomy for Brown syndrome. *J AAPOS* 1997;1(1):8-15.
- 3 Wright KW. Brown's syndrome: diagnosis and management. *Trans Am Ophthalmol Soc* 1999;97:1023-1109.
- 4 Stager DR, Parks MM, Stager DR, *et al.* Long-term results of silicone expander for moderate and severe Brown syndrome (Brown syndrome "plus"). *J Am Assoc Pediatr Ophthalmol Strabismus* 1999;3(6):328-332.
- 5 Suh DW, Guyton DL, Hunter DG. An adjustable superior oblique tendon spacer with the use of nonabsorbable suture. *J AAPOS* 2001;5(3):164-171.
- 6 Suh DW, Oystreck DT, Hunter DG. Long-term results of an intraoperative adjustable superior oblique tendon suture spacer using nonabsorbable suture for Brown Syndrome. *Ophthalmology* 2008;115(10):1800-1804.
- 7 Awad AH, Digout LG, Al-Turkmani S, *et al.* Large-segment superior oblique tendon expanders in the management of severe congenital Brown syndrome. *J AAPOS* 2003;7(4):274-278.
- 8 Yazdian Z, Kamali-Alamdari M, Ali Yazdian M, *et al.* Superior oblique tendon spacer with application of nonabsorbable adjustable suture for treatment of Brown syndrome. *J AAPOS* 2008;12(4):405-408.
- 9 Awadein A, Gawdat G. Comparison of superior oblique suture spacers and superior oblique silicone band expanders. *J AAPOS* 2012;16(2):131-135.
- 10 Moghadam AA, Sharifi M, Heydari S. The results of Brown syndrome surgery with superior oblique split tendon lengthening. *Strabismus* 2014;22(1):7-12.
- 11 Sharma M, MacKinnon S, Zurkowski D, *et al.* Consecutive superior oblique palsy after adjustable suture spacer surgery for Brown syndrome: incidence and predicting risk. *J AAPOS* 2018;22(5):335-339.e2.
- 12 Eustis HS, O'Reilly C, Crawford JS. Management of superior oblique palsy after surgery for true Brown's syndrome. *J Pediatr Ophthalmol Strabismus* 1987;24(1):10-16.
- 13 Kraft SP, Nabi NU, Wilson ME, *et al.* Bilateral idiopathic Brown's syndrome with delayed onset in the second eye. *J AAPOS* 2000;4(3):158-163.
- 14 Sekeroğlu HT, Türkçüoğlu P, Sanaç AŞ, *et al.* Sequential presentation of bilateral brown syndrome. *J AAPOS* 2012;16(2):210-212.
- 15 Osigian CJ, Cavuoto KM, Kothari N, *et al.* Sequential congenital and acquired presentation of bilateral Brown syndrome. *J AAPOS* 2017;21(3):238-238.e1.
- 16 Bagheri A, Abbasnia E, Abrishami A, *et al.* Sequential presentation of bilateral brown syndrome: report of a case with an interesting imaging finding. *J Curr Ophthalmol* 2021;33(2):201-204.