

***Klebsiella pneumoniae* endophthalmitis following central retinal artery occlusion**

Huang–Yi Lei¹, Feng Jiang², Zheng–Gao Xie¹

¹Department of Ophthalmology, Nanjing Drum Tower Hospital, Clinical College of Nanjing Medical University, Nanjing 210000, Jiangsu Province, China

²Department of Ophthalmology, Nanjing Drum Tower Hospital, the Affiliated Hospital of Nanjing University Medical School, Nanjing 210000, Jiangsu Province, China

Correspondence to: Zheng-Gao Xie. Department of Ophthalmology, Nanjing Drum Tower Hospital, the Affiliated Hospital of Nanjing University Medical School, No.321, Zhongshan Road, Gulou District, Nanjing 210000, Jiangsu Province, China. zgxie87@163.com

Received: 2025-01-14 Accepted: 2025-03-21

DOI:10.18240/ijo.2025.07.25

Citation: Lei HY, Jiang F, Xie ZG. *Klebsiella pneumoniae* endophthalmitis following central retinal artery occlusion. *Int J Ophthalmol* 2025;18(7):1401-1404

Dear Editor,

Central retinal artery occlusion (CRAO) is a devastating ocular event caused by obstruction of the central retinal artery, leading to a sudden and significant loss of vision. A hallmark of CRAO on funduscopic examination is a characteristic “cherry-red spot” at the fovea surrounded by a pale retina^[1]. The anterior segment typically appears unremarkable. CRAO is often associated with underlying medical conditions, including cardiovascular diseases (e.g., atherosclerosis, hypertension), hypercoagulable states, inflammatory conditions and metabolic disorders^[1-2]. Endogenous *Klebsiella* endophthalmitis (KE) is a severe intraocular infection with a poor visual prognosis. KE typically presents with decreased visual acuity, marked conjunctival redness and swelling, anterior chamber inflammation (hypopyon) and vitritis^[3]. Retinal vascular involvement has been reported in KE, such as subretinal abscess with hemorrhage^[4]. In the last 30y, liver abscesses due to *Klebsiella pneumoniae* infections have increased. Liver disease patients may experience abnormal blood clotting and endogenous endophthalmitis (EE), potentially causing choroidal vessel hemorrhages as bacteria reach the retina through the choroid^[3]. Endotoxins released by

the bacteria may stimulate the proliferation of macrophages, leading to the production of inflammatory mediators that can disrupt microvascular function and potentially contribute to vascular occlusion.

We present a case in which the patient initially exhibited painless visual impairment, with no systemic signs of infection and no family history of liver disease or diabetes. After a diagnosis of CRAO, the patient developed a fulminant progression of infectious symptoms in the right eye and systemically. This report emphasizes the potential for CRAO to serve as an early indicator of severe EE caused by *Klebsiella pneumoniae* infection, highlighting the need for heightened clinical vigilance.

Ethical Approval This study was approved by Ethics Committee of Drum Tower Hospital Affiliated to Nanjing University School of Medicine and adhered to the Declaration of Helsinki (No.2024KY180). Written informed consent was obtained from the patient for publication of this Case Report and any accompanying images.

Case Report A 70-year-old male patient with no remarkable medical history presented to the clinic with a one-hour history of painless vision loss in the right eye. During the ophthalmologic examination, his visual acuity was found to be at the light perception level. His right pupil was fixed and dilated. The intraocular pressures of both eyes were 12.1 and 12.5 mm Hg. Fundoscopic findings were consistent with CRAO, featuring a pale, white retina and a characteristic cherry-red spot (Figure 1A1). The anterior chamber was clear, showing no signs of inflammatory flare or cells.

Optical coherence tomography (OCT) further confirmed the diagnosis of CRAO, as it demonstrated increased thickness of the inner retinal layers (Figure 1A2). The initial management approach included ocular massage and the administration of topical antiglaucoma medications to improve retinal perfusion. The left eye appeared normal, with the exception of a mild nuclear cataract.

The next day, the patient returned to the ophthalmology clinic, complaining of significant discomfort and acute pain in the right eye. The subsequent examination revealed conjunctival and ciliary congestion, along with the presence of anterior chamber cells, flare, and fibrin formation (Figure 1B).

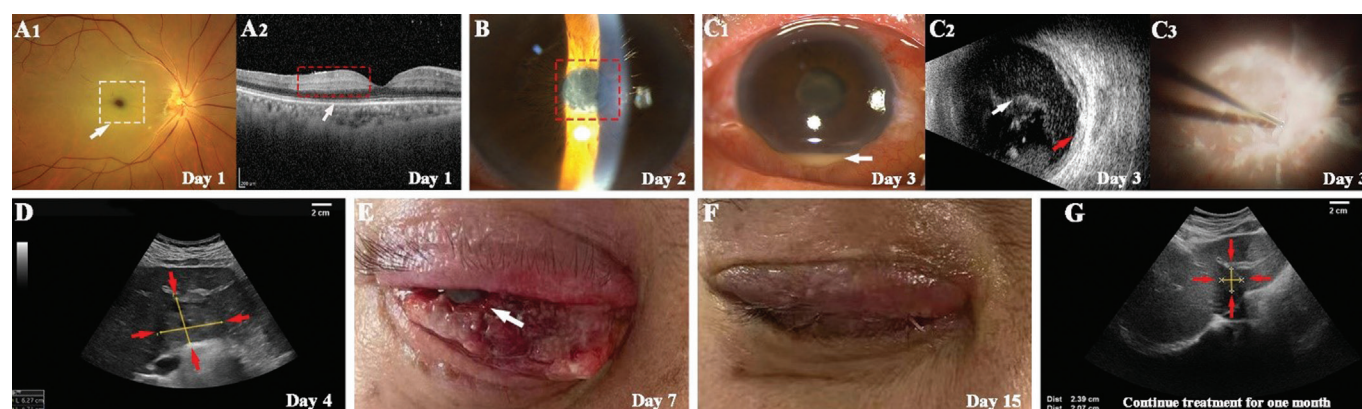


Figure 1 A case of *Klebsiella pneumoniae* endophthalmitis following CRAO A1: On day 1, funduscopy examination of the right eye revealed a cherry-red spot at the macula surrounded by a pale retina (white arrow), a hallmark of CRAO. This indicated significant retinal ischemia and hypoxia. A2: Optical coherence tomography (OCT) scan of the right eye demonstrated increased thickness of the inner retinal layers (white arrow), further confirming the diagnosis of CRAO. B: On day 2, closer view of the anterior chamber showed some fibrin and posterior synechia (red box) which indicated that the infection is beginning to spread. C1: On day 3, anterior segment photographs of the right eye showed marked conjunctival chemosis and hypopyon in the anterior chamber (white arrow); C2: Ultrasound B-Scan of the right eye showed dense opacity in entire vitreous (white arrow) and thickened chorio-retinal complex (red arrow), indicating vitreous exudates; C3: During the vitrectomy surgery, extensive superficial retinal exudates and vascular occlusion were visible, demonstrating the severity of retinal damage caused by the infection. D: On day 4, abdominal color Doppler ultrasound examination performed a 6.27 cm×4.74 cm complex mass in the right lower hepatic lobe (red arrow) which suggested a potential source of the bacterial infection causing endogenous endophthalmitis. E: On day 7, the infection had triggered corneal melting at the nasal scleral site (white arrow), a severe complication of endogenous endophthalmitis that risks globe perforation. F: On day 15, after removing the damaged eye through evisceration, the patient's right eye showed markedly reduced eyelid swelling and conjunctival congestion, indicating a significant decrease in inflammation. G: One month after discharge, abdominal color Doppler ultrasound examination showed improvement in the previously identified liver abscess area (red arrow) which suggested successful treatment of the underlying infection. CRAO: Central retinal artery occlusion.

The patient was diagnosed with EE in the right eye, as indicated by the presence of hypopyon and severe vitritis (Figure 1C1-1C2). A physical examination of the heart, lungs, and abdomen showed no abnormalities. Additionally, the patient denied having a family history of liver disease and diabetes.

Upon admission, the patient immediately underwent emergency phacoemulsification, aspiration, and vitrectomy (VIT). To start, the infusion line was sealed, and a 1 mL syringe was attached to the suction port of the VIT system. The VIT probe was then carefully positioned at the mid-periphery of the vitreous cavity to obtain a small vitreous specimen. Subsequently, approximately 0.3 mL of undiluted vitreous sample was manually extracted. This sample was promptly sent for Gram staining, as well as bacterial and fungal cultures. During the operation, vancomycin and ceftazidime were administered, followed by silicone oil injection. Intraoperative findings showed extensive retinal necrosis and vascular occlusion (Figure 1C3).

After the surgery, the postoperative antibiotic therapy was initiated with vancomycin 1.0 g every 12h and ceftazidime 2.0 g every 12h. Laboratory results from the blood culture indicated a state of inflammation and liver impairment:

white blood cell count of $9.1 \times 10^9/L$; C-reactive protein (CRP) level of 100.37 mg/L (normal range: 0–6 mg/L); procalcitonin 4.61 ng/mL (normal range: 0–0.5 ng/mL); alanine aminotransferase 69.9 U/L (normal range: 5–40 U/L); aspartate aminotransferase 53.4 U/L (normal range: 8–40 U/L); alkaline phosphoric acid 41.8 U/L (normal range: 45–125 U/L); γ -glutamyl aminotransferase 238 U/L (normal range: 10–60 U/L). The D-dimer level was markedly elevated at 3.28 mg/L (normal range: 0–0.5 mg/L), well above the normal range, while the fibrinogen level, an additional marker of hypercoagulability, was also elevated at 4.8 g/L (normal range: 2–4 g/L). Fasting blood glucose and glycated hemoglobin (HbA1c) was normal as 6.17 mmol/L and 5.4%, respectively.

Chest and abdominal computed tomography (CT) scans revealed a 59 mm multilocular mass and multiple patchy slightly low-density shadows in liver along with multiple pulmonary nodules. Abdominal color Doppler ultrasound examination revealed several mixed echo areas in the liver, with varying sizes. The largest lesion was 62.7 mm×47.4 mm in size and had an elliptical shape, with uneven distribution of internal echoes (Figure 1D).

On the third day after surgery, the vitreous culture confirmed the diagnosis of endophthalmitis caused by *Klebsiella*

pneumoniae. Based on the advice from the Infectious Disease Department, the patient's antibiotic regimen was adjusted. Meropenem 1.0 g was prescribed every 8h, and cefotaxime 1 g was given every 12h.

An attempt was made to perform a percutaneous liver puncture under ultrasound guidance, but no fluid could be drained. Blood cultures also turned out negative.

However, the patient's blood test results still indicated a severe infection: white blood cell count of $13.4 \times 10^9/L$; CRP level of 115.68 mg/L (normal range: 0–6 mg/L); procalcitonin 3.04 ng/mL (normal range: 0–0.5 ng/mL); alanine aminotransferase 58.4 U/L (normal range: 5–40 U/L); aspartate aminotransferase 37 U/L (normal range: 8–40 U/L); alkaline phosphoric acid 138.5 U/L (normal range: 45–125 U/L); γ -glutamyl aminotransferase 209.9 U/L (normal range: 10–60 U/L).

On the seventh day, due to the progressive corneal melting at the nasal scleral site and the loss of light perception (Figure 1E), the patient underwent evisceration of the right eye. The evisceration successfully removed all uveal tissue while preserving the intact scleral shell. Post-operatively, the patient reported significant improvement in their condition with substantial reduction in right eyelid swelling and conjunctival congestion (Figure 1F).

The patient's blood test results also showed remarkable improvement: white blood cell count of $5.2 \times 10^9/L$; CRP level of 1.16 mg/L (normal range: 0–6 mg/L); procalcitonin 0.26 ng/mL (normal range: 0–0.5 ng/mL); alanine aminotransferase 32.7 U/L (normal range: 5–40 U/L); aspartate aminotransferase 17.9 U/L (normal range: 8–40 U/L); alkaline phosphoric acid 198.4 U/L (normal range: 45–125 U/L); γ -glutamyl aminotransferase 88.3 U/L (normal range: 10–60 U/L).

The patient was discharged on the fifteenth day. A follow-up abdominal ultrasound performed 1mo later demonstrated improvement of the liver abscess (Figure 1G).

EE is a severe ocular infection often linked to systemic sepsis, with *Klebsiella pneumoniae* implicated in 55.8% of EE cases in Chen *et al*'s study^[5]. This opportunistic pathogen, typically residing in the gastrointestinal tract, can invade the bloodstream or tissues in immunocompromised individuals^[6]. In this case, the patient had no history of metabolic disorders or recent invasive procedures but experienced significant psychological stress, potentially disrupting immune function. The pathogenesis of CRAO involves atherosclerosis, thrombosis, and embolism. *Klebsiella pneumoniae* may contribute to atherosclerosis by promoting endothelial dysfunction, lipid accumulation, and inflammatory cell infiltration. Inflammatory mediators from bacterial infection can exacerbate vascular inflammation, increasing CRAO risk^[7]. A proposed mechanism is that immune dysregulation damages

the retinal microvasculature, compromising the blood-retina barrier and allowing bacterial translocation, potentially triggering CRAO and EE^[8].

Although no embolic source was detected on fundoscopy and blood cultures were negative, *Klebsiella pneumoniae* was later identified in the vitreous fluid, prompting targeted antibiotic therapy. This case underscores the importance of systemic screening in CRAO patients without traditional risk factors, as early detection of embolic sources can prevent CRAO. Targeting *Klebsiella pneumoniae* and other pathogens linked to atherosclerosis may offer innovative preventive strategies.

Pyogenic liver abscess (PLA), a severe EE complication, is increasingly associated with *Klebsiella pneumoniae*^[9]. Elevated CRP levels may aid PLA diagnosis^[10], though our patient showed no fever or supportive laboratory evidence of PLA.

This patient displayed unique features compared to previously reported cases, which often involved confirmed *Klebsiella pneumoniae* infections or comorbidities such as diabetes. Although ocular symptoms typically indicate an infectious etiology, identifying the pathogen in our patient was difficult based on medical history and initial presentation alone.

This case indicates that CRAO may precede severe EE in *Klebsiella pneumoniae* infection. The absence of hypercoagulability or traditional risk factors points to bacterial-induced microangiopathy as a potential mechanism. Clinicians should suspect systemic infection in patients with significant visual loss, even in the absence of diabetes or abdominal symptoms.

Limitations In this case report, the sample size of patients with EE induced by *Klebsiella pneumoniae* and concurrent CRAO was rather small. As a result, it is of great urgency to collect more similar cases in the future for a more in-depth investigation. The absence of positive results from blood cultures or liver abscess drainage makes it challenging to definitively confirm the *Klebsiella pneumoniae* infection.

ACKNOWLEDGEMENTS

Conflicts of Interest: Lei HY, None; Jiang F, None; Xie ZG, None.

REFERENCES

- 1 Chen CL, Singh G, Madike R, *et al*. Central retinal artery occlusion: a stroke of the eye. *Eye (Lond)* 2024;38(12):2319-2326.
- 2 Ma CH, Wang CY, Dai TT, *et al*. Risk factors of non-arteritic anterior ischaemic optic neuropathy and central retinal artery occlusion. *Int J Ophthalmol* 2024;17(5):869-876.
- 3 Kim E, Byon I, Lee JJ, *et al*. Endogenous endophthalmitis from a klebsiella pneumoniae liver abscess: the incidence, risk factors, and utility of imaging. *Am J Ophthalmol* 2023;252:69-76.
- 4 Al-Kharsan H, Nuesi R. Subretinal and liver abscesses in klebsiella endophthalmitis. *Am J Ophthalmol* 2023;248:e1.

- 5 Chen SC, Lee YY, Chen YH, *et al.* *Klebsiella pneumoniae* infection leads to a poor visual outcome in endogenous endophthalmitis: a 12-year experience in southern Taiwan *Ocul Immunol Inflamm* 2017;25(6):870-877.
- 6 Zysset-Burri DC, Morandi S, Herzog EL, *et al.* The role of the gut microbiome in eye diseases. *Prog Retin Eye Res* 2023;92:101117.
- 7 Liu CL, Sun ZH, Shali S, *et al.* The gut microbiome and microbial metabolites in acute myocardial infarction. *J Genet Genom* 2022;49(6):569-578.
- 8 Çölkesen F, Tarakçı A, Eroğlu E, *et al.* Carbapenem-resistant *Klebsiella pneumoniae* infection and its risk factors in older adult patients. *Clin Interv Aging* 2023;18:1037-1045.
- 9 Mak CY, Ho M, Iu LP, *et al.* Clinical features and treatment outcomes of endogenous *Klebsiella* endophthalmitis: a 12-year review. *Int J Ophthalmol* 2020;13(12):1933-1940.
- 10 Gu L, Ai T, Ye Q, *et al.* Development and validation of a clinical-radiomics nomogram for the early prediction of *Klebsiella pneumoniae* liver abscess. *Ann Med* 2024;56(1):2413923.