

# Clinical presentation of a mixed 23-gauge infusion and 20-gauge pars plana technique for active silicone oil removal

Jian-Qin Lei, An-Ming Xie, Qiang Shi

Department of Ophthalmology, the First Affiliated Hospital of the Medical College of Xi'an Jiaotong University, Xi'an 710061, Shaanxi Province, China

**Correspondence to:** An-Ming Xie. Department of Ophthalmology, the First Affiliated Hospital of the Medical College of Xi'an Jiaotong University, Xi'an 710061, Shaanxi Province, China. xie9102@163.com

Received: 2012-05-30 Accepted: 2012-09-18

## Abstract

- **AIM:** To present with a clinical case series of a mixed 23-gauge infusion and 20-gauge pars plana technique for 5,700-centipoise silicone oil removal (SOR), and to discuss its efficacy and safety.
- **METHODS:** This is a retrospective, non-randomized controlled study. We performed SOR with 23-gauge infusion and 20-gauge active suction technique on 29 patients 29 eyes from April to October, 2011 (mixed group). During the surgeries, a 23-gauge sclerotomy was made for infusion and a 20-gauge sclerotomy was used for active silicone oil suction. Anterior segment optical coherence tomography (OCT) was applied for 23-gauge sclerotomy analysis 1 day post-operation. Traditional 20-gauge SOR was performed on another consecutive 29 patients 29 eyes, the control group (20G group).
- **RESULTS:** There were 2 eyes (6.9%) in mixed group and 5 eyes (17.2%) in 20G group which had recurrent retinal detachment after surgery. Hypotony (IOP $\leq$  6mmHg) occurred in 8 eyes (27.6%) of mixed group and in 10 eyes (34.5%) of 20G group post-operation, but all of them recovered to the normal level finally. There were no statistical significant differences. Final visual acuity was significantly increased after surgery in both groups. Anterior segment OCT images were acquired from 13 eyes of mixed group, and all of them had a proper wound apposition. But local ciliary detachment was found in 9 eyes (69%). It was hard to define the OCT image of the sclerotomies and ciliary body because of the serious conjunctival hemorrhages and chemosis in 20G group.
- **CONCLUSION:** This mixed technique is a convenient and effective way to remove high viscosity silicone oil. Compared with traditional 20-gauge SOR, it does not increase the risk of post-operative complications and has less conjunctival

reactions.. Transient postoperative hypotony is common for this procedure and subclinical ciliochoroidal detachment is a probable cause.

• **KEYWORDS:** silicone oil removal; 23-gauge; hypotony

DOI:10.3980/j.issn.2222-3959.2012.05.11

Lei JQ, Xie AM, Shi Q. Clinical presentation of a mixed 23-gauge infusion and 20-gauge pars plana technique for active silicone oil removal. *Int J Ophthalmol* 2012;5(5):600-604

## INTRODUCTION

Silicone oil tamponade is commonly used for complex cases during pars plana vitrectomy. Long term use of silicone oil may lead to complications such as cataract, glaucoma, band keratopathy and toxicity to the retina<sup>[1]</sup>. Therefore, when silicone oil has been inserted, it must be removed later. Several surgical techniques have been introduced to remove the silicone oil<sup>[2-4]</sup>. And it was usually done through a pars plana 20-gauge vitrectomy system in phakic or pseudophakic eyes. More recently, some studies have reported using 23-gauge sutureless vitrectomy system to remove the silicone oil<sup>[5-8]</sup>. Smaller sclerotomies have the advantages of being sutureless, faster and less discomfort. On the other hand, however, larger pressure should be needed to extract the oil since the inner diameter is decreased. Either the infusional bottle height or the active suction pressure is increased to counteract the resistance of the tube. These manipulations may probably increase the risk of optic disc damage or eyeball collapse. And it takes time to remove silicone oil of high viscosity with the technique. Therefore, using a 23-gauge sclerotomy for infusion combined with a 20-gauge sclerotomy for silicone oil removal would be an eclectic method. There are few publications that have reported the outcomes of such technique. In present study, we performed a retrospective non-randomized controlled study of using mixed 23-gauge infusion and 20-gauge active suction technique for removing 5,700-centipoise silicone oil.

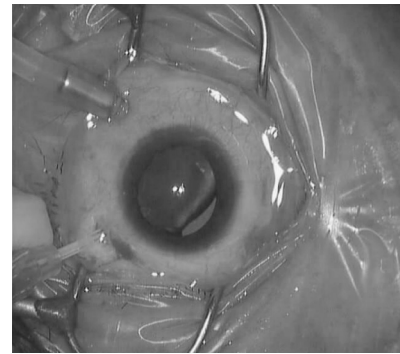
## SUBJECTS AND METHODS

**Subjects** We retrospectively reviewed 29 patients 29 eyes who had undergone silicone oil removal (SOR) with mixed 23-gauge infusion and 20-gauge active suction technique

(mixed group) from April to October, 2011. Meanwhile, another consecutive 29 patients 29 eyes who had traditional 20-gauge SOR in 2011 were set as controls (20G group). Surgeries combined with trabeculectomy were excluded. All patients had previously been treated with pars plana vitrectomy and 5700-centipoise silicone oil tamponade. In addition to general ophthalmic examinations, three-mirror lens examination was routinely performed before silicone oil removal. Anterior segment OCT (Visante, Carl Zeiss) of the inferotemporal sclerotomy was acquired 1 day post-operation. The follow-up period was at least 3 months.

Information obtained by reviewing the medical records of each patients included 1) age, 2) sex, 3) primary diagnosis before the silicone oil tamponade surgery was performed, 4) diagnosis before silicone oil removal surgery, 5) the duration of silicone oil remaining in the eyes, 6) best corrected visual acuity (BCVA) before silicone oil removal and at the last follow-up, 7) intraocular pressure (IOP) before operation, at 1 day post-operation and at the last follow-up, 8) axial length obtained either by IOL master (Carl Zeiss) or by A-mode ultrasonic scanning when the refractive substances was not clear enough.

**Methods** Retrobulbar anesthesia was performed in all surgeries. In mixed group, a 23-gauge cannula was placed using one-step technique at inferotemporal region 3.5mm posterior to the limbus for setting up the infusion line (Alcon 23-gauge system). The conjunctiva was displaced slightly at the incisional site, and a spear shaped trocar was inserted tangential to the limbus at an angle of 10 degrees. After advancing the trocar for about 2mm within the sclera, the angle was changed to 30 degree to complete the incision. If there was no need for intraocular manipulations during the operation, only 2 sclerotomies were made. One was made at superonasal or superotemporal part at the surgeon's convenience and a 20-gauge incision was made on the scleral 3.5mm behind the limbus. Then, a 20-gauge cannula connected to a 10mL syringe was applied to actively aspirate the silicone oil using Accorus vitrectomy system (Alcon) with a negative pressure of 500mmHg (Figure 1). After removing the silicone oil, an illuminating line was put through the 20-gauge incision to check the fundus contact lenses. When the surgery was combined with epi-retinal membrane peeling or other intraocular manipulations, another 23-gauge cannular was set up for illumination. Then, a partial air-fluid exchange was repeated for several times to clear residual small oil bubbles. At last, the 20-gauge incision was closed with one mattress suture and the 23-gauge cannular was removed with pressing the sclerotomy for about 30 seconds. If leakage or hypotony was found at the endpoint of the surgery, one or two sutures with 8-0 absorbable line were applied to close the incision (s) and finally, the IOP was adjusted to normal level. In 20G group, the conjunctiva should first be opened where the



**Figure 1** A 20-gauge cannula connected to a 10mL syringe was applied to actively aspirate the silicone oil using Accorus vitrectomy system(Alcon) with a negative pressure of 500mmHg.

sclerotomies were made with a MVR blade (0.89mm). One prepared mattress suture was made on the inferotemporal sclera with 6-0 absorbable line before the 20-gauge infusion line was set up. Active SOR was also performed through a 20-gauge sclerotomy. Similarly, when intraocular manipulation was not needed, only 2 sclerotomies were made. And fundus was also routinely checked with intraocular illumination after silicone oil was taken out. Finally, all the incisions were sutured and the prepared mattress suture was tightened simultaneously when the infusion line was removed. All the surgeries were performed by two doctors (Dr. Xie A. & Dr. Lei J.).

**Statistical Analysis** SPSS version 13.0 was used for statistical analysis. A  $P$  value  $<0.05$  was considered statistical significance. Snellen visual acuity was converted to logarithm of the minimal angle of resolution (logMAR) for statistical analysis. Visual acuity of counting fingers and hand motions were arbitrarily assigned an equivalent of 2.3 logMAR and 2.6logMAR units, respectively. The paired-sample- $t$  test was used to compare the BCVA, IOP before and after operation. To compare between mixed group and 20G group, one-way ANOVA was used for numerical variables, and Chi-square test was used for categorical variables. Bivariate correlations were used to find if post surgical hypotony was related with primary diagnosis, axial length, type of surgery and post-operative intraocular hemorrhage.

## RESULTS

The mixed group included 29 eyes of 29 patients. There were 21 men and 8 women, whose mean age was  $(49.97 \pm 16.8)$  years old, ranging from 7 to 78 years old. Primary diagnosis at the time of silicone oil tamponade were rhegmatogenous retinal detachment in 17 eyes (58.6%), among which, 8 eyes had proliferative vitreoretinopathy (PVR  $\geq$  grade C1) or recurrent retinal detachment. Five eyes (17.2%) suffered from proliferative diabetic retinopathy with tractional detachment of retina. Three eyes (10.3%) had retinal vasculitis with proliferative retinopathy. Three eyes (10.3%) had ocular trauma involving posterior segment

**Table 1 Comparison between mixed 23-gauge and 20-gauge silicone oil removal and traditional 20-gauge silicone oil removal**

Variables group	Mixed 23- and 20-gauge (n=29)	20-gauge group (n=29)	$\bar{x} \pm s$ (range)	P
Age (years)	49.97±16.88 (7-78)	49.62±15.39 (19-83)		0.935
Axial length (mm)	25.53±2.69 (22.00-31.19)	25.82±2.14 (23.40-30.12)		0.645
Oil duration (mo)	11.16±13.76 (3.3-72.0)	10.41±7.71 (3.0-36.0)		0.801
Pre VA (log MAR)	1.52±0.66 (0.4-2.6)	1.47±0.58 (0.6-2.6)		0.737
Last VA (log MAR)	1.22±0.68 (0.1-2.6)	1.22±0.56 (0.4-2.6)		0.983
Pre IOP (mmHg)	17.8±5.6 (10-39)	16.5±7.3 (10-50)		0.458
IOP at day1 (mmHg)	8.9±3.9 (4-20)	9.7±5.0 (4-20)		0.493
Last IOP (mmHg)	16.5±3.6 (11-26)	15.4±3.2 (11-24)		0.230
Males n(%)	21 (72.4)	18 (62.1)		0.576
Combined IOL implant	14 (48.3)	16 (55.2)		0.793
Combined EMM peeling	7 (24.1)	4 (13.8)		0.504
Hypotony	8 (27.6)	10 (34.5)		0.777
Recurrent RD	2 (6.9)	5 (17.2)		0.423
Hemorrhage	6 (20.7)	3 (10.3)		0.470

and 1 (3.4%) eye was diagnosed of hemorrhagic choroidal detachment and secondary retinal detachment.

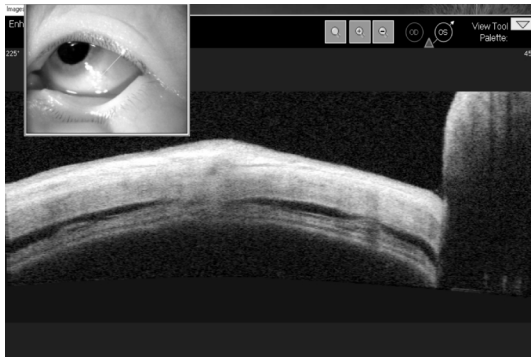
The 20G group also included 29 eyes of 29 patients. There were 18 men and 11 women, whose mean age was (49.62±15.4) years old, ranging from 19 to 83 years old. Primary diagnosis at the time of silicone oil tamponade were rhegmatogenous retinal detachment in 13 eyes (44.8%), among which, 7 eyes had proliferative vitreoretinopathy (PVR ≥ grade C1) or recurrent retinal detachment. Seven eyes (24.1%) suffered from proliferative diabetic retinopathy with tractional detachment of retina. Seven eyes (24.1%) had ocular trauma involving posterior segment and 2 (6.9%) eye was diagnosed branch retinal vein occlusion complicated with vitreous hemorrhage and retinal detachment. The outcomes of comparison between mixed group and 20G group were listed in Table 1. One-way ANOVA showed that there was no significant difference between the two groups in age, axial length, duration of silicone oil remaining the eyes, BCVA before and after the surgeries, IOP pre-operation, at day 1 post-operation and at the last follow-up. And Chi-square test also showed no significant difference in gender, if combined with IOL implant, if combined with EMM peeling, and also in post-operative complications including recurrent retinal detachment, hypotony and intraocular hemorrhage.

No serious intra-operative complication occurred in any of the eyes. However, 2 eyes in mixed group developed serous choroidal detachment when the silicone oil was almost cleared out and regressed soon after the 23-gauge infusion line was changed to a traditional 20-gauge one. In mixed group, 8 eyes had incisional site leakage and hypotony after removal of the 23-gauge infusion line and additional sutures was applied to close the incisions in these eyes.

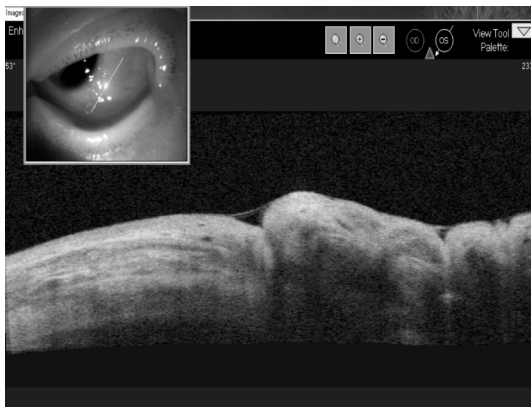
In both groups, logMAR visual acuity at the last follow up

was significantly better than that before SOR. The post-operative IOP at the first day was significantly decreased in both groups, but the IOP at the last follow up had no significant difference compared with that of pre-operation. Eight eyes (27.6%) in mixed group and 10 eyes (34.5%) in 20G group developed hypotony (IOP ≤ 6mmHg) at the first day of post operation, but all recovered to normal level (IOP ≥ 11mmHg) at the last follow-up. Other post-operative complications included anterior chamber or vitreous hemorrhage in 6 eyes (20.7%) of mixed group and 3 eyes (10.3%) of 20G group. All of them were mild and resolved spontaneously within 2 weeks. Two eyes (6.9%) in mixed group and 5 eyes (17.2%) in 20G group had recurrent retinal detachment. However, none of the incidence of the post-operative complications above had significant difference between the two groups. One eye in mixed group developed macular hole after EMM peeling which was proved by spectral domain OCT (cirrus, Zeiss) after surgery. No post operative suprachoroidal hemorrhage, endophthalmitis or intraocular lens dislocation occurred.

In the correlation study, post-operative hypotony did not correlate with post operative intraocular hemorrhage. Nor did it correlate with axial length, primary diagnosis or combined IOL implant. Only 13 of 29 eyes in mixed group had successfully acquired an anterior segment OCT image of the 23-gauge sclerotomy at the first day post-operation. Proper wound apposition had been found in all the 13 eyes. Local ciliary detachment (Figure 2) was documented in 9 eyes (69%). Ciliary detachment was found in all the eyes with hypotony and an OCT image. However, since the sample was too small, there was no significant correlation between hypotony and ciliary detachment. It was hard to define the OCT image of the sclerotomies and ciliary body because of the serious conjunctival hemorrhages and chemosis in 20G group. (Figure 3).



**Figure 2** Local ciliary detachment was documented in 9 eyes (69%).



**Figure 3** It was hard to define the OCT image of the sclerotomies and ciliary body because of the serious conjunctival hemorrhages and chemosis in 20G group.

## DISCUSSION

SOR is one of the most common procedures in vitreoretinal surgery. A lot of methods have been designed for it. And no matter which method was used, the primary goal is to remove the oil as completely as possible while avoiding complications. Secondary aims include time efficiency and surgical simplicity<sup>[3]</sup>. In present study, the mixed 23-gauge infusion and 20-gauge active suction technique for SOR had several merits. On one hand, it could shorten the time duration for the operation, relieve conjunctival reactions and bring less discomfort to the patients after surgery. Since there's no need for sutures to stabilize the infusion line and it also decreased the sutures on sclera and conjunctiva. On the other hand, one 20-gauge sclerotomy was still created for active SOR in order to facilitate clearing all the oil bubbles without compromise its efficiency. Therefore, this technique would be a convenient and practical way for SOR. And to the best of our knowledge, no one has reported the same technique before.

The first complete 23-gauge vitrectomy system was introduced in 2005 and is judged to be safe and efficient<sup>[9]</sup>. It affords transconjunctival sutureless access, and thus shortened surgical time and fastened patient rehabilitation. Patwardhan *et al*<sup>[5]</sup> reported using three port 23-gauge transconjunctival system for passive removal of 1,000 centistoke silicone oil. However, it would be too time

consuming to remove high viscosity silicone oil. Song *et al*<sup>[6]</sup> reported an active way of removing 5,000-centistoke silicone oil through a three-port 23-gauge system. However, special equipment should be connected to the cannular to facilitate the active suction. In our study, we described a technique which can be applied to remove silicone oil of different viscosity with aphakia, pseudophakia or phakia. The whole procedure was quick and simple compared with a standard 20-gauge silicone oil removal technique and was also less expensive than a three-port 23-gauge system. In 22 eyes of mixed group, intraocular manipulation was unnecessary and a two-port silicone oil removal technique was used which was even simpler and faster. No serious complication occurred during or after operations and visual acuity increased significantly. However, one disadvantage of two-port technique was that a small area of the fundus could not be perceived during the surgery. But the incidence of recurrent retinal detachment was tolerable (4.5%, 1/22). Tan *et al*<sup>[2]</sup> have compared the results of silicone oil removal between a two-port and a three-port approach and the retinal redetachment rate and there was no significantly difference. However, in one retrospective study of Guo *et al*<sup>[10]</sup>, the incidence of recurrent RD was significantly higher in 2-port SOR than that in 3-port SOR.

Among all the possible post-operative complications, recurrent retinal detachment is the major concern. The reported incidence of recurrent rate in 20-gauge surgery was nearly 20%<sup>[11-13]</sup>. In our study, the incidence of recurrent RD was 6.9% in mixed group and 17.2% in 20G group. Although the difference was not statistically significant, it at least suggested that this technique would not increase the risk for recurrent RD. And what's more, we think it is important to perform a thorough fundus check before and during the surgery for predicting and avoiding retinal redetachment.

Post surgical hypotony was another common complication after SOR. The incidence of hypotony was 27.6% in mixed group and 34.5% in 20G group. The latter was a little bit higher than the former, but without statistical significance. This suggested that our new technique would not increase the risk of post-operative hypotony. In Song's study of 23-gauge silicone oil removal, the incidence of post operative hypotony was 23.5%<sup>[6]</sup> which was comparable to our study. And he postulated that wound leakage was a probable reason. Kim *et al*<sup>[14]</sup> reported even higher incidence of hypotony (39.3%) using a standard 20-gauge three-port system for silicone oil removal. While in the studies of 23-gauge vitrectomy, the reported incidence of hypotony ranged only from 0% to 3.8%<sup>[15-17]</sup>. In this study, although wound leakage had been checked and handled and the IOP had reached to a normal level before finishing the operation, IOP still significantly decreased at day 1 post operation. An obvious ciliary detachment around 23-gauge sclerotomy

could be found by anterior segment OCT in eyes with hypotony. Thus, we postulated that liquid might enter the supraciliary space through the inner opening of the incision and led to subclinical ciliochoroidal detachment. The reported incidence of hypotony in primary 23-gauge vitrectomy was much lower than that of silicone oil removal. One possible explanation is that peripheral vitreous incarceration may help to prevent wound leakage or ciliochoroidal detachment. Although the incidence of hypotony was high in our study, they were all self-limited and were not associated with post-surgical vitreous or anterior chamber hemorrhage. In two risk factor studies<sup>[14,15]</sup>, myopia and long axial length have been found to be associated with postoperative hypotony in both 23-gauge vitrectomy and 20-gauge silicone oil removal. This association was not confirmed in our study, but a larger sample would be needed for risk analysis.

In the mixed group, serous choroidal detachment occurred in 2 eyes when the silicone oil was almost cleared out. In both cases, the 23-gauge infusion line was removed and was changed to a standard 20-gauge infusion line at the same position. And the choroidal detachment regressed soon after this manipulation. Neither of the eyes had choroidal detachment after surgery examined by indirect ophthalmoscopy. This suggested that the 23-gauge cannula was retracted from the sclerotomy during the surgery. Tarantola *et al*<sup>[18]</sup> had a review of intraoperative choroidal detachments during 23-gauge vitrectomy and examined possible mechanisms involved. And they proposed that infusion cannula retraction is an important mechanism and a risk factor.

Taban *et al*<sup>[19]</sup> has first reported using anterior segment OCT to evaluate *in vivo* wound closure characteristics of sclerotomies after sutureless 23-gauge vitrectomy. However, no one has reported on that after silicone oil removal surgery. In present study, anterior segment OCT demonstrated a high incidence (69%) of ciliary detachment around 23-gauge sclerotomy after silicone oil removal. In another study of 23-gauge sclerotomies using OCT, local ciliochoroidal detachment was found in 4 of 35 (11.4%) eyes<sup>[20]</sup>. If the high incidence of ciliary detachment was associated with 23-gauge sclerotomies or silicone oil removal surgery, prospective and larger sample studies would still be needed.

In conclusion, this mixed 23-gauge infusion and 20-gauge active suction technique is a convenient and effective way of removing silicone oil of high viscosity. This technique does not increase the risk of post-operative complications compared to traditional 20-gauge SOR. However, attentions should still be paid to the leakage of 23-gauge incisions and associated complications. Transient post-operative hypotony is common for this procedure and subclinical ciliochoroidal detachment is a probable cause.

## REFERENCES

- 1 Herbert EN, Habib M, Steel D, Williamson TH. Central scotoma associated with intraocular silicone oil tamponade develops before oil removal. *Gracfs Arch Clin Exp Ophthalmol*2006;244(2):248–252
- 2 Tan HS, Dell'omo R, Mura M. Silicone oil removal after rhegmatogenous retinal detachment: comparing techniques. *Eye (Lond)*2012;26(3):444–447
- 3 Tsui I, Reddy S, Hubschman JP. An elementary and effective method for silicone oil removal. *Retina*2010;30(3):524–526
- 4 Immonen I, Vuorinen R, Tommila P. A simple and inexpensive system for the removal of silicone oil through a 20-gauge opening. *Retina*1995;15(3):263–264
- 5 Patwardhan SD, Azad R, Shah V, Sharma Y. The safety and efficacy of passive removal of silicone oil with 23-gauge transconjunctival sutureless system. *Retina*2010;30(8):1237–1241
- 6 Song ZM, Chen D, Ke ZS, Wang RH, Wang QM, Lu F, Qu J. A new approach for active removal of 5,000 centistokes silicone oil through 23-gauge cannula. *Retina*2010;30(8):1302–1307
- 7 Cekiç O, Cakir M, Yilmaz OF. Passive silicone oil removal in 23-gauge tranconjunctival vitrectomy. *Ophthalmic Surg Lasers Imaging*2011;42(6):514–515
- 8 Abouammoh MA, Yeung J, Gale JS. Sutureless silicone oil removal: a quick and safe technique. *Retina*2012;32(2):396–398
- 9 Eckardt C. Transconjunctival sutureless 23-gauge vitrectomy. *Retina*2005;25(2):208–211
- 10 Guo CM, Wang YS, Hui YN. Analysis of the complications of two kinds of silicone oil removal. *Int J Ophthalmol*2008;11(1):167–170
- 11 Hutton WL, Azen SP, Blumenkranz MS, Lai MY, McCuen BW, Han DP, Flynn HW Jr, Ramsay RC, Ryan SJ. The effects of silicone oil removal. Silicone Study Report 6. *Arch Ophthalmol*1994;112(6):778–785
- 12 Jiang F, Krause M, Ruprecht KW, Hille K. Risk factors for anatomical success and visual outcome in patients undergoing silicone oil removal. *Eur J Ophthalmol*2002;12(4):293–298
- 13 Goezinne F, La Heij EC, Berendschot TT, Liem AT, Hendrikse F. Risk factors for redetachment and worse visual outcome after silicone oil removal in eyes with complicated retinal detachment. *Eur J Ophthalmol*2007;17(4):627–637
- 14 Kim SW, OH J, Yang KS, Kim MJ, Rhim JW, Huh K. Risk factors for the development of transient hypotony after silicone oil removal. *Retina*2010;30(8):1228–1236
- 15 Woo SJ, Park KH, Hwang JM, Kim JH, Yu YS, Chung H. Risk factors associated with sclerotomy leakage and postoperative hypotony after 23-gauge transconjunctival sutureless vitrectomy. *Retina*2009;29(4):456–463
- 16 Parolini B, Prigione G, Romanelli F, Cereda MC, Sartore M, Pertile G. Postoperative complications and intraocular pressure in 943 consecutive cases of 23-gauge transconjunctival pars plana vitrectomy with 1-year follow-up. *Retina*2010;30(1):107–111
- 17 Singh CN, Iezzi R, Mahmoud TH. Intraocular pressure instability after 23-gauge vitrectomy. *Retina*2010;30(4):629–634
- 18 Tarantola RM, Folk JC, Shah SS, Boldt HC, Abr à moff MD, Russell SR, Mahajan VB. Intraoperative choroidal detachment during 23-gauge vitrectomy. *Retina*2011;31(5):893–901
- 19 Taban M, Sharma S, Ventura AA, Kaiser PK. Evaluation of wound closure in oblique 23-gauge sutureless sclerotomies with visante optical coherence tomography. *Am J Ophthalmol*2009;147(1):101–107
- 20 Chen D, Lian Y, Cui L, Lu F, Ke Z, Song Z. Sutureless vitrectomy incision architecture in the immediate postoperative period evaluated *in vivo* using optical coherence tomography. *Ophthalmology*2010;117(10):2003–2009