

# Superglue injuries of the eye

*Sagili Chandrasekhara Reddy*

Department of Ophthalmology, School of Medical Sciences, University Sains Malaysia, Kubang Kerian, Kelantan, Malaysia

**Correspondence to:** Sagili Chandrasekhara Reddy. Department of Ophthalmology, UCSI School of Medicine, Bukit Khor, 21600 Marang, Terengganu, Malaysia. Email: profscreddy@gmail.com

Received:2012-05-24 Accepted:2012-07-15

## Abstract

- **AIM:** To report various ocular lesions caused by accidental instillation of superglue.
- **METHODS:** Three cases of ocular injuries are described in children aged 6 years, 3 years and 8 months, following accidental instillation of superglue in the eye.
- **RESULTS:** In the first case there was sticking of eyelashes in the medial 1/3 of eyelids in both eyes. In the second case sticking of eye lashes was present in the lateral 1/3 of eyelids in the left eye. In the third case, superglue was present on the right cheek, above the right ear and sticking of eyelids in medial 1/3 in right eye. The eyelids were separated by pulling the lid margins with fingers in the first case and later on superglue was removed by trimming the eyelashes; and by direct trimming the eyelashes in second and third cases. There was no injury to other structures of anterior segment in the first two cases. However, removal of the superglue on the cornea resulted in corneal abrasion in the third case which healed with medical treatment and patching of the right eye.
- **CONCLUSION:** Accidental instillation of superglue is possible because of the appearance of the tube like eye ointment tube. Immediate medical aid will prevent ocular morbidity.
- **KEYWORDS:** ocular injuries; superglue; sticking of eyelids; corneal abrasion

DOI:10.3980/j.issn.2222-3959.2012.05.18

Reddy SC. Superglue injuries of the eye. *Int J Ophthalmol* 2012;5(5):634-637

## INTRODUCTION

Superglue (a cyanoacrylate adhesive) is easily available in the market and it has become popular choice for domestic use in repairs of broken items, in the craft work, and in cosmetic application of nail tips. It has the ability to

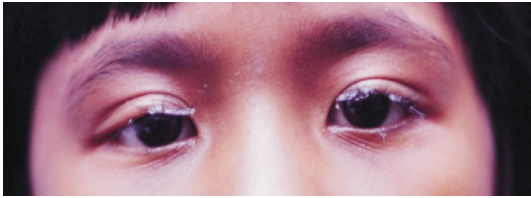bond a variety of objects (metal, plastic, glass, wood, leather etc) in few seconds and keep them together firmly adherent to each other. The widespread repackaging of superglue into dropper bottles resembling eye drops bottles three decades ago has resulted in many cases of inadvertent ocular instillation. Pubmed literature search revealed case reports, letters to editors and retrospective studies [1-16] on superglue injuries of the eye due to inadvertent instillation of superglue drops mistaken for eye drops due to similar appearance of both bottles or due to similar appearance of the superglue tube to the eye ointment tube. All the reports were from the western countries only. This paper describes three cases of superglue injuries of eye in children from Malaysia, with a review of literature on this subject.

## CASE REPORTS

**Case 1** A 6 years old Malay girl was brought to emergency department at 11.30pm with complaints of discomfort and inability to open both eyes for the past two hours following the instillation of some eye ointment by her grand father in both eyes. Her grandfather put the superglue in her both eyes (mistaken as eye ointment by the appearance of the tube) complained irritation in both eyes. On examination, both eyelids were stuck together on the medial 1/3 of the lid margins and child could open the eyes partly. The anterior segment was normal in both eyes. Visual acuity was 6/12 in both eyes.

The condition of both eyes was explained to the parents. An attempt was made to separate the eye lids with fingers using mild force in the emergency department. The eyelashes of the lower lid along with superglue came out and the child could open both eyes completely. The superglue was attached to the upper lid in medial 1/3 in both eyes. Small specks of superglue were seen on both lower lids (Figure 1). Gentamycin eye ointment was applied in both eyes and the child was admitted in the eye ward.

On the following day, eyelid margins were cleaned with acetone (superglue disolvent) but superglue could not be removed. Therefore, trimming of eyelashes was done to remove the superglue (under sedation and topical anaesthesia in the presence of mother holding the hand of the child) in the minor operation theatre. The child was discharged on gentamycin eye ointment at night and followed up after two weeks. Vision improved to 6/6 in both eyes and both eyes were normal. Gentamycin eye ointment was stopped. In the next visit after one month, the eye lashes grew to normal size in both eyes.

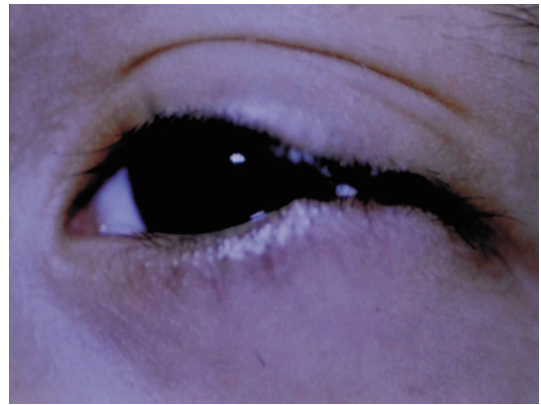


**Figure 1** Showing the superglue on the medial 1/3 of upper lid margins in both eyes after separation of both lids.

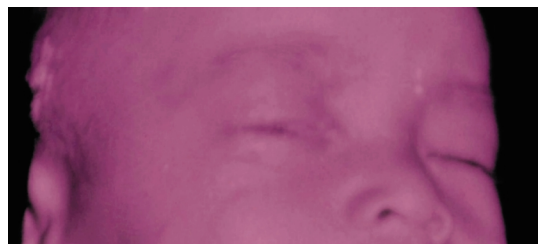**Case 2** A 3 years old Malay boy was brought to the emergency department at 8.00pm with history of inability to open the left eye for the past 3 hours following accidental putting of superglue by himself while playing with glue. On examination, right eye was normal. Both eyelids were stuck together in the lateral 1/3 of the lids (Figure 2), and the child could not open the left eye completely. The anterior segment was normal. Condition of left eye was explained to parents. Parents were informed that removal of superglue is to be done by trimming the eyelashes in the left eye. Gentamycin eye ointment was put in the left eye and the child was admitted in the eye ward. Next day, eyelashes were trimmed under general anaesthesia and gentamycin eye ointment was put in the left eye. The child was discharged on gentamycin eye ointment at night and followed up after two weeks. Left eye was normal. Gentamycin eye ointment was stopped. In the next visit after one month, the eye lashes grew to normal size.

**Case 3** An 8 months old Malay boy was brought to the eye clinic at 12.30pm with the history of inability to open the right eye for the past 2 hours following accidental fall of superglue in the baby's right eye and face when the baby pulled her hand holding the superglue tube while repairing her leather handbag. When her hand was pulled, the superglue was squeezed and the superglue was splashed into the eye accidentally. On examination, superglue was seen on the right cheek and above the right ear. Both lids were stuck together in the medial 1/2 in the right eye (Figure 3). Baby could not open the right eye at all. After separating the lids with fingers, superglue was seen on the lower part of cornea. Mother was explained about the condition of right eye and removal of superglue under general anaesthesia. The baby was admitted in the eye ward and prepared for general anaesthesia.

Under anaesthesia, the glue was found to be attached more to the upper lid margin on the medial side. Eye lashes were trimmed and the eyelids opened completely. Glue was also seen adherent on the medial 1/3 of tarsal conjunctiva, which was peeled off with forceps resulting in conjunctival abrasion. Small layer of glue was attached to the cornea in the lower nasal quadrant which could be peeled off easily with plane forceps resulting in corneal abrasion. Gentamycin eye ointment was put and the eye was patched. The superglue on the right cheek and above the right ear was removed by repeated cleaning with acetone swab.



**Figure 2** Close view of left eye showing superglue on the lower lid margin, upper lid margin and tarsorrhaphy in lateral 1/3 of the lids.



**Figure 3** Showing both eyelids of right eye stuck together with superglue on the medial half; superglue above the right ear, right temple area (white spots).

Next day, the conjunctival abrasion and corneal abrasion were found to be less in size. Cyclopentolate eye drop was put and eye ointment was continued tds in right eye. The conjunctival and corneal abrasions healed completely in two days time. The child was discharged on topical antibiotic eye ointment bd in right eye. The baby was followed up after one week and the right was white and quiet. The antibiotic eye ointment was continued at night time for one more week. In the next visit after one month, the eye lashes grew to normal size in the right eye.

#### **DISCUSSION**

The cause of ocular injuries from the reported cases in the literature was attributed to misidentification by the poorly sighted patients who were prescribed topical eye medications, patient carelessness who confuse the glue for over the counter eye drops, childhood curiosity resulting in accidental splashing of glue into the eyes while playing with the glue containers and deliberate forcible squirting of glue into eyes during assault<sup>[8]</sup>.

Fifty three cases of superglue injuries of the eyes have been published in the literature in the past thirty years. The most common clinical presentation was sticking of eyelids/eyelashes and inability to open the eye. The most common signs were tarsorrhaphy like appearance of the eyelids, conjunctival and corneal abrasion. The management included irrigation of the eye, trimming of eyelashes to remove the superglue attached to the lid margins and

**Table 1 Ocular findings and management of superglue ocular injuries reported in the literature**

Author	n	Ocular findings	Management
Margo & Trobe <sup>[1]</sup>	3	Eyelids stuck together, punctate keratopathy, corneal abrasion, tarsal margin abrasion	Eyelashes cut, irrigation, topical antibiotics, cycloplegics, tarsal separation under irrigation
Morgan & Astbury <sup>[2]</sup>	1	Eyelids stuck together, keratoconjunctivitis	Eyelashes cut, topical antibiotics, eye patch
Raynor <sup>[3]</sup>	1	Eyelids stuck together	Tarsal separation using a wet patch
Silverman <sup>[4]</sup>	1	Corneal abrasion	Topical antibiotics, cycloplegics, eye patch
Lyons <i>et al</i> <sup>[5]</sup>	6	Corneal and conjunctival abrasion, punctate epitheliopathy	Glue removal, mydriatics, topical antibiotics
DeRespinis <sup>[6]</sup>	8	Corneal abrasion, loss of eyelashes, conjunctival inflammation, eyelid skin excoriation	Conservative management, topical antibiotics
Good & McCabe <sup>[7]</sup>	2	Tarsorrhaphy (eyelids stucktogether), corneal abrasion	Surgical separation of eye lids, trimming of eyelashes, topical antibiotics
McClellan <sup>[8]</sup>	14	Eyelashes stuck together, glue on the lids, conjunctivitis, corneal abrasion	eyelashes cut, irrigation, topical antibiotics, conservative management
Rohrbach <i>et al</i> <sup>[9]</sup>	5	Eyelid closure, corneal abrasion	Irrigation, mechanical removal of glue, topical antibiotics
Leibowitz & Levartovsky <sup>[10]</sup>	1	corneal and conjunctival erosions	Topical antibiotics
Knight <sup>[11]</sup>	1	Closure of the eye, temporary Adherence of upper lid to cornea	Conservative management
Mandal <i>et a</i> <sup>[12]</sup>	2	Eyelashes stuck together	Conservative management, topical antibiotics
Needham <i>et al</i> <sup>[13]</sup>	2	Partial tarsorrhaphy, eyelashclumping, corneal abrasion, misdirection of eyelashes	Mechanical removal of glued eyelashes, topical antibiotic
Spencer & Clark <sup>[14]</sup>	2	Ttarsorrhaphy (lid margins stuck together), corneal abrasion	surgical separation of eyelids, topical antibiotics
Desai <sup>[15]</sup>	3	Eyelid closure, corneal abrasion	Conservative management
Yusuf & Patel <sup>[16]</sup>	1	Eyelids stuck together, corneal Abrasion	Glue removal, topical antibiotics, cycloplegics
Present Study	3	Eyelashes stuck together, corneal abrasion	Separation of lids by trimming of eyelashes, topical antibiotics

removal of the glue with forceps from the conjunctiva and cornea. The corneal abrasion was treated with topical antibiotics, mydriatics/cycloplegics and eye patching. In some cases conservative management was given i.e. antibiotic eye drops and allowing the glue to fall off by itself over a period of few days (Table 1). No serious ocular morbidity has been reported due to superglue injury. The age of patients varied from 3 months to 64 years and 25% of them were children.

The superglue tend will only bond the dry surfaces. When the glue drop or cream is instilled, the patient spontaneously blinks forcibly due to stinging or burning pain in the eye because of its chemical nature and the glue is forcibly pushed on to the lid margin and eye lashes. Since there is dry surface on the lid margins and eyelashes, the glue bonds these surfaces resulting in sticking of eyelashes or eyelid margins (ankyloblepheron) is very common in superglue injuries. The glue causes chemical conjunctivitis and keratitis when it comes in contact with conjunctiva or cornea.

There are two main principles in the management of ocular superglue injuries. (1) to reverse the chemically induced tarsorrhaphy so that detailed eye examination can be performed and visible superglue can be removed. (2) to identify the ocular damage by fluorescein staining and treat the ocular damage as per the standard protocols. Immediate irrigation of the eyes helps in removing some of the glue and reducing the rate of condensation of the glue, and severity of resulting tarsorrhaphy and ocular damage. The ankyloblepheron is treated by trimming of eyelashes and

separation of lid margins without the need of any anaesthesia in adults; the same has to be done under general anaesthesia in children. In young children if the superglue ankyloblepheron is left untreated, there is a danger of development of amblyopia due to obstruction of visual axis by superglue.

The cyanoacrylate glue can be removed by using acetone<sup>[17]</sup> which is a solvent for the glue; but in the eye acetone may cause chemical injury to the conjunctiva and cornea. Removal of the glue on the lid margins can be tried by frequent cleaning with acetone swab. Rubbing of margerine<sup>[18]</sup>, high molecular weight oil, over the lid margins and eyelashes can be tried to remove the glue on the lid margins.

Superglues are cyanoacrylic derivatives. Those used domestically are lower alkyl derivatives than those designed for medical use and they have higher tissue toxicity<sup>[14]</sup>. The risk of ocular accidental application of superglues can be reduced by implementing changes in the package of their bottles which include childproof cap to prevent conventional opening of the bottle, distinctive shape of the bottles, different odour to alert the user, warning in bold print on the bottles, vertical ribs on the bottle<sup>[7,8,11,13,14]</sup>. Suggestions written on the bottle cover to keep them away from easy access to children and to keep them physically apart from bathroom cabinets and dressing table drawers will also lessen the risk of accidental instillation of superglue in the eyes.

Splashing of glue into the eyes was the mechanism of injury when the child (aged 1-10 years) was playing with glue<sup>[8]</sup>. There was inadvertent instillation of nail glue drops into 3

months old baby by mother mistaking as chloramphenicol eye drops, and a 3 years old child imitated her mother's action by putting eye drops in her own eye, but used nail adhesive instead <sup>[12]</sup>. Mandal et al <sup>[13]</sup> report 6 year old girl with accidental application of superglue to the left eye by her mother, inadvertently used as chloramphenicol eye ointment.

All the three cases in the present report are children and there was no serious ocular morbidity in any of them. The mechanism of injury in case 1 was the application of superglue by grand father of the child, mistaking it as antibiotic eye ointment (size and shape of the superglue tube looks similar to eye ointment tube). In case 2, the ocular injury was due to accidental splashing of glue while the child was playing with glue tube. In case 3, the injury was due to inadvertent squirting of glue into the eye when the baby pulled his mother's hand holding the superglue tube.

In conclusion, superglue injuries of the eye occur due to inadvertent application of glue because of mistaking nail glue drops for eye medication drops due to similar appearance of both bottles and because of mistaking glue tube as eye ointment tube due to similar appearance of both. Immediate medical aid will prevent ocular morbidity.

#### REFERENCES

- 1 Margo CE, Trobe JD. Tarsorrhaphy from accidental instillation of cyanoacrylate adhesive in the eye. *JAMA*1982;247(5):660-661
- 2 Morgan SJ, Astbury NJ. Inadvertent self administration of superglue: a consumer hazard. *Br Med J (Clin Res Ed)* 1984;289(6439):226-227
- 3 Raynor LA. Treatment of inadvertent cyanoacrylate tarsorrhaphy: case report. *Arch Ophthalmol* 1988;106(8):1033
- 4 Silverman CM. Corneal abrasion from accidental instillation of cyanoacrylate into the eye. *Arch Ophthalmol* 1988;106(8):1029-1030
- 5 Lyons C, Stevens J, Bloom J. Superglue inadvertently used as eye drops. *BMJ* 1990;300 (6720):328
- 6 DeRespinis PA. Cyanoacrylate nail glue mistaken for eye drops. *JAMA* 1990;263(17): 2301
- 7 Good AM, McCabe SE. Superglue accidents and the eye-causes and prevention. *Br J Ophthalmol* 1994;78(10):802
- 8 Mclean CJ. Ocular superglue injury. *J Accid Emerg Med* 1997;14 (1): 40-41
- 9 Rohrbach JM, Wohlrab TM, Nölle B, Schlote T. Cyanoacrylate injuries of the eye. *Ophthalmologe* 2000;97(12):878-880
- 10 Leibowitz E, Levartovsky S. Confusion caused by similar containers of eye drops and superglue. *Ann Ophthalmol* 2000;32(1):11-12
- 11 Knight IJ. Mistaken eye drops and subsequent instillation of superglue. *Eye(Lond)* 2001;15(Pt 5):663
- 12 Needham A, Natha S, Kaye S. Similarity in the packing of cyanoacrylate nail glue and ophthalmic preparations: an ongoing problem. *Br J Ophthalmol* 2001;85(4):496-497
- 13 Mandal A, Imran D, Erdmann MW. Inadvertent application of superglue as eye ointment. *Ir Med J* 2003;96(10):310-311
- 14 Spencer TJ, Clark B. Self-inflicted superglue injuries. *Med J Aust* 2004;181(6):341
- 15 Desai SP, Teggihalli BC, Bhola R. Superglue mistaken for eye drops. *Arch Dis Child* 2005;90(11):1193
- 16 Yusuf IH, Patel CK. A sticky sight: cyanoacrylate 'superglue' injuries of the eye. *BMJ Case Rep* 2010;2010. pii: bcr11.2009.2435.
- 17 Abadir WF, Nakhla V, Chong P. Removal of superglue from the external ear using acetone: case report and review of literature. *J Laryngol Otol* 1995;109(12):1219-1221
- 18 Narendranath R. How to remove superglue from the mouth: case report. *Br J Oral Maxillofacial Surg* 2005;43(1):81-82